

# Dermatologic conditions in Down syndrome

Chenin Ryan MS<sup>1</sup> | Kishore Vellody MD<sup>2</sup> | Leah Belazarian MD<sup>3</sup> | Jillian F. Rork MD<sup>1,4</sup> 

<sup>1</sup>Dartmouth Geisel School of Medicine, Hanover, New Hampshire, USA

<sup>2</sup>Department of Pediatrics, University of Pittsburgh School of Medicine, Pittsburgh, Pennsylvania, USA

<sup>3</sup>Departments of Pediatrics and Dermatology, University of Massachusetts Medical School, Worcester, Massachusetts, USA

<sup>4</sup>Department of Dermatology, Dartmouth-Hitchcock Medical Center, Manchester, New Hampshire, USA

## Correspondence

Jillian F. Rork, MD, Department of Dermatology, Dartmouth-Hitchcock Medical Center, 100 Hitchcock Way, Manchester, NH, USA.

Email: Jillian.F.Rork@hitchcock.org

## Abstract

Down syndrome (DS) is the most common chromosomal condition and affects many organs including the skin. Dermatologists are an integral part of the DS care team. This is a review of both common and rare dermatologic conditions in DS. We provide practical strategies for a successful dermatology interview and examination. We explore the downstream effects of trisomy of chromosome 21, in particular on the immune system, and how these insights may enhance our pathophysiologic understanding of their cutaneous conditions.

## KEYWORDS

alopecia areata, dermatologic conditions, dermatology, folliculitis, Down syndrome, eczema, hidradenitis suppurativa, melanoma, onychomycosis, psoriasis, scabies, seborrheic dermatitis, skin, skin cancer, trisomy 21, xerosis

## 1 | INTRODUCTION

Down syndrome (DS), or trisomy 21, is the most common chromosomal condition diagnosed in the United States with an estimated worldwide incidence of one in every 1000 births. About 200-300 genes are found on chromosome 21, and the added gene products translate to a variety of potential medical conditions. Although often overlooked in research and health care guidelines, the skin can be significantly affected in people with DS.<sup>1,2</sup> A study on the prevalence of medical conditions in young adults with DS found 56% of those surveyed reported skin findings.<sup>3</sup>

In this review, a general overview of DS and practical examination strategies are provided. We comprehensively review associated dermatologic conditions, with particular emphasis on more common diseases including adnexal, eczematous, and cutaneous autoimmune disorders (Table 1). Throughout the review, trisomy of chromosome 21 and resulting downstream effects are explored, in particular the effect on the immune system. At the conclusion, clinicians should feel confident in their approach to a patient with DS and anticipate potential dermatologic diagnoses.

## 2 | OVERVIEW OF DOWN SYNDROME

An estimated 200,000 individuals with DS reside in the United States today.<sup>4</sup> Certain medical conditions are more common,

including hearing deficits, visual problems, hematologic/oncologic disorders, congenital heart disease, and endocrinopathies.<sup>5</sup> Elevated body mass index (BMI) is also highly prevalent and a recent literature review found up to 70% of people with DS were classified as overweight or obese.<sup>6</sup> This could be relevant to several skin conditions including hidradenitis suppurativa and psoriasis.

Features of both immunodeficiency and immune dysregulation are common in DS. Upper and lower respiratory tract infections result in significant morbidity and mortality.<sup>7</sup> Autoimmune conditions such as Hashimoto thyroiditis, celiac disease, type 1 diabetes, alopecia areata, and juvenile idiopathic arthritis are more frequent.<sup>5</sup> The extent of immune dysregulation is complex. Current research suggests dysfunction of innate and adaptive systems, anomalies in T and B cells, atypical monocytes, impaired neutrophil chemotaxis, abnormal circulating cytokines, and suboptimal antibody responses.<sup>8</sup> The skin offers a unique window into understanding these immune pathways.

While many known complications in DS are found, medical benefits are also well described. These include a reduced incidence of solid organ tumors, atherosclerotic disease, hypertension, thromboembolic stroke, asthma, and allergy.<sup>9-14</sup> These observations will be of particular interest when we discuss hidradenitis suppurativa (HS), psoriasis, eczematous dermatitis, and cutaneous malignancies in patients with DS.

Evidence-based health care guidelines for children and adults are available to guide practitioners in a preventative care model.<sup>1,2</sup> Improved knowledge and care of associated medical conditions have contributed to a greater life span, dramatically increasing from 12 years old in 1940 to 55 years old in 2016.<sup>15,16</sup>

### 3 | THE PATIENT VISIT

Successful evaluation of the skin in any patient requires a level of trust and confidence from the patient toward the clinician. This same concept applies to patients with DS but may often require additional preparation and forethought. For patients who will likely have future visits to the dermatologist, creating an adaptive care plan that addresses specific needs of the individual patient should be considered.<sup>17</sup> Also, several toolkits are available to help prepare the patient and the clinician for a visit.<sup>18</sup>

People with DS often have speech difficulties ranging from being completely non-verbal to full sentence structure with intermittent challenges in articulation. Clinicians should recognize that expressive speech difficulties do not often correlate with receptive language skills.<sup>19</sup> In addition, documentation in the chart detailing any degree of hearing loss is encouraged so that appropriate communication aids can be made available.<sup>20</sup>

While many patients with DS will present to a clinical setting with a support person (eg, a parent, health care aide, or support staff), clinicians should introduce themselves directly to the patient first. As much as developmentally possible, medical concerns should be obtained directly from the patient, and prematurely interrupting a partially expressed thought should be avoided since this can exacerbate speech difficulties such as stuttering.

We often find it helpful to discuss personal hygiene routines since many of their skin conditions required topical treatments. Helpful questions include the following:

- “Do you like the way water feels? How often do you take a shower or bath?”
- “Does anyone help you with your bathing routine? If so, who?”
- “How long does it take for you to take a shower/bath?”
- “Do you like the way lotion feels on your skin? How about something more greasy like Vaseline?”

A complete dermatologic examination will often require changing into a medical gown. Patients with DS may have challenges with transitions or may have sensory difficulties that make this step more difficult.<sup>21</sup> Establishing the sense of a safe environment through respectful and congenial history taking can often ameliorate these challenges. In addition, giving the patient a sense of control over aspects of the examination yet still maintaining the overall direction of the examination is an important skill for clinicians to practice. Helpful phrases could include the following:

**TABLE 1** Dermatologic conditions in Down syndrome by category

Dermatologic condition
Adnexal
Folliculitis
Hidradenitis suppurativa
Acne vulgaris
Xerotic and eczematous
Xerosis
Hyperkeratosis
Keratosis pilaris
Eczematous dermatitis
Seborrheic dermatitis
Cutaneous autoimmune
Alopecia areata
Vitiligo
Infection and infestation
Tinea pedis/onychomycosis
Angular cheilitis
Folliculitis/furunculosis
Scabies
Oral and perioral conditions
Cheilitis
Angular cheilitis
Lingua plicata
Papulosquamous
Psoriasis
Hematologic/oncologic
Transient abnormal myelopoiesis
Benign cutaneous neoplasms
Syringomas
Milia-like idiopathic calcinosis cutis
Eruptive dermatofibromas
Elastosis perforans serpiginosa
Vascular reactions and anomalies
Livedo reticularis
Premature aging

- “Would you like to change into a yellow gown or a blue gown?”
- “Would you prefer that I look at your arms or your legs first?”
- “If you want, can you show me with your hands where your rash is?”

We strongly encourage a complete skin examination. As will be discussed below, many associated skin conditions can occur in hidden areas such as the scalp, armpits, groin, and feet. A focused examination addressing only a chief complaint could overlook skin conditions in need of expertise.

## 4 | DERMATOLOGIC CONDITIONS

### 4.1 | Adnexal conditions

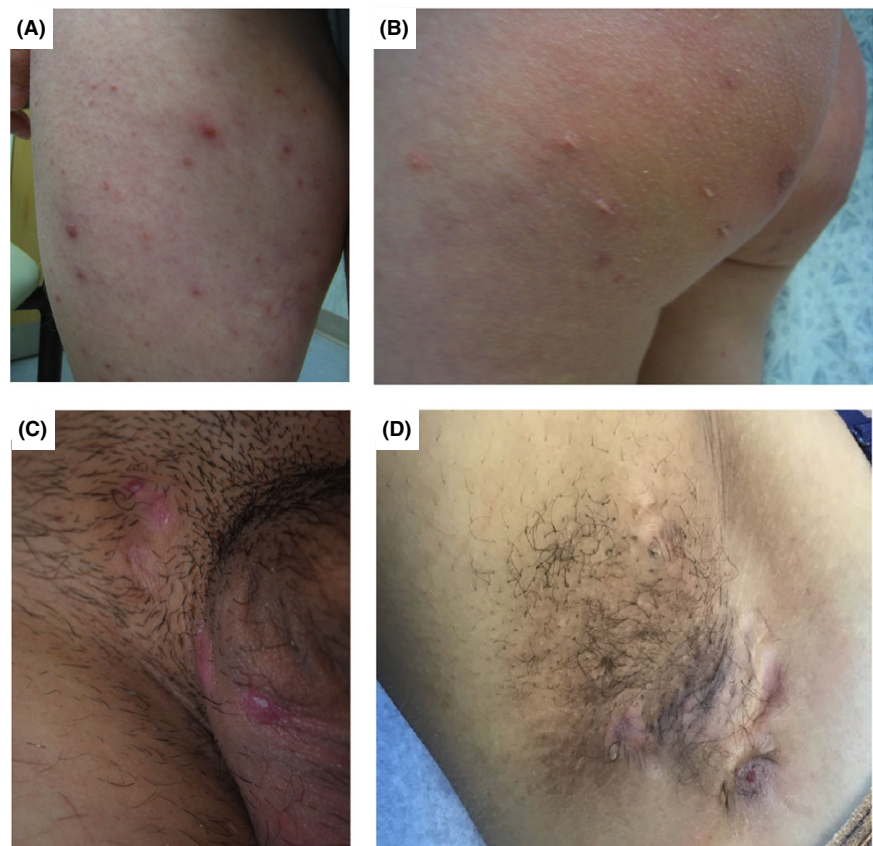
Follicular occlusion disorders, including folliculitis and hidradenitis suppurativa, are among the most common cutaneous conditions in patients with DS.<sup>22-28</sup> Folliculitis was first described as *Pityrosporum* folliculitis on the chest and back.<sup>29,30</sup> Recent publications have described a refractory inflammatory folliculitis concentrated on the thighs and buttocks that can result in anetoderma-like scar formation (Figure 1A,1B).<sup>22,24,27,28,31</sup> Several studies have found this form of folliculitis to be the most common skin diagnosis, and many patients have a concomitant diagnosis of HS, suggesting these conditions may be along the same continuum.<sup>22,24,27,28</sup>

Hidradenitis suppurativa appears to be more prevalent in DS (Figure 1C,1D).<sup>32</sup> A population-based cross-sectional analysis of nearly 12 000 DS patients found a 2.1% prevalence of HS vs. 0.3% in controls.<sup>26</sup> Given these findings, the US and Canadian Hidradenitis Suppurativa Foundations have recently recommended annual HS screening in patients with DS.<sup>33</sup> HS also appears to present at a younger age, typically during adolescence, with several reports of preadolescent occurrence.<sup>25,33-35</sup> The most common reported Hurley stages are I-II, but further research is needed on clinical severity and response to treatments.<sup>24,35-37</sup>

Trisomy of chromosome 21 and subsequent effects on the immune system and pilosebaceous apocrine unit could predispose to folliculitis and HS. Individuals with DS may have an increased amount of amyloid precursor protein (APP) since the encoding gene is located on chromosome 21.<sup>38</sup> APP is expressed in the epidermis and stimulates keratinocyte adhesion, migration, and proliferation; therefore, increased amounts of APP may predispose to follicular occlusion.<sup>23,39</sup> Gamma-secretase, a transmembrane enzyme mutated in familial cases of HS, may also be involved. In DS, gamma-secretase may be sequestered to process the excess APP leading to defective Notch signaling.<sup>40</sup> Chronic immune dysregulation in DS may also promote microbial growth, leading to cutaneous dysbiosis.<sup>8</sup>

Obesity is a commonly shared comorbidity in patients with HS and DS. In a recent study, the majority of DS patients with HS were obese (68.2%).<sup>28</sup> HS is known to be associated with metabolic syndrome and an increased risk of adverse cardiovascular outcomes.<sup>41,42</sup> While a reported decrease in hypertension and atherosclerotic events is found to be observed in patients with DS, we do not know whether this applies to those with HS. Given the increasing average life expectancy, these potential associations will be essential to explore.

Limited studies are found on acne in DS.<sup>27,43</sup> A cross-sectional study of 89 patients aged 10-28 years reported a prevalence of 70.8%. In our experience, acne is not an uncommon diagnosis encountered in our dermatology practices, but additional research is needed.



**FIGURE 1** Adnexal disorders in Down syndrome. (A) Anterior thigh folliculitis in a 12 year-old girl. (B) Anetoderma-like scarring on the buttocks where folliculitis resolved in the same patient. (C) Groin hidradenitis suppurativa in a 15 year-old man. (D) Axillary hidradenitis suppurativa in a 17 year-old woman

## 4.2 | Xerotic and eczematous conditions

Xerosis is a common skin condition of all ages and is often considered part of the DS phenotype (Figure 2A).<sup>22</sup> Several conditions related to xerosis are commonly seen, including keratosis pilaris and hyperkeratosis of the extensor and palmoplantar surfaces (Figure 2B).<sup>22,27,28</sup> Eczematous dermatitis can also occur. While earlier studies reported atopic dermatitis was a major cutaneous finding of DS, this has since been challenged when Hanifin and Rajka atopic dermatitis criteria were applied.<sup>44</sup> In our experience, eczematous dermatitis is often on the face, back, and hands in the setting of severe xerosis or possible irritant/allergic contact dermatitis.

Seborrheic dermatitis is also a common finding.<sup>28,45-47</sup> This can be limited to the scalp, but also extend to the face and intertriginous areas (Figure 2C,D), thus potentially on the spectrum of seborrheic dermatitis. Seborrheic dermatitis in DS tends to present at a younger age and follows a more severe, chronic course. The pathophysiology of seborrheic dermatitis is poorly understood, but is known to be more frequent in individuals with immunologic defects. These defects may affect the relationship between the skin barrier and cutaneous microorganisms such as *Malassezia* and could explain why it is more common in DS.

## 4.3 | Autoimmune skin conditions

Alopecia areata (AA) occurs more often in DS (Figure 3A). Studies evaluating prevalence are limited, but figures vary from 1.3% to 11% compared with 0.1% to 0.2% in the general population.<sup>48,49</sup> AA tends to appear earlier in life, often between ages 5 and 10 years.<sup>22,28</sup> Patch type, totalis, and universalis have all been observed, and additional research is needed to determine whether a more severe, refractory phenotype is common. Vitiligo may also be more common, and both conditions have been observed concomitantly.<sup>22,46,50</sup>

As previously discussed, it is well established that autoimmune diseases occur more often in DS. Of interest, the autoimmune regulator (*AIRE*) gene, which regulates self-recognition and T-cell function, is located on chromosome 21. Reduced *AIRE* expression has been observed in DS, which could lead to a greater propensity for autoimmune conditions, as is seen in autoimmune polyendocrinopathy-candidiasis-ectodermal dystrophy (APECED), an autosomal recessive condition caused by mutations in the *AIRE* gene.<sup>51-53</sup>

Hyperactive interferon (IFN) is also of particular interest. Chromosome 21 encodes four of the six IFN receptor subunits, including type 1 IFN, IFN- $\alpha$ , and IFN- $\gamma$ , and these receptors are overexpressed in multiple DS cell types.<sup>54,55</sup> This could explain the observed "super-induction" of downstream JAK/STAT signaling and IFN-stimulated genes in cells of individuals with DS.<sup>56</sup> IFN- $\gamma$  has been implicated as central to the mechanism of both AA and vitiligo.<sup>57,58</sup> JAK-1 inhibition is a potential therapeutic target, and clinical trials are currently underway in patients with DS with skin conditions including AA, vitiligo, atopic dermatitis, and HS.<sup>59</sup>

When the diagnosis of AA is made, providers should confirm thyroid screening is up to date. According to recent guidelines,

thyroid function studies should be performed at ages 6 months and 12 months, annually beginning at age 1 year, and every 1-2 years beginning at age 21 years.<sup>1,2</sup>

## 4.4 | Infections and infestations

As previously mentioned, individuals with DS are known to have an increased susceptibility to certain infections, particularly of the respiratory tract. The two most common cutaneous infections and infestations reported are crusted scabies and dermatophytes, specifically tinea pedis and onychomycosis (Figure 3B). These observations may be an overestimate since many early studies were of patients living in institutions.<sup>45,60</sup> There has also been discussion of increased cutaneous candida infections and bacterial infections, but additional studies are needed.<sup>61,62</sup>

Despite the current literature's shortcomings, dermatophyte infections appear to be more common at a younger age in DS.<sup>28,63</sup> Also, several informative case reports describing crusted scabies initially misdiagnosed as psoriasis and inappropriately treated with immunosuppression are found.<sup>64-67</sup> Crusted scabies may be more common in DS given underlying immunodeficiency and immune dysregulation; it is well documented that immunocompromised patients are at increased risk of developing crusted scabies. Given this knowledge, crusted scabies should be on the differential diagnosis when a patient with DS presents with generalized erythrodermic dermatitis, keratoderma, or onychodystrophy.

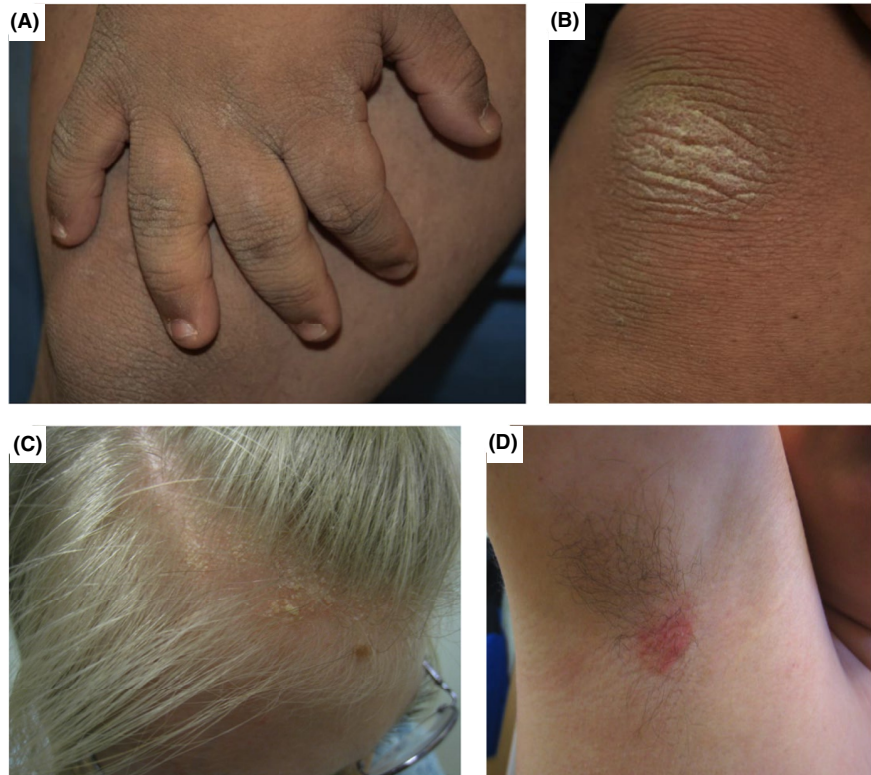
## 4.5 | Oral and perioral conditions

Oral manifestations are frequent among patients with DS. Macroglossia and decreased oral motor tone are common. This can lead to pooling of saliva within the oral commissures and increase saliva around the mouth (Figure 3C). The irritating properties of saliva can cause lip fissures and angular cheilitis. In addition, the oral cavity may have higher opportunistic infections, especially *Candida* species, which could contribute to angular cheilitis.<sup>61</sup> Lingua plicata can also be present and should be considered a benign finding (Figure 3D).

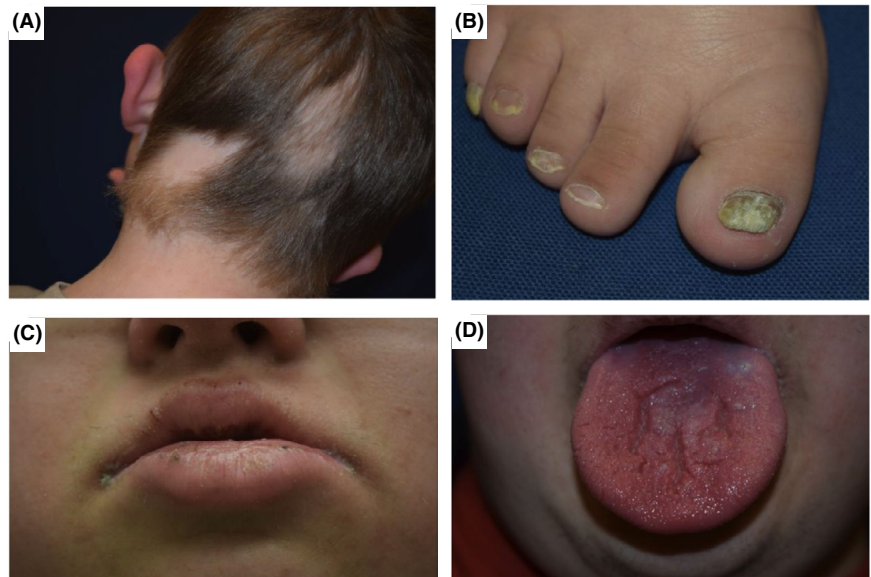
## 4.6 | Papulosquamous conditions

Psoriasis may be associated with DS, although existing literature is limited. The reported incidence ranges between 0.5% and 8%.<sup>68</sup> There have been case reports of various presentations including mild-to-severe disease, annular pustular psoriasis, and concomitant psoriatic arthritis.<sup>69-71</sup> The association between obesity and psoriasis in DS needs to be further explored, as does cardiovascular disease risk.<sup>28</sup> While DS appears to be protective against atherosclerotic disease and hypertension, myocardial infarction in the setting of psoriasis has been reported.<sup>72</sup> We recommend following current psoriasis comorbidity screening recommendations for adult and pediatric patients with DS until this has been further studied.<sup>73,74</sup>

**FIGURE 2** Xerotic and eczematous disorders in Down syndrome. (A) Hand xerosis in a 26 year-old man. (B) Hyperkeratosis of the extensor knee in a 21 year-old man. (C) Seborrheic dermatitis on the frontal scalp in a 13 year-old girl. (D) Axillary seborrheic intertrigo in the same patient



**FIGURE 3** Autoimmune, infections, and oral conditions in Down syndrome. (A) Alopecia areata in a 6 year-old boy. (B) Onychomycosis in a 7 year-old girl. (C) Cheilitis and pooling of saliva within the oral commissures of a 21 year-old man. (D) Lingua plicata in the same patient



## 4.7 | Hematologic/oncologic conditions

### 4.7.1 | Transient abnormal myelopoiesis

Leukemia develops in 2%-3% of all patients with DS, in particular acute myeloid leukemia.<sup>5</sup> Transient abnormal myelopoiesis (TAM), formerly called transient myeloproliferative disorder, is a form of myeloid pre-leukemia occurring in up to 10% of neonates with DS.<sup>75</sup> Somatic mutations in the *GATA1* gene are responsible for this

leukemogenic condition.<sup>76</sup> TAM more frequently affects males, which may be due to the presence of the *GATA* gene on the X chromosome.

Skin findings of TAM occur in only 5% of those diagnosed. Cutaneous morphology includes vesicles, vesiculopustules, and crusted papules, which appear on the face, trunk, and extremities, and in areas of trauma, such as venipuncture sites.<sup>77</sup> These lesions, which typically occur between days 1 and 21 (median 3 days), do not seem to correlate with the number of circulating white blood

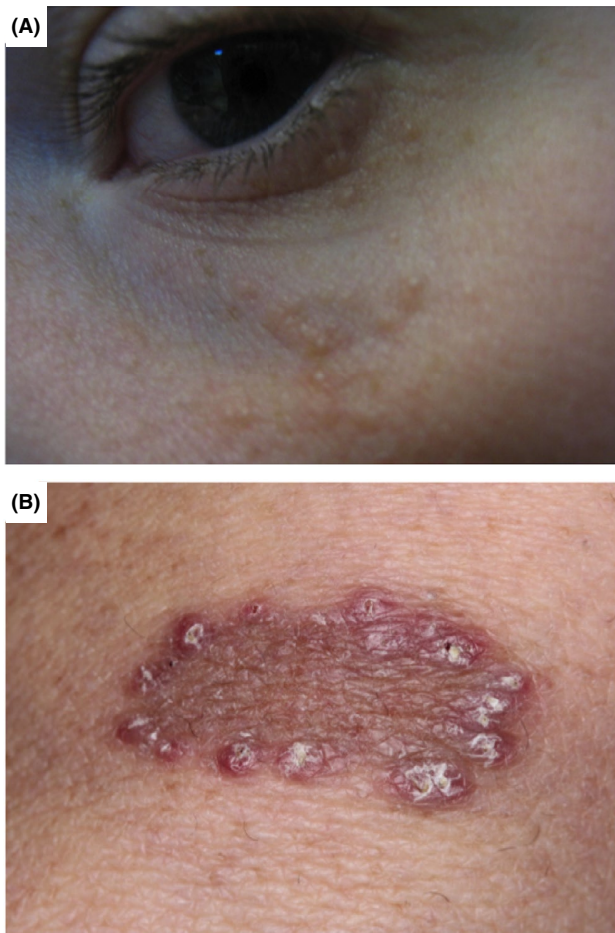
cells or blasts.<sup>76</sup> The cutaneous findings may be the only initial clue identifying DS in a neonate with mild clinical features or trisomy 21 mosaicism. It is thus important to place TAM on the differential of a neonatal vesiculopustular eruption.

TAM can be evaluated by performing a microscopic examination of contents from the base of a pustule, which shows immature myelocytes and promyelocytes.<sup>77</sup> Although TAM usually resolves spontaneously, early detection and monitoring by a pediatric hematologist is recommended since 20%-30% will develop leukemia, specifically acute megakaryoblastic leukemia (AMKL).<sup>5</sup>

## 4.8 | Benign cutaneous neoplasms

### 4.8.1 | Syringomas

Syringomas have an incidence approximately 30 times higher in DS than in the general population, ranging between 18.5% and 39.2% (Figure 4A).<sup>78,79</sup> They are more common in women than in men, and prevalence increases with age.<sup>77</sup> The typical morphology is similar to



**FIGURE 4** Cutaneous tumors in Down syndrome. (A) Syringomas in a 14 year-old woman. (B) Elastosis perforans serpiginosa in a 25 year-old man

the general population; they present as small 1-3 mm flesh-colored-to-yellowish disklike papules most commonly in the periorbital region. Eruptive syringomas have also been reported with extension onto the trunk and extremities.<sup>80-82</sup> They also may coexist with milia-like calcinosis cutis (discussed below) or present as milium-like syringomas.<sup>83-86</sup> Syringomas typically persist, and treatment is challenging.

### 4.8.2 | Milia-like idiopathic calcinosis cutis

Milia-like idiopathic calcinosis cutis (MICC) is a rare condition that can occur in children with DS.<sup>86-88</sup> It typically presents as asymptomatic small, firm, and white papules, sometimes with an erythematous halo. They are most often located on acral sites. Serum calcium and phosphorus levels are normal, therefore classifying MICC as a form of idiopathic calcinosis cutis. Pathogenesis is unclear. Since lesions tend to self-resolve by adulthood, treatment is unnecessary.

### 4.8.3 | Eruptive dermatofibromas

Multiple eruptive dermatofibromas (MDF) are defined by 4-8 dermatofibromas occurring over a 4 months period.<sup>89</sup> The majority of MDF cases have been associated with autoimmune conditions or immunodeficiency, which may explain the association with DS.<sup>90</sup> Several cases of MDF have been reported in the literature with the lesions developing within a short period ranging from 3 months to 3 years.<sup>89,91,92</sup>

### 4.8.4 | Elastosis perforans serpiginosa

Elastosis perforans serpiginosa (EPS) is believed to be more common in DS, although the exact prevalence is unknown (Figure 4B). It is unclear why this association occurs, but it could be related to connective tissue dysplasia.<sup>93</sup> EPS typically occurs in older children and young adults.<sup>77</sup> Locations include face, neck, abdomen, and extremities. A variety of morphologies have been described, including annular, arcuate, and serpiginous hyperkeratotic papules. It can also present as a more extensive, generalized form.<sup>93-95</sup> There have been cases of spontaneous remission, but many are chronic.<sup>22,96</sup> If the lesions do resolve, they can leave behind atrophic scars.

## 4.9 | Vascular reactions and anomalies

Livedo reticularis is a common finding, although it is not often discussed in the literature. This tends to persist through adulthood and is considered a benign finding. Individuals with DS may have a reduced risk of vascular anomalies, including infantile hemangiomas.<sup>97</sup> Elevated expression of anti-angiogenic proteins, including VEGF inhibitors, may protect against developing vascular anomalies and may also play a role in preventing solid tumors.<sup>98</sup>

#### 4.10 | Premature aging

Despite dramatic increases in life span, “accelerated aging” is still considered part of the DS phenotype. Cutaneous signs include graying of hair, hair loss, and skin wrinkling. Several mechanistic proposals, including decreased DNA repair enzymes and altered free-radical metabolism, are found.<sup>78</sup>

#### 4.11 | Atypical and malignant cutaneous neoplasms

Cutaneous malignancies, including melanoma, non-melanoma skin cancer, and atypical Spitz tumors, have been infrequently reported in DS.<sup>28,99–102</sup> Several reported melanoma cases are in pediatric and adolescent patients with no recorded fatalities. As life expectancy in DS increases, dermatologists should be aware of the potential for cutaneous malignancies even though solid tumors are overall less common.<sup>103</sup>

## 5 | CONCLUSION

The skin is often affected in individuals with DS, and dermatologists should be aware of both common and rare associated diagnoses. We recommend a thorough cutaneous examination, with particular attention to the scalp, axilla, groin, and feet, as these are locations of more common skin conditions, including alopecia areata, seborrheic dermatitis, folliculitis, hidradenitis suppurativa, and dermatophyte infections. Trisomy of chromosome 21 and the resulting immune system dysregulation could further our understanding of disease pathophysiology.

#### DATA AVAILABILITY STATEMENT

Research data not shared.

#### ORCID

Jillian F. Rork  <https://orcid.org/0000-0001-5588-8594>

#### REFERENCES

1. Bull MJ, Genetics CO. Health supervision for children with Down syndrome. *Pediatrics*. 2011;128(2):393-406.
2. Tsou AY, Bulova P, Capone G, et al. Medical care of adults with down syndrome: a clinical guideline. *JAMA*. 2020;324(15):1543-1556.
3. Pikora TJ, Bourke J, Bathgate K, Foley KR, Lennox N, Leonard H. Health conditions and their impact among adolescents and young adults with Down syndrome. *PLoS One*. 2014;9(5):e96868.
4. de Graaf G, Buckley F, Dever J, Skotko BG. Estimation of live birth and population prevalence of Down syndrome in nine U.S. states. *Am J Med Genet A*. 2017;173(10):2710-2719.
5. Bull MJ. Down Syndrome. *N Engl J Med*. 2020;382(24):2344-2352.
6. Bertapelli F, Pitetti K, Agiovlasis S, Guerra-Junior G. Overweight and obesity in children and adolescents with Down syndrome-prevalence, determinants, consequences, and interventions: a literature review. *Res Dev Disabil*. 2016;57:181-192.
7. Verstegen RHJ, Kusters MAA. Inborn errors of adaptive immunity in Down syndrome. *J Clin Immunol*. 2020;40(6):791-806.

8. Huggard D, Doherty DG, Molloy EJ. Immune dysregulation in children with Down syndrome. *Front Pediatr*. 2020;8:73.
9. Malinge S, Izraeli S, Crispino JD. Insights into the manifestations, outcomes, and mechanisms of leukemogenesis in Down syndrome. *Blood*. 2009;113(12):2619-2628.
10. Nizetic D, Groet J. Tumorigenesis in Down's syndrome: big lessons from a small chromosome. *Nat Rev Cancer*. 2012;12(10):721-732.
11. Englund A, Jonsson B, Zander CS, Gustafsson J, Anneren G. Changes in mortality and causes of death in the Swedish Down syndrome population. *Am J Med Genet A*. 2013;161A(4):642-649.
12. Rodrigues A, Coelho LC, Goncalves WL, et al. Stiffness of the large arteries in individuals with and without Down syndrome. *Vasc Health Risk Manag*. 2011;7:375-381.
13. Marto JP, Dias M, Alves JN, et al. Stroke in adults with Down syndrome. *J Neurol Sci*. 2017;375:279-280.
14. Weijerman ME, Brand PL, van Furth MA, Broers CJ, Gemke RJ. Recurrent wheeze in children with Down syndrome: is it asthma? *Acta Paediatr*. 2011;100(11):e194-e197.
15. Coppus A, Evenhuis H, Verberne GJ, et al. Dementia and mortality in persons with Down's syndrome. *J Intellect Disabil Res*. 2006;50(Pt 10):768-777.
16. Landes SD, Stevens JD, Turk MA. Heterogeneity in age at death for adults with developmental disability. *J Intellect Disabil Res*. 2019;63(12):1482-1487.
17. Liddle M, Birkett K, Bonjour A, Risma K. A collaborative approach to improving health care for children with developmental disabilities. *Pediatrics*. 2018;142(6):e20181136.
18. Kripke C. Adults with developmental disabilities: a comprehensive approach to medical care. *Am Fam Physician*. 2018;97(10):649-656.
19. Grieco J, Pulsifer M, Seligsohn K, Skotko B, Schwartz A. Down syndrome: cognitive and behavioral functioning across the lifespan. *Am J Med Genet C Semin Med Genet*. 2015;169(2):135-149.
20. Shott SR. Down syndrome: common otolaryngologic manifestations. *Am J Med Genet C Semin Med Genet*. 2006;142C(3):131-140.
21. Will EA, Daunhauer LA, Fidler DJ, Raitano Lee N, Rosenberg CR, Hepburn SL. Sensory processing and maladaptive behavior: profiles within the Down syndrome phenotype. *Phys Occup Ther Pediatr*. 2019;39(5):461-476.
22. Schepis C, Barone C, Siragusa M, Pettinato R, Romano C. An updated survey on skin conditions in Down syndrome. *Dermatology*. 2002;205(3):234-238.
23. Blok J, Jonkman M, Horvath B. The possible association of hidradenitis suppurativa and Down syndrome: is increased amyloid precursor protein expression resulting in impaired notch signalling the missing link? *Br J Dermatol*. 2014;170(6):1375-1377.
24. Sechi A, Guglielmo A, Patrizi A, et al. Disseminate recurrent folliculitis and hidradenitis suppurativa are associated conditions: results from a retrospective study of 131 patients with Down Syndrome and a cohort of 12,351 pediatric controls. *Dermatol Pract Concept*. 2019;9(3):187-194.
25. Denny G, Anadkat MJ. Hidradenitis suppurativa (HS) and Down syndrome (DS): Increased prevalence and a younger age of hidradenitis symptom onset. *J Am Acad Dermatol*. 2016;75(3):632-634.
26. Garg A, Strunk A, Midura M, Papagermanos V, Pomerantz H. Prevalence of hidradenitis suppurativa among patients with Down syndrome: a population-based cross-sectional analysis. *Br J Dermatol*. 2018;178(3):697-703.
27. Firsowicz M, Boyd M, Jacks SK. Follicular occlusion disorders in Down syndrome patients. *Pediatr Dermatol*. 2020;37(1):219-221.
28. Rork JF, McCormack L, Lal K, Wiss K, Belazarian L. Dermatologic conditions in Down syndrome: a single-center retrospective chart review. *Pediatr Dermatol*. 2020;37(5):811-816.
29. Finn OA, Grant PW, McCallum DI, Raffle EJ. A singular dermatosis of mongols. *Arch Dermatol*. 1978;114(10):1493-1494.

30. Kavanagh GM, Leeming JP, Marshman GM, Reynolds NJ, Burton JL. Folliculitis in Down's syndrome. *Br J Dermatol*. 1993;129(6):696-699.
31. Schepis C, Siragusa M. Secondary anetoderma in people with Down's syndrome. *Acta Derm Venereol*. 1999;79(3):245.
32. Lam M, Lai C, Almuhanha N, Alhusayen R. Hidradenitis suppurativa and Down syndrome: a systematic review and meta-analysis. *Pediatr Dermatol*. 2020;37(6):1044-1050.
33. Garg A, Malviya N, Strunk A, et al. Comorbidity screening in Hidradenitis Suppurativa: evidence-based recommendations from the US and Canadian hidradenitis suppurativa foundations. *J Am Acad Dermatol*. 2021;S0190-9622(21):00213-00219.
34. Veraldi S, Guanziroli E, Benzecry V, Nazzaro G. Hidradenitis suppurativa in patients with Down syndrome. *J Eur Acad Dermatol Venereol*. 2019;33(Suppl. 6):34-35.
35. Giovanardi G, Chiricozzi A, Bianchi L, et al. Hidradenitis suppurativa associated with Down syndrome is characterized by early age at diagnosis. *Dermatology*. 2018;234(1-2):66-70.
36. Hamadah I, Haider M, Chisti M, Binamer Y. Hidradenitis suppurativa in Down syndrome: a case series. *Pediatr Dermatol*. 2017;34(4):461-464.
37. Poizeau F, Sbidian E, Mircher C, et al. Prevalence and description of hidradenitis suppurativa in Down syndrome: a cross-sectional study of 783 subjects. *Acta Derm Venereol*. 2019;99(3):351-352.
38. Jenkins EC, Devine-Gage EA, Robakis NK, et al. Fine mapping of an Alzheimer disease-associated gene encoding beta-amyloid protein. *Biochem Biophys Res Commun*. 1988;151(1):1-8.
39. Herzog V, Kirfel G, Siemes C, Schmitz A. Biological roles of APP in the epidermis. *Eur J Cell Biol*. 2004;83(11-12):613-624.
40. Berezovska O, Jack C, Deng A, Gastineau N, Rebeck GW, Hyman BT. Notch1 and amyloid precursor protein are competitive substrates for presenilin1-dependent gamma-secretase cleavage. *J Biol Chem*. 2001;276(32):30018-30023.
41. Gold DA, Reeder VJ, Mahan MG, Hamzavi IH. The prevalence of metabolic syndrome in patients with hidradenitis suppurativa. *J Am Acad Dermatol*. 2014;70(4):699-703.
42. Egeberg A, Gislason GH, Hansen PR. Risk of major adverse cardiovascular events and all-cause mortality in patients with hidradenitis suppurativa. *JAMA Dermatol*. 2016;152(4):429-434.
43. Bagatin E, Kamamoto CSL, dos Santos Guadanhim LR, et al. Prevalence of acne vulgaris in patients with Down syndrome. *Dermatology*. 2010;220(4):333-339.
44. Schepis C, Barone C, Siragusa M, Romano C. Prevalence of atopic dermatitis in patients with Down syndrome: a clinical survey. *J Am Acad Dermatol*. 1997;36(6 Pt 1):1019-1021.
45. Carter DM, Jegasothy BV. Alopecia areata and Down syndrome. *Arch Dermatol*. 1976;112(10):1397-1399.
46. Ercis M, Balci S, Atakan N. Dermatological manifestations of 71 Down syndrome children admitted to a clinical genetics unit. *Clin Genet*. 1996;50(5):317-320.
47. Bilgili SG, Akdeniz N, Karadag AS, Akbayram S, Calka O, Ozkol HU. Mucocutaneous disorders in children with down syndrome: case-controlled study. *Genet Couns*. 2011;22(4):385-392.
48. Lima Estefan J, Queiroz M, Costa FF, et al. Clinical characteristics of alopecia areata in Down syndrome. *Acta Dermatovenereol Croat*. 2013;21(4):253-258.
49. Strazzulla LC, Wang EHC, Avila L, et al. Alopecia areata: disease characteristics, clinical evaluation, and new perspectives on pathogenesis. *J Am Acad Dermatol*. 2018;78(1):1-12.
50. Daneshpazhooh M, Nazemi TM, Bigdeloo L, Yoosefi M. Mucocutaneous findings in 100 children with Down syndrome. *Pediatr Dermatol*. 2007;24(3):317-320.
51. Gimenez-Barcons M, Casteras A, Armengol Mdel P, et al. Autoimmune predisposition in Down syndrome may result from a partial central tolerance failure due to insufficient intrathymic expression of AIRE and peripheral antigens. *J Immunol*. 2014;193(8):3872-3879.
52. Lima FA, Moreira-Filho CA, Ramos PL, et al. Decreased AIRE expression and global thymic hypofunction in Down syndrome. *J Immunol*. 2011;187(6):3422-3430.
53. Collins SM, Dominguez M, Ilmarinen T, Costigan C, Irvine AD. Dermatological manifestations of autoimmune polyendocrinopathy-candidiasis-ectodermal dystrophy syndrome. *Br J Dermatol*. 2006;154(6):1088-1093.
54. de Weerd NA, Nguyen T. The interferons and their receptors—distribution and regulation. *Immunol Cell Biol*. 2012;90(5):483-491.
55. Sullivan KD, Lewis HC, Hill AA, et al. Trisomy 21 consistently activates the interferon response. *Elife*. 2016;5:e16220.
56. Waugh KA, Araya P, Pandey A, et al. Mass cytometry reveals global immune remodeling with multi-lineage hypersensitivity to type I interferon in Down syndrome. *Cell Rep*. 2019;29(7):1893-1908.
57. Rajabi F, Drake LA, Senna MM, Rezaei N. Alopecia areata: a review of disease pathogenesis. *Br J Dermatol*. 2018;179(5):1033-1048.
58. Frisoli ML, Essien K, Harris JE. Vitiligo: mechanisms of pathogenesis and treatment. *Annu Rev Immunol*. 2020;38:621-648.
59. Rachubinski AL, Estrada BE, Norris D, Dunnick CA, Boldrick JC, Espinosa JM. Janus kinase inhibition in Down syndrome: 2 cases of therapeutic benefit for alopecia areata. *JAAD Case Rep*. 2019;5(4):365-367.
60. Hubler WR Jr. Epidemic Norwegian scabies. *Arch Dermatol*. 1976;112(2):179-181.
61. Mohiddin G, Narayanaswamy AB, Masthan KM, Nagarajan A, Panda A, Behura SS. Oral Candidal and streptococcal carriage in Down syndrome patients. *J Nat Sci Biol Med*. 2015;6(2):300-305.
62. Ram G, Chinen J. Infections and immunodeficiency in Down syndrome. *Clin Exp Immunol*. 2011;164(1):9-16.
63. Solis-Arias MP, Garcia-Romero MT. Onychomycosis in children. A review. *Int J Dermatol*. 2017;56(2):123-130.
64. Fonseca V, Price HN, Jeffries M, Alder SL, Hansen RC. Crusted scabies misdiagnosed as erythrodermic psoriasis in a 3-year-old girl with down syndrome. *Pediatr Dermatol*. 2014;31(6):753-754.
65. Senterre Y, Jouret G, Collins P, Nikkels AF. Risankizumab-aggravated crusted scabies in a patient with Down syndrome. *Dermatol Ther (Heidelb)*. 2020;10(4):829-834.
66. Lehmborg J, Roper B, Omoruyi E, Evangelista M. Skin Plaques Mimicking Psoriasis. *J Pediatr*. 2015;167(4):937-937 e931.
67. Nagsuk P, Moore R, Lopez L. A case report of crusted scabies in an adult patient with Down syndrome. *Dermatol Online J*. 2015;21(8):13030.
68. Barankin B, Guenther L. Dermatological manifestations of Down's syndrome. *J Cutan Med Surg*. 2001;5(4):289-293.
69. Hedayati B, Carley SK, Kraus CN, Smith J. Arcuate pink plaques in a female with Down syndrome. *Int J Dermatol*. 2020;59(4):e127-e128.
70. Marmon S, De Souza A, Strober BE. Psoriasis and Down syndrome: a report of three cases and a potential pathophysiologic link. *Dermatol Online J*. 2012;18(6):13.
71. Sugiura K, Kitoh T, Watanabe D, Muto M, Akiyama M. Childhood-onset PsA in Down syndrome with psoriasis susceptibility variant CARD14 rs11652075. *Rheumatology (Oxford)*. 2015;54(1):197-199.
72. Sismour B, D'Acunto K. Down syndrome, severe psoriasis, and increased risk for cardiovascular events. *JAAPA*. 2019;32(12):31-33.
73. Kimball AB, Gladman D, Gelfand JM, et al. National psoriasis foundation clinical consensus on psoriasis comorbidities and recommendations for screening. *J Am Acad Dermatol*. 2008;58(6):1031-1042.
74. Osier E, Wang AS, Tollefson MM, et al. Pediatric psoriasis comorbidity screening guidelines. *JAMA Dermatol*. 2017;153(7):698-704.
75. Gamis AS, Alonzo TA, Gerbing RB, et al. Natural history of transient myeloproliferative disorder clinically diagnosed in Down



- syndrome neonates: a report from the children's oncology group study a2971. *Blood*. 2011;118(26):6752-6759. quiz 6996.
76. Brazzelli V, Segal A, Bernacca C, et al. Neonatal vesiculopustular eruption in Down syndrome and transient myeloproliferative disorder: a case report and review of the literature. *Pediatr Dermatol*. 2019;36(5):702-706.
  77. Folster-Holst R, Rohrer T, Jung AM. Dermatological aspects of the S2k guidelines on Down syndrome in childhood and adolescence. *J Dtsch Dermatol Ges*. 2018;16(10):1289-1295.
  78. Madan V, Williams J, Lear JT. Dermatological manifestations of Down's syndrome. *Clin Exp Dermatol*. 2006;31(5):623-629.
  79. Williams K, Shinkai K. Evaluation and management of the patient with multiple syringomas: a systematic review of the literature. *J Am Acad Dermatol*. 2016;74(6):1234-1240.
  80. Ong GC, Lim KS, Chian LY. Eruptive syringoma in a patient with trisomy 21. *Singapore Med J*. 2010;51(2):e46-e47.
  81. Schepis C, Torre V, Siragusa M, et al. Eruptive syringomas with calcium deposits in a young woman with Down's syndrome. *Dermatology*. 2001;203(4):345-347.
  82. Martyn-Simmons CL, Ostlere LS. Papular eruption on a patient with Down syndrome. *Arch Dermatol*. 2004;140(9):1161-1166.
  83. Turan E, Yurt N, Yesilova Y, Tanrikulu O. A rare association in Down syndrome: milialike idiopathic calcinosis cutis and palpebral syringoma. *Cutis*. 2016;98(6):E22-E23.
  84. Motegi SI, Sekiguchi A, Fujiwara C, Yamazaki S, Ishikawa O. Milialike idiopathic calcinosis cutis and plaque-type syringoma in a girl with Down syndrome. *J Dermatol*. 2019;46(4):e136-e137.
  85. Seo SH, Oh CK, Kwon KS, Kim MB. A case of milium-like syringoma with focal calcification in Down syndrome. *Br J Dermatol*. 2007;157(3):612-614.
  86. Schepis C, Siragusa M, Palazzo R, Batolo D, Romano C. Milialike idiopathic calcinosis cutis: an unusual dermatosis associated with Down syndrome. *Br J Dermatol*. 1996;134(1):143-146.
  87. Fox GN, Mehregan DA, Jablonski MN. Acral milialike idiopathic calcinosis cutis in a child with down syndrome: report of a case, review of the literature, and description of dermoscopic findings. *Pediatr Dermatol*. 2013;30(2):263-264.
  88. Becuwe C, Roth B, Villedieu MH, Chouvet B, Kanitakis J, Claudy A. Milialike idiopathic calcinosis cutis. *Pediatr Dermatol*. 2004;21(4):483-485.
  89. Lamb RC, Gangopadhyay M, MacDonald A. Multiple dermatofibromas in Down syndrome. *Int J Dermatol*. 2014;53(4):e274-e275.
  90. Zaccaria E, Rebora A, Rongioletti F. Multiple eruptive dermatofibromas and immunosuppression: report of two cases and review of the literature. *Int J Dermatol*. 2008;47(7):723-727.
  91. Tanaka M, Hoashi T, Serizawa N, et al. Multiple unilaterally localized dermatofibromas in a patient with Down syndrome. *J Dermatol*. 2017;44(9):1074-1076.
  92. Honda M, Tomimura S, de Vega S, Utani A. Multiple dermatofibromas in a patient with Down syndrome. *J Dermatol*. 2016;43(3):346-348.
  93. O'Donnell B, Kelly P, Dervan P, Powell FC. Generalized elastosis perforans serpiginosa in Down's syndrome. *Clin Exp Dermatol*. 1992;17(1):31-33.
  94. Rasmussen JE. Disseminated elastosis perforans serpiginosa in four mongoloids. Recognition of residual changes. *Br J Dermatol*. 1972;86(1):9-13.
  95. Treadwell PA. Hyperkeratotic papules in a patient with Down syndrome. *Pediatr Dermatol*. 1990;7(3):237-238.
  96. Siragusa M, Romano C, Cavallari V, Schepis C. Localized elastosis perforans serpiginosa in a boy with Down syndrome. *Pediatr Dermatol*. 1997;14(3):244-246.
  97. Greene AK, Kim S, Rogers GF, Fishman SJ, Olsen BR, Mulliken JB. Risk of vascular anomalies with Down syndrome. *Pediatrics*. 2008;121(1):e135-e140.
  98. Zorick TS, Mustacchi Z, Bando SY, et al. High serum endostatin levels in Down syndrome: implications for improved treatment and prevention of solid tumours. *Eur J Hum Genet*. 2001;9(11):811-814.
  99. Nakano J, Muto M, Arikawa K, Hirota T, Asagami C. Acral lentiginous melanoma associated with Down's syndrome. *J Dermatol*. 1993;20(1):59-60.
  100. Jafarian F, Powell J, Kokta V, et al. Malignant melanoma in childhood and adolescence: report of 13 cases. *J Am Acad Dermatol*. 2005;53(5):816-822.
  101. Satge D, Dimoux-Dime G, Godard W, de Fremerville B. Adolescent girl with Down syndrome and lumbar cutaneous melanoma. *Pediatr Dermatol*. 2014;31(1):108-109.
  102. Hassanein AH, Gellis SE, Schmidt BA, Greene AK. Agminated atypical Spitz tumor: large nasal lesion in a child with Down syndrome. *J Pediatr Surg*. 2011;46(7):1435-1437.
  103. Hasle H, Friedman JM, Olsen JH, Rasmussen SA. Low risk of solid tumors in persons with Down syndrome. *Genet Med*. 2016;18(11):1151-1157.

**How to cite this article:** Ryan C, Vellody K, Belazarian L, Rork JF. Dermatologic conditions in Down syndrome. *Pediatr Dermatol*. 2021;38(Suppl. 2):49-57. <https://doi.org/10.1111/pde.14731>