



Contents lists available at ScienceDirect

Journal of ISAKOS

journal homepage: www.elsevier.com/locate/jisakos

Systematic Review

Subscapularis repair techniques for reverse total shoulder arthroplasty: A systematic review



Andrew D. Lachance, BS^a, Annalise M. Peebles, BA^b, Trevor McBride, MD^c, Stephanie K. Eble, BA^d, Matthew T. Provencher, MD, MBA, MC, USNR (Ret.)^{e,*}

^a Tufts University School of Medicine, Boston, MA, USA

^b The Steadman Philippon Research Institute, Vail, CO, USA

^c Sidney Kimmel Medical College, Philadelphia, PA, USA

^d Geisel School of Medicine at Dartmouth, Hanover, NH, USA

^e The Steadman Clinic, Vail, CO, USA

ARTICLE INFO

Keywords:

Subscapularis repair
Reverse total shoulder arthroplasty
Outcomes

ABSTRACT

Importance: Repair of the subscapularis can be effective in the setting of reverse total shoulder arthroplasty (rTSA). However, there has yet to be a consensus on an optimal repair technique.

Objectives: The purpose of this systematic review is to consolidate current high-quality studies comparing outcomes after rTSA with different subscapularis repair techniques.

Evidence review: A comprehensive literature review was conducted according to the preferred reporting items for systematic reviews and meta-Analyses using the PubMed, Embase, Scopus and Cochrane databases for original, English-language studies observing outcomes of rTSA after subscapularis repair published between January 1, 2000 and December 31, 2020. Subscapularis management techniques were repair to (1) tendon (tendon–tendon), (2) prosthetic stem, (3) lesser tuberosity (bone tunnels) or (4) a subscapularis-preserving approach (intact). The repair technique was recorded for included studies, and clinical and functional subjective scores were extracted from text, tables and figures. Forest plots were created to allow for qualitative comparison of the outcomes of interest between subscapularis repair techniques.

Findings: Seven comprehensive studies were identified, which included 367 patients. The mean age of patient at the time of surgery was 71.1 ± 2.8 years (range = 47–87 years). Overall, 259 patients underwent tendon–tendon repair, 48 patients underwent repair to prosthetic stem, 40 patients underwent repair with bone tunnels and 20 patients' subscapularis remained intact. Significant improvement was seen in most studies for Single Assessment Numeric Evaluation (range, Δ 42.6– Δ 46.0 out of 3), American Shoulder and Elbow Surgeons (range, Δ 44.2– Δ 43.6 out of 3) and Visual Analogue Scale pain scores (range Δ 4.2– Δ 6 out of 5). Active forward elevation (range Δ 40.4°– Δ 57.3° out of 4) and active external rotation (range Δ 2.9°– Δ 16.0° out of 4) significantly improved, but forward elevation varied by nearly 17° (Δ 16.94°), while external rotation varied by 13° (Δ 13.16°) among repair techniques. Complications were reported in only one study, which used a tendon–tendon technique.

Conclusions and relevance: This study summarizes the current evidence regarding subscapularis repair techniques after rTSA including functional and subjective clinical outcome scores. Several different subscapularis repair techniques during rTSA appear to lend to sufficient improvement in clinical and subjective outcomes. This information can help guide future studies in this area and highlights the need for high quality studies comparing different subscapularis repair techniques.

Level of evidence: III.

* Corresponding author. Steadman Philippon Research Institute, The Steadman Clinic, 181 W Meadow Dr, Ste 400, Vail, CO 81657, USA. Tel.: +970-479-1596. E-mail address: mprovencher@thesteadmanclinic.com (M.T. Provencher).

<https://doi.org/10.1016/j.jisako.2022.05.001>

Received 15 October 2021; Received in revised form 12 April 2022; Accepted 8 May 2022

Available online 18 May 2022

2059-7754/ Published by Elsevier Inc. on behalf of International Society of Arthroscopy, Knee Surgery and Orthopedic Sports Medicine. This is an open access article under the CC BY license (<http://creativecommons.org/licenses/by/4.0/>).

What is already known?

- Several studies have found subscapularis repair to be safe and effective for the augmentation of reverse total shoulder arthroplasty.
- Reported benefits include decreased risk of early dislocation, and improved clinical and functional outcomes.

What are the new findings?

- Several different subscapularis repair techniques during reverse total shoulder arthroplasty (rTSA) appear to lend to sufficient improvement in clinical and subjective outcomes.
- This information can help guide future studies in this area and highlights the need for high-quality studies comparing different subscapularis repair techniques.

Introduction

Reverse total shoulder arthroplasty (rTSA) is an evolving treatment option for cuff tear arthropathy and shoulder pseudoparalysis secondary to massive rotator cuff tear, fracture, tumour, instability or revision arthroplasty [7]. Compared to anatomic total shoulder arthroplasty (TSA), rTSA provides advantages such as medializing the centre of rotation, maximizing deltoid efficiency and providing more stability [20].

Several studies have found subscapularis repair to be safe and effective for the augmentation of rTSA [3–6]. Biomechanical and cadaveric studies have demonstrated that following rTSA without subscapularis repair, less force is required by the deltoid and posterior rotator cuff muscles in order to abduct the arm [11,13]. Additionally, patients undergoing rTSA without repair of the subscapularis tendon or those with an irreparable subscapularis tendon have shown an increased risk of early dislocation [3,8].

While several studies have investigated the outcomes of rTSA with subscapularis repair, there has yet to be a review of the literature examining different repair techniques of the subscapularis tendon. In TSA, subscapularis tenotomy with tendon-to-tendon repair has traditionally been the standard of care, while other techniques such as lesser tuberosity osteotomy and subscapularis peel were developed to improve healing, the strength of repair and function [17]. The subscapularis peel technique, which repairs tendon to bone, allows the subscapularis insertion to be medialized, resulting in increased external rotation [5] and improved tendon to bone healing [1]. While there have been positive results for the peel technique, there have been some reports of subscapularis deficiency and lower functional outcomes [2].

With this purpose in mind, we performed a systematic review to summarize the existing literature on outcomes after rTSA with different subscapularis repair techniques. Based on the existing literature, we expect no difference in clinical and functional subjective scores according to the subscapularis repair technique following rTSA.

Methods*Literature search*

A comprehensive literature review was conducted according to the Preferred Reporting Items for Systematic Reviews and Meta-Analyses (PRISMA) using the PubMed, Embase, Scopus and Cochrane databases for all articles. This combination search strategy employed the following keywords: (“rTSA OR “reverse total shoulder arthroplasty”) AND (“subscapularis repair”) AND (“plate” OR “tendon” OR “tenotomy” OR “anchor” OR “repair to stem”) AND (“outcomes”). Eligible articles were

deemed as those published in English between January 1, 2000 and December 31, 2020, yielding 318 unique publications that were subsequently screened for inclusion.

Study selection

Articles captured in the initial search were excluded from the review if they were published before the year 2000 or in a non-English language. The titles and abstracts of all resulting articles were independently investigated by three authors (A.M.P., T.M. and A.D.L.) to determine relevancy to rTSA outcomes with and without subscapularis repair. Following the initial title and abstract screening, the remaining studies were meticulously reviewed by each author utilizing the following inclusion criteria: clinical trials, RCTs, and cohort studies that examined quantifiable outcomes of rTSA with/without subscapularis repair, peer-reviewed clinical studies with evidence level I-IV and that were at least 6-months follow-up after the index rTSA. Articles that met each of these criteria were included in the systematic review. Articles were excluded if they included fracture repair, revision surgery, case reports, systemic reviews, surveys, animal studies or cadaveric studies. Additionally, the references of each included study were reviewed for additional publications that were not captured in the initial database search.

Patient demographics, subscapularis repair status, surgical technique, outcome measures, complication rates and a total number of revisions were obtained from each article.

Study risk of bias assessment

Screening at each level and for each study was performed by two reviewers in a blinded fashion in order to eliminate inter-observer bias. A third reviewer was used to settle any conflicts. Grading for levels of evidence was performed in the same manner to ensure minimal bias. Levels I through IV were included during the review to minimize the risk of bias from any studies of lesser quality.

Data analysis

Due to a limited number of studies eligible for inclusion, a statistical comparison of outcomes was not performed. Forest plots were created to allow for qualitative comparison of the outcomes of interest. Plots were utilized for outcomes when three or more studies reported results (Single Assessment Numeric Evaluation [SANE], American Shoulder and Elbow Surgeons [ASES], visual analogue scale [VAS], forward elevation [FE] and external rotation [ER]). Means and 95% confidence intervals, based on calculated standard errors, are reported.

Results*Search results*

The initial search generated 318 articles that were reviewed by the lead investigators (A.M.P., T.M. and A.D.L.) in which 28 abstracts were relevant to our review. Seven publications [4,9,10,15,16,19,23] (four retrospective case-control level III and three case series level IV) were eligible for our inclusion–exclusion criteria and were included in the analysis of our final review. A summary of the flowchart of our literature search according to PRISMA guidelines can be found in Fig. 1.

Demographics

Of the 7 studies included, there were a total of 367 patients. The mean age of patient at the time of surgery was 71.1 ± 2.8 years (range = 47–87 years). Mean patient follow-up was reported for six studies [4,9,10,15, 16,19,23] (86%) and was 13.54 ± 11.2 months (range = 6–91 months), while mean percent follow-up was 81%. Indications for surgery included rotator cuff (RC) arthropathy, glenohumeral osteoarthritis, irreparable

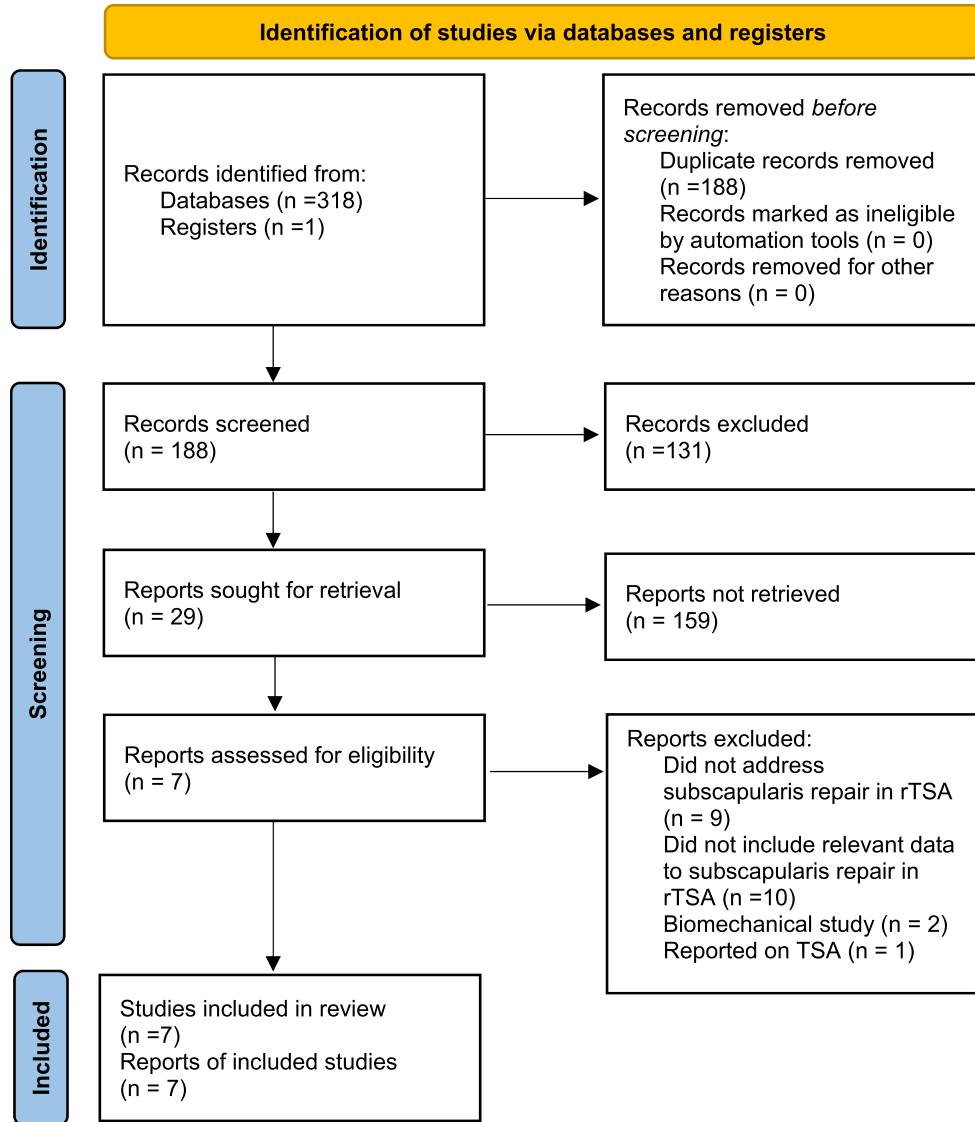


Fig. 1. Flow diagram displaying the systematic review of search strategy.

massive RC tear, migration of the humeral head, inflammatory arthritis with RC tear and failed prior RC repair. Patient demographics can be viewed in Table 1.

Surgical techniques

Two studies performed only a tenotomy of the subscapularis, one of which repaired tendon-to-tendon [15] (tendon–tendon), and the other repaired the subscapularis to the prosthetic stem [9]. One study used a subscapularis-preserving approach in which the subscapularis remained intact during the entirety of the procedure [16] (intact). Three studies directly compared a tenotomy of the subscapularis with subsequent repair using the tendon–tendon approach versus no repair [4,10,23]. One study directly compared a tenotomy of the subscapularis with subsequent attachment to the lesser tuberosity bone tunnels versus no repair [19] (Table 2). Overall, 259 patients underwent tendon–tendon repair, 48 patients underwent repair to prosthetic stem, 40 patients underwent bone tunnel repair and 20 patients’ subscapularis remained intact (see Table 3).

Table 1

Patient demographics. Patient age and follow-up are represented as mean (S.D.).

Studies, n	7
Patients, n	367
Mean age, y	71.1 (2.8)
Age range, y	47 to 87
Mean follow-up, m	13.5 (11.2)
Follow-up range, m	6 to 91

Clinical and patient-reported outcomes

Clinical and patient-reported outcomes were reported in all reviewed studies (100%) [4,9,10,15,16,19,23]. The most commonly reported clinical and functional subjective scores included ER [4,9,10,15,16,19,23] (100%), FE [4,9,10,15,16,19,23] (86%), visual analogue scale (VAS) (71%) [9,10,15,16,19], ASES assessment (71%) [4,9,15,19,23] and SANE (57%) [11,9,15,16]. Strength outcomes were deployed in only two studies (29%) [15,19]. Simple Shoulder Test [19] and Constant-Murlay

Table 2
Summary of individual studies.

Study	Type of Study (Level of Evidence)	Study Population (N)	Subscapular Intervention	Outcome
Oh et al.	Retrospective (Level III)	N = 40	Peel	<ul style="list-style-type: none"> Significant improvement in ASES, VAS scores, ER and FE for both subscapularis repair and non-repair group No significant difference between repair and non-repair group
Khazzam et al.	Case series (Level IV)	N = 20	Tendon-tendon	<ul style="list-style-type: none"> Significant improvement in ASES, SANE, VAS scores, ER and FE
Erickson et al.	Case series (Level IV)	N = 48	Prosthetic Stem	<ul style="list-style-type: none"> Significant improvement in ASES, SANE, VAS scores, ER and FE
De Boer et al.	Retrospective case control (Level III)	N = 65	Tendon-tendon	<ul style="list-style-type: none"> Reported no significant difference between subscapularis repair and non-repair groups Postoperative VAS scores, FE and ER were recorded as 'non-significant' improvements. Not quantified. Significant improvement in VAS scores, ER, intrarotation, ABER and FE for both subscapularis repair and non-repair group
Franceschetti et al.	Retrospective (Level III)	N = 88	Tendon-tendon	<ul style="list-style-type: none"> Patients with tendon-tendon repair significantly better intrarotation Patients with no repair significantly better ABER Significantly improved SANE, VAS scores
Ladermann et al.	Case series (Level IV)	N = 20	Subscapularis-preserving (Intact)	<ul style="list-style-type: none"> No significant improvement in FE and ER
Vourazeris et al.	Retrospective (Level III)	N = 86	Tendon-tendon	<ul style="list-style-type: none"> Significant improvement in ASES, ER and FE for both subscapularis repair and non-repair group No significant difference between repair and non-repair group

ASES = American Shoulder and Elbow Surgeons; SANE = Single Assessment Numeric Evaluation; VAS = Visual Analog Scale; ABER = Abduction and External Rotation; FE = Forward Elevation; ER = External Rotation.

Table 3
Coleman methodology scores.

Author	Study Size (10)	Mean Follow-Up (5)	No. of Surgical Interventions per Group (10)	Study Type (15)	Diagnostic Certainty (5)	Description of Surgical Technique (5)	Description of Postoperative Rehabilitation (5)	Outcome Criteria (10)	Procedure for Assessing Outcomes (15)	Description for Participant Selection Process (15)	Total (100)
De Boer et al. [4]	10	5	10	0	5	3	10	10	3	10	66
Erickson et al. [9]	7	2	10	0	5	5	10	10	3	10	62
Franceschetti et al. [10]	10	2	10	0	5	0	0	10	3	5	50
Khazzam et al. [15]	4	2	10	0	5	5	10	10	6	10	62
Ladermann et al. [16]	4	0	10	0	5	5	10	10	3	10	57
Oh et al. [19]	10	5	10	0	5	5	10	10	3	5	63
Vourazeris et al. [23]	10	5	10	0	5	5	10	10	6	10	71

Shoulder Score [10] were each reported in only one study, respectively (14%).

Significant post-operative improvement

Subjective outcome scores

All studies (100%) in this review compared pre- and post-operative clinical and patient-reported outcome scores [4,9,10,15,16,19,23]. Significant improvement in SANE was observed in three [9,15,16] cases (range, Δ 42.6–Δ 46.0) (Fig. 2), of which included tendon–tendon repair [14] (p < 0.001), repair to prosthetic stem [12] (p < 0.001) and an intact approach [15] (p < 0.001). Significant improvement was also observed in ASES scores in three [12,14,16] cases (range Δ44.2–Δ43.6) (Fig. 3), including repair to stem [12] (p < 0.001), tendon–tendon repair [14] (p < 0.001) and bone tunnel [16] (p = 0.025). Reported VAS scores significantly improved with all techniques [9,10,15,16,19] (range Δ 4.2–Δ 6, p < 0.05) (Fig. 4). Notably, Khazzam et al. [14], which used a tendon–tendon repair technique, reported the greatest decrease in VAS score (Δ6, p < 0.001).

Range of motion

Significant improvement in active FE [9,10,12–15,19,23] (range Δ 40.4°–Δ 57.4°, p < 0.05) (Fig. 5) and ER [9,10,12–15,19,23] (range Δ 2.9°–Δ 16.0°, p < 0.05) (Fig. 6) were observed in almost all studies in which a tendon–tendon [13,14,17], bone tunnels [19] and repair to stem [12] were used. No significant improvement in FE or ER was observed in studies performed by De Boer et al. [4] and Ladermann et al. [16], which utilized a tendon–tendon repair and intact technique, respectively. Interestingly, repair of the subscapularis using a tendon–tendon technique [13] recorded the largest increase in both postoperative ER (Δ 16.02°, p = 0.01) [13] and largest increase in postoperative FE (Δ 57.4°, p = 0.008) [14].

Among the four retrospective studies that directly compared the subscapularis repair group to a non-repair cohort, three [4,19,23] (tendon–tendon repair or bone tunnels) reported no significant difference between pre-and post-operative clinical or patient-reported outcome scores. Interestingly, Franceschetti et al. [10] found that patients who underwent subscapularis repair using a tendon–tendon approach had significantly better post-operative internal rotation (p = 0.02), while patients who did not undergo subscapularis repair had significantly better abduction (p = 0.04).

Complications were reported in only one study [17], which used a tendon–tendon technique. A total of 6% (7 out of 116 patients) experienced complications that included postoperative infection, base plate failure, humeral component loosening and dislocation.

Discussion

The current review found that reported clinical and functional outcomes were comparable among all subscapularis repair techniques. Postoperative SANE scores improved similarly using a tendon–tendon [14], repair to prosthetic stem [12] or intact approach [15] (Δ3.2). Additionally, ASES scores reported similar improvement using a tendon–tendon [14], bone tunnels [16] and repair to prosthetic stem technique [12] (Δ2.4). VAS scores significantly improved for all repair techniques [12–16], with little variability (Δ1.82). However, post-operative range of motion reported more inconsistent results, as FE varied by nearly 17° (Δ16.94°), while ER varied by 13° (Δ13.16°) among repair techniques. A tendon–tendon repair technique was used in both studies that reported the greatest increase in FE [14] and ER [13].

The findings of the current study suggest that subjective post-operative scores, including ASES and SANE, are comparable among intact, prosthetic stem, tendon–tendon and bone tunnel subscapularis repair techniques performed during rTSA. These observations are consistent with a case control study by Hartline et al. [14] that examined differences in postoperative outcomes between patients that underwent a tendon–tendon, prosthetic stem and no-repair subscapularis management techniques during primary rTSA. The study found no significant difference in subjective outcome scores (ASES), complications or reoperations (p > 0.05). Interestingly, Hartline et al. [14] observed that subscapularis repair—regardless of technique—resulted in significantly greater postoperative pain improvement (VAS) than the non-repair group. These findings are consistent with the current review that observed homogenously significant improvement in VAS among all subscapularis repair techniques. While the current review does not directly compare repair techniques to a non-repair cohort, Godin et al. [12] suggest that the sufficiency of the subscapularis tendon is an important factor resulting in better subjective outcome scores. These results suggest that patients with healthier subscapularis preoperatively have less shoulder pathology potentially resulting in independently better postoperative subjective outcomes scores. Thus, the competency of the subscapularis preoperatively is a notable confounding variable that may attribute to improved patient-reported outcomes.

Variable outcomes in postoperative ROM depending on subscapularis management technique warrants further investigation. The current review found that improvement in postoperative FE varied by nearly 17°, while ER varied by 13°. A tendon–tendon repair technique was used in both studies that reported the greatest increase in postoperative FE [14] and ER [13]. Franceschetti et al. [10] found patients undergoing subscapularis repair using a tendon–tendon approach and had significantly better post-operative internal rotation versus patients who did not

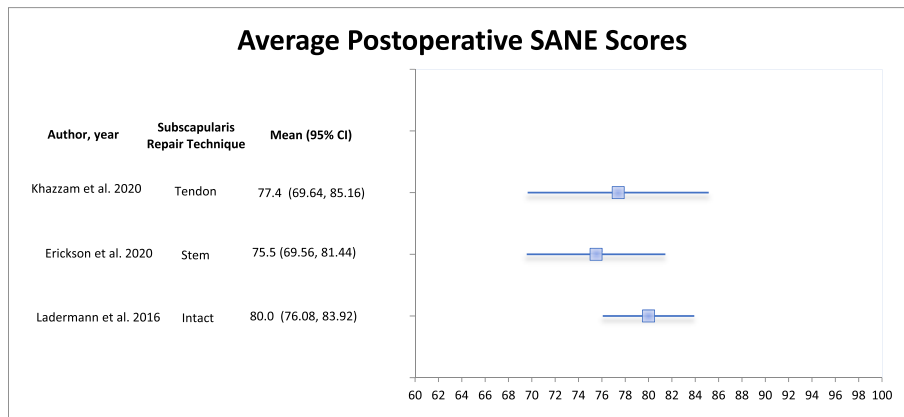


Fig. 2. Forest plot of mean pre-to postoperative reported SANE scores with 95% Confidence Intervals. Significant improvement in SANE was observed in three cases (range, Δ 42.6–Δ 46.0), of which included tendon–tendon repair [14] (p < 0.001), repair to prosthetic stem [12] (p < 0.001), and an intact approach [15] (p < 0.001).

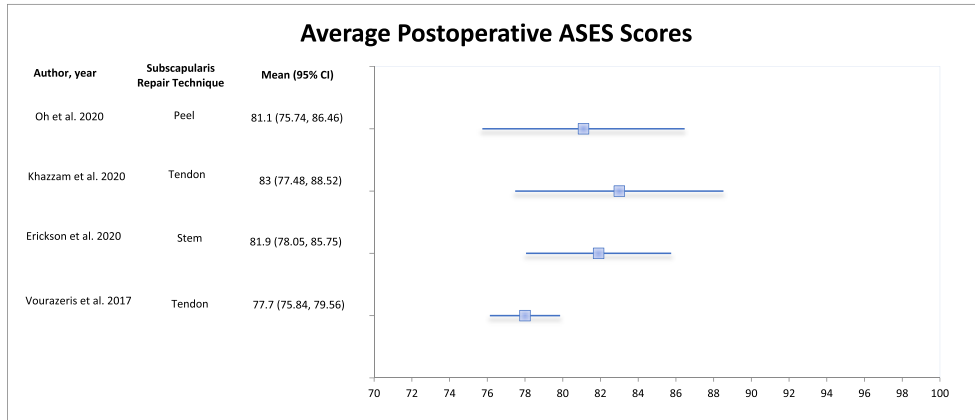


Fig. 3. Forest plot of mean pre-to postoperative reported ASES scores with 95% Confidence Intervals. Significant improvement was observed in ASES scores in three cases (range Δ 44.2– Δ 43.6), including repair to stem [12] ($p < 0.001$), tendon–tendon repair [14] ($p < 0.001$) and bone tunnelling [16] ($p = 0.025$).

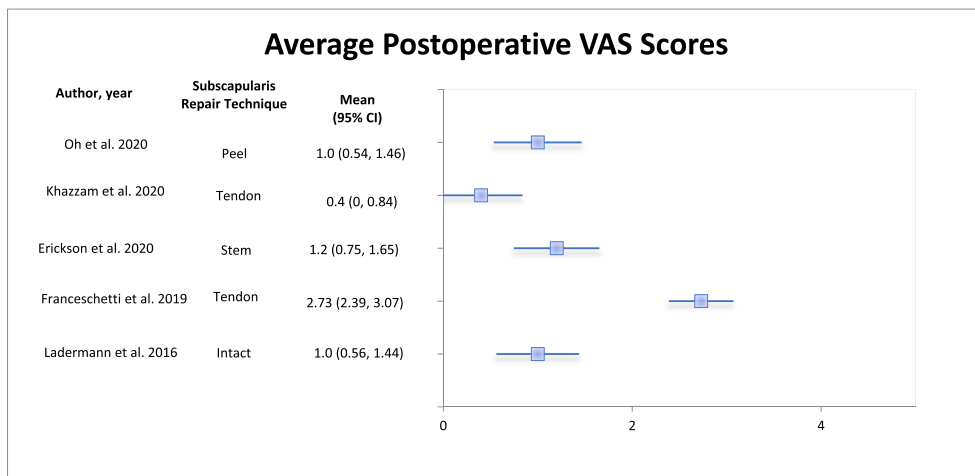


Fig. 4. Forest plot of mean pre-to postoperative reported VAS scores with 95% Confidence Intervals. Reported VAS scores significantly improved with all techniques (range Δ 4.2– Δ 6, $p < 0.05$).

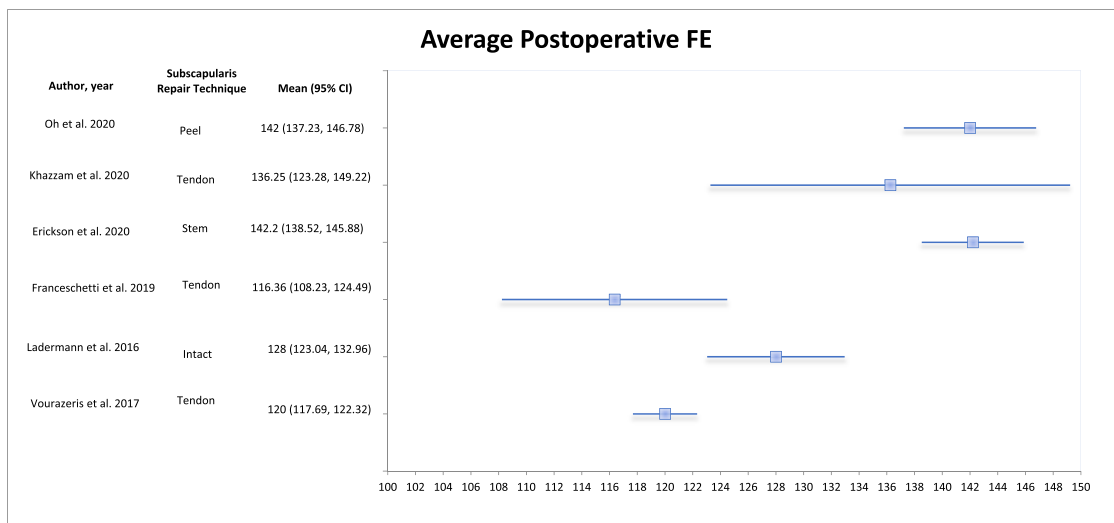


Fig. 5. Forest plot of mean pre-to postoperative reported active Forward Elevation (FE) scores with 95% Confidence Intervals. Significant improvement in FE was observed in almost all studies, which included a tendon–tendon, bone tunnelling, and repair to stem technique (range Δ 40.4°– Δ 57.4°, $p < 0.05$).

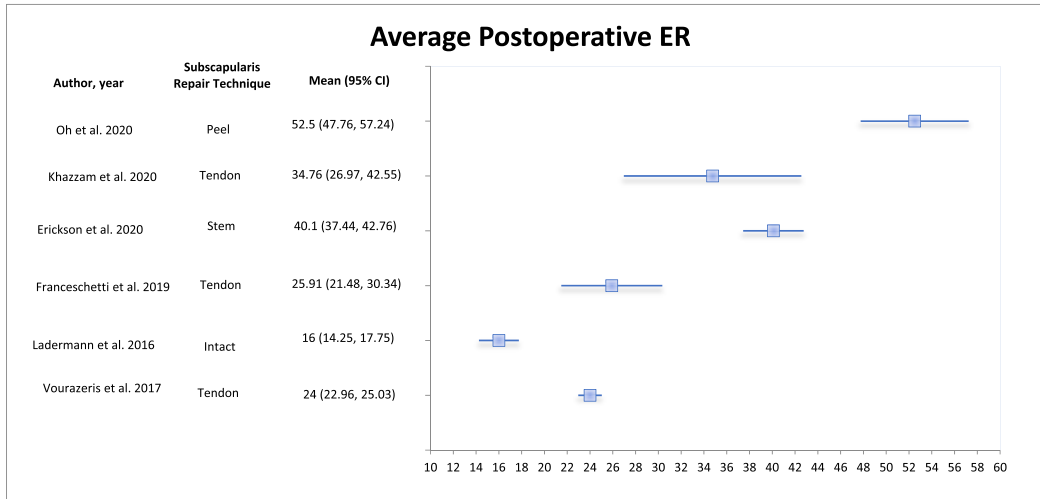


Fig. 6. Forest plot of mean pre-to postoperative reported active external rotation (ER) with 95% Confidence Intervals. Significant improvement in FE was observed in almost all studies, which included a tendon–tendon, bone tunnelling and repair to stem technique (range Δ 2.9°– Δ 16.0°, $p < 0.05$).

undergo subscapularis repair had significantly better abduction. These results may suggest an altered force vector by repairing the subscapularis non-anatomically.

While studies have found that subscapularis repair in rTSA can affect postoperative ROM due to antagonistic forces of the subscapularis exerted on the posterior RC [13], variability is observed among *types* of subscapularis repair techniques. This difference could be explained by a plethora of potential confounding factors including patient population, age and surgeon experience. The results of the current review are consistent with the findings of Hartline et al. [14], which observed a significantly greater improvement in ER strength among patients who underwent a tendon–tendon subscapularis repair than a bone–tendon repair. However, Khazzam et al. [15], who also used a tendon–tendon repair technique, reported only a 2.8° improvement in ER — 11.5° less than the second lowest pre-to postoperative improvement in ER. While the differences in ER and FE outcomes among repair techniques remain uncertain, we speculate this observed difference could relate to the length of the repaired tendon. In a cadaveric study by Van den Berghe et al. [22] that examines the effect of subscapularis repair techniques on ROM in TSA, it was found that tendon–tendon repairs shortened the subscapularis by 5.3 mm while a tendon–bone repair lengthened the tendon by an average of 2.6 mm [22]. One centimetre of subscapularis shortening may cause a 20° loss of ER [18], thus shortening the subscapularis tendon may have considerable effects on ROM depending on the repair technique.

At present, the paucity of literature comparing lesser tuberosity osteotomy (LTO) to tenotomy or peel technique in rTSA leaves this review incomplete. Comparing these techniques in patients undergoing TSA, a meta-analysis by Del Core et al. [6] found that LTO had superior healing and subscapularis specific strength testing. However, there was no difference in ROM between peel, tenotomy and LTO with all groups showing improvement in patient-reported outcomes. These findings regarding improvements in patient-reported outcomes using the peel and tenotomy techniques are consistent with their utilization in rTSA in our study. Nevertheless, there is little literature on LTO utilization in rTSA. While there are different techniques, several studies have shown that LTO is biomechanically superior and has favourable healing rates compared with the peel or tenotomy techniques [21]. It could be speculated that the patient populations undergoing rTSA are older, with weaker bones for which surgeons are less likely to utilize LTO. Further study is required if there is any potential utility for LTO in rTSA.

There are several notable limitations of the current study. Systematic reviews are inherently limited by the relevant data reported in the

literature. To date, there has been no level one or level two studies regarding rTSA and subscapularis repair. As such, the current study carries the same biases as those of non-randomized and retrospective analyses. Furthermore, the tendon-to-tendon repair technique was overrepresented as it was performed in five of the seven studies. Within subscapularis repair, there are many other variables that may affect outcomes including preoperative ROM, implant characteristics and preoperative subscapularis competency which make these results more difficult to interpret independently. Surgeon experience, patient age and patient populations are also impossible to control for in comparisons made in a review article. Additionally, the heterogeneity of shoulder outcome scores utilized made the analysis more challenging. There were limited studies to compare these techniques, preventing a deeper statistical analysis.

Conclusion

With the sparsity of high-quality literature, further study is required to accurately compare subscapularis repair techniques after rTSA. While tendon–tendon repair was overrepresented in this study, all repair techniques examined in this study appear to achieve successful functional and subjective clinical outcome scores. Although a comparison was not made to a non-repair group, this review displays that subscapularis repair techniques have little impact on both subjective and objective clinical outcomes. This information can help guide future studies in this area.

Declaration of competing interest

The authors declare that they have no known competing financial interests or personal relationships that could have appeared to influence the work reported in this paper.

References

- [1] Bornes TD, Rollins MD, Lapner PL, Bouliane MJ. Subscapularis management in total shoulder arthroplasty: current evidence comparing peel, osteotomy, and tenotomy. *J Shoulder Elbow Arthroplasty* 2018;2:2471549218807772. <https://doi.org/10.1177/2471549218807772>.
- [2] Buckley T, Miller R, Nicandri G, Lewis R, Voloshin I. Analysis of subscapularis integrity and function after lesser tuberosity osteotomy versus subscapularis tenotomy in total shoulder arthroplasty using ultrasound and validated clinical outcome measures. *J Shoulder Elbow Surg* 2014;23:1309–17. <https://doi.org/10.1016/j.jse.2013.12.009>.
- [3] Chalmers PN, Rahman Z, Romeo AA, Nicholson GP. Early dislocation after reverse total shoulder arthroplasty. *J Shoulder Elbow Surg* 2014;23:737–44. <https://doi.org/10.1016/j.jse.2013.08.015>.

- [4] de Boer FA, van Kampen PM, Huijsmans PE. The influence of subscapularis tendon reattachment on range of motion in reversed shoulder arthroplasty: a clinical study. *Musculoskelet Surg* 2016;100:121–6. <https://doi.org/10.1007/s12306-016-0401-8>.
- [5] DeFranco MJ, Higgins LD, Warner JJ. Subscapularis management in open shoulder surgery. *J Am Acad Orthop Surg* 2010;18(12):707–17. <https://doi.org/10.5435/00124635-201012000-00001>.
- [6] Del Core MA, Cutler HS, Ahn J, Khazzam M. Systematic review and network meta-analysis of subscapularis management techniques in anatomic total shoulder arthroplasty. *J Shoulder Elbow Surg* 2021;Jul;30(7):1714–24. <https://doi.org/10.1016/j.jse.2020.09.027>.
- [7] Drake GN, O'Connor DP, Edwards TB. Indications for reverse total shoulder arthroplasty in rotator cuff disease. *Clin Orthop Relat Res* 2010;468:1526–33. <https://doi.org/10.1007/s11999-009-1188-9>.
- [8] Edwards TB, Williams MD, Labriola JE, Elkousy HA, Gartsman GM, O'Connor DP. Subscapularis insufficiency and the risk of shoulder dislocation after reverse shoulder arthroplasty. *J Shoulder Elbow Surg* 2009;18:892–6. <https://doi.org/10.1016/j.jse.2008.12.013>.
- [9] Erickson BJ, Shishani Y, Bishop ME, Patel M, Jones S, Romeo AA, et al. Subscapularis repair during reverse total shoulder arthroplasty using a stem-based double-row repair: sonographic and clinical outcomes. *Orthop J Sports Med* 2020;8:2325967120906806. <https://doi.org/10.1177/2325967120906806>.
- [10] Franceschetti E, de Sanctis EG, Ranieri R, Palumbo A, Paciotti M, Franceschi F. The role of the subscapularis tendon in a lateralized reverse total shoulder arthroplasty: repair versus nonrepair. *Int Orthop* 2019;43:2579–86. <https://doi.org/10.1007/s00264-018-4275-2>.
- [11] Giles JW, Langohr GDG, Johnson JA, Athwal GS. The rotator cuff muscles are antagonists after reverse total shoulder arthroplasty. *J Shoulder Elbow Surg* 2016;25:1592–600. <https://doi.org/10.1016/j.jse.2016.02.028>.
- [12] Godin JA, Pogorzelski J, Horan MP, Lacheta L, Hussain ZB, Altintas B, et al. Impact of age and subscapularis tendon reparability on return to recreational sports activities and 2-year outcomes after reverse total shoulder arthroplasty. *Orthop J Sports Med* 2019;7:2325967119875461. <https://doi.org/10.1177/2325967119875461>.
- [13] Hansen ML, Nayak A, Worhac K, Stowell R, Roche CP. Role of subscapularis repair on muscle force requirements with reverse shoulder arthroplasty. *Bull Hosp Joint Dis* 2015;73:S21. PMID: 26631191.
- [14] Hartline JT, Brodin TJ, Wan JY, Dibaba DT, Azar FM, Throckmorton TW. The effect of subscapularis management technique on outcomes and complication rates following reverse total shoulder arthroplasty. In: *Seminars in arthroplasty*: JSES. Elsevier; 2020. p. 42–9. <https://doi.org/10.1053/j.sart.2020.04.005> (ISBN No. 1045-4527).
- [15] Khazzam M, Reyes B, Phelan A, Gates S. Subscapularis integrity, function and EMG/nerve conduction study findings following reverse total shoulder arthroplasty. *JSES Int* 2020;4:680–7. <https://doi.org/10.1016/j.jseint.2020.02.015>.
- [16] Lädermann A, Lo EY, Schwitzguébel AJ, Yates E. Subscapularis and deltoid preserving anterior approach for reverse shoulder arthroplasty. *Orthop Traumatol Surg Res* 2016;102:905–8. <https://doi.org/10.1016/j.otsr.2016.06.005>.
- [17] Lapner PL, Sabri E, Rakhra K, Bell K, Athwal GS. Comparison of lesser tuberosity osteotomy to subscapularis peel in shoulder arthroplasty: a randomized controlled trial. *J Bone Joint Surg Am* 2012;94(24):2239–46. <https://doi.org/10.2106/JBJS.K.01365>.
- [18] Matsen 3rd F, Zuckerman JD. Anterior glenohumeral instability. *Clin Sports Med* 1983;2:319–38. PMID:9697641.
- [19] Oh JH, Sharma N, Rhee SM, Park JH. Do individualized humeral retroversion and subscapularis repair affect the clinical outcomes of reverse total shoulder arthroplasty? *J Shoulder Elbow Surg* 2020;29:821–9. <https://doi.org/10.1016/j.jse.2019.08.016>.
- [20] Rugg CM, Coughlan MJ, Lansdown DA. Reverse total shoulder arthroplasty: biomechanics and indications. *Current Rev Musculoskeletal Med* 2019;12(4):542–53. <https://doi.org/10.1007/s12178-019-09586-y>.
- [21] Schrock JB, Kraeutler MJ, Crellin CT, McCarty EC, Bravman JT. How should I fixate the subscapularis in total shoulder arthroplasty? A systematic review of pertinent subscapularis repair biomechanics. *Shoulder Elbow* 2017;9:153–9. <https://doi.org/10.1177/1758573217700833>.
- [22] Van den Berghe GR, Nguyen B, Patil S, D'Lima DD, Mahar A, Pedowitz R, et al. A biomechanical evaluation of three surgical techniques for subscapularis repair. *J Shoulder Elbow Surg* 2008;17(1):156–61. <https://doi.org/10.1016/j.jse.2007.04.016>.
- [23] Vourazeris JD, Wright TW, Struk AM, King JJ, Farmer KW. Primary reverse total shoulder arthroplasty outcomes in patients with subscapularis repair versus tenotomy. *J Shoulder Elbow Surg* 2017;26:450–7. <https://doi.org/10.1016/j.jse.2016.09.017>.