



ELSEVIER

Contents lists available at ScienceDirect

JSES Reviews, Reports, and Techniques

journal homepage: www.jsesreviewsreportstech.org

Shoulder strength outcomes after reverse total shoulder arthroplasty: a systematic review and descriptive synthesis

Fletcher R. Preuss, MD^a, Stephanie K. Eble, BA^b, Annalise M. Peebles, BA^c, Antonia Osuna-Garcia, MLIS^d, CAPT Matthew T. Provencher, MD, MBA, MC, USNR (ret)^{c,e,*}^aDavid Geffen School of Medicine at The University of California Los Angeles, Los Angeles, CA, USA^bGeisel School of Medicine at Dartmouth College, Hanover, NH, USA^cThe Steadman Philippon Research Institute, Vail, CO, USA^dLouise M. Darling Biomedical Library, The University of California Los Angeles, Los Angeles, CA, USA^eThe Steadman Clinic, Vail, CO, USA

ARTICLE INFO

Keywords:

rTSA
Reverse total shoulder arthroplasty
Subscapularis
Strength
Postoperative outcomes
Range of motion*Level of evidence:* Level IV; Systematic Review

Hypothesis and Background: There is no differences in abduction, internal rotation, or external rotation strength after reverse total shoulder arthroplasty (rTSA) with or without subscapularis repair. Repair of the subscapularis can be effective in the setting of rTSA. However, consensus has yet to be reached on whether postoperative strength after rTSA differs based on subscapularis management. The purpose of this review is to evaluate shoulder strength outcomes after rTSA with and without subscapularis tendon repair.

Methods: A comprehensive literature review was conducted using the key terms “subscapularis” AND “reverse total shoulder arthroplasty” AND “muscle strength” in PubMed, Embase, Web of Science, Cochrane Reviews and Trials, and Scopus. Original, English-language studies evaluating shoulder strength outcomes after rTSA published from January 1, 2000, to present were evaluated. Strength outcomes reported included abduction strength (kg) and internal rotation strength (kg) using an electric spring balance and external rotation strength (lb) using a handheld dynamometer. Heterogeneity of data in the included studies did not allow for meta-analysis.

Results: The search yielded 4253 unique results, which were screened for inclusion according to the Preferred Reporting Items for Systematic Reviews and Meta-Analyses (PRISMA). Two articles met eligibility criteria and were included in the final full-text review. A total of 267 shoulders were represented, 111 with subscapularis repair and 156 without subscapularis repair. No significant differences in abduction ($P = .39$), internal rotation ($P = .09$), and external rotation ($P = .463$) strength were observed between subscapularis repair and nonrepair groups.

Conclusion: There were no differences in abduction, internal rotation, or external rotation strength after rTSA with or without subscapularis repair. The literature on postoperative strength outcomes after rTSA is limited, and further study in this area is warranted.

Published by Elsevier Inc. on behalf of American Shoulder & Elbow Surgeons. This is an open access article under the CC BY-NC-ND license (<http://creativecommons.org/licenses/by-nc-nd/4.0/>).

Reverse total shoulder arthroplasty (rTSA) is a surgical technique that was approved for use in the United States in the early 2000s.¹⁵ The prosthetic design compensates for rotator cuff deficiency through medialization of the glenohumeral region such that the deltoid functions to both elevate and abduct the glenohumeral joint.¹² While the prosthesis utility has expanded to address various glenohumeral bony pathologies and cases of severe chronic

instability,⁵ management of the subscapularis tendon during rTSA remains a topic of debate.

At present, several recommended techniques have been described in the literature for management of the subscapularis during rTSA, but currently there is no consensus on whether or not to repair the tendon after placement of the prosthesis or on effects to patient outcomes of repair vs. no repair. Some literature suggests that an unrepaired subscapularis after rTSA increases risk of instability, while other studies have shown no difference in dislocation rates between repaired and unrepaired subscapularis.^{1,6} Regarding surgical techniques for subscapularis management, some authors support tenotomy and subsequent reattachment,⁶ while other authors suggest no significant difference in outcomes

Institutional review board approval was not required for this systematic review.
*Corresponding author: CAPT Matthew T. Provencher, MD, MBA, MC, USNR (ret), The Steadman Clinic, 181 West Meadow Drive, Suite 400, Vail, CO 81657, USA.
E-mail address: mprovencher@thesteadmanclinic.com (C.M.T. Provencher).

based on treatment with lesser tuberosity osteotomy, subscapularis peel or tenotomy, or no repair.⁴ Other studies have examined the relationship between rTSA subscapularis management and shoulder strength outcomes.^{7,8,10,16} A study conducted by Ersen et al¹⁰ found that isokinetic strength of the shoulder did not significantly improve after subscapularis tendon repair and that internal and external rotational strength were significantly lower in operated shoulders than in patients' contralateral shoulders. In addition, a study by Vourazeris et al¹⁶ found no significant difference in strength outcomes between patients who underwent subscapularis tenotomy with subsequent repair and those who did not undergo subscapularis tendon repair.

Studies attempting to decrease postoperative shoulder instability and improve postoperative shoulder function have focused on alternative subscapularis surgical management techniques.^{3,11,13} There is currently no review of the literature on strength outcomes after rTSA with respect to subscapularis repair. The purpose of this systematic review was to investigate differences in strength outcomes after rTSA based on subscapularis management. We hypothesized that subscapularis repair will not produce a significant difference in strength outcomes after rTSA.

Methods

Search strategy

This study was conducted in accordance with the 2009 Preferred Reporting Items for Systematic Review and Meta-Analysis (PRISMA) statement. Registration of this systematic review was performed in February 2021 using the PROSPERO International prospective register of systematic reviews (registration number: [CRD42021239760](https://doi.org/10.1111/CRD4.2021239760)).

The search strategies were developed by a health sciences librarian who translated the search concepts using each database platform's search fields and field tags. The following databases were searched using the aforementioned strategies: PubMed (includes Medline), Embase, Web of Science, Cochrane Reviews and Trials, and Scopus.

For the search terms, MeSH, Emtree, and keywords were used for the concepts of subscapularis, rTSA, and muscle strength. All three concepts were combined with the "AND" Boolean operator (see [Appendix 1](#) for detailed search strategies). A date limit was applied to each search strategy to obtain articles published beginning January 2000 to March 2021. Final searches were completed on March 5, 2021, and references downloaded for deduplication.

Deduplication was conducted using Bramer's instructions for deduplication of search results in EndNote.² The total number of results downloaded from all databases searched was 7551, and 3298 duplicate results were removed, leaving the final number of results at 4253. The deduplicated results were exported to an Excel file for final review and appraisal.

Article selection

A total of 4253 articles were screened by two authors to exclude articles not related to the topic of interest (FRP, SKE). A third independent review was used to resolve any existing conflicts (AMP). Articles were reviewed in full, and references checked to ensure no further relevant articles were missing from the present review. Articles were excluded if they included anatomic total shoulder arthroplasty, bilateral rTSA, fracture repair, revision surgery, case studies, or cadaveric studies. Patient demographics, subscapularis

repair status, surgical technique, and strength outcomes were evaluated for each article meeting inclusion criteria.

Results

Search results

After title, abstract, and full-text review with application of exclusion criteria, two studies (Vourazeris et al, 2017; de Boer et al, 2016)^{7,16} were included for data analysis, both retrospective studies (level III evidence). Heterogeneity of the data in the two included studies did not allow for meta-analysis. A PRISMA flowchart summarizing the literature search is presented in [Figure 1](#).

Demographics

Across the two studies included in the final review, a total of 267 shoulders were represented. One hundred eleven patients underwent subscapularis repair, and 156 patients did not undergo subscapularis repair. Indications for surgery included rotator cuff (RC) arthropathy, glenohumeral osteoarthritis, inflammatory arthritis with RC tear, and avascular necrosis of the humeral head with RC tear. Patient demographics for each study are presented in [Table I](#). In both studies, mean patient age and mean patient follow-up were similar between groups. For the studies by de Boer et al and Vourazeris et al, percent follow-up was 51.2% and 91.4%, respectively.^{7,16}

In addition to assessing strength and clinical outcomes, de Boer et al also performed postoperative ultrasound examination to assess the status of the subscapularis tendon. Patients who had a subscapularis repair (n = 25) were further divided into two groups based on the presence (present, n = 10) or absence (absent, n = 15) of the intact subscapularis tendon on ultrasound.

Surgical techniques

In the cohort of de Boer et al, an Aequalis reverse shoulder prosthesis (Tornier, Montbonnot, France) was placed in all patients.⁷ When the subscapularis tendon quality was deemed sufficient and the lesser tuberosity was suitable for reattachment, a transosseous and tendon-to-tendon combination technique was used. Vourazeris et al used the Equinox Shoulder System (Exactech, Gainesville, FL, USA).¹⁶ Although subscapularis repair technique was not specified in this study, the primary surgeon was noted to have shifted to leaving the subscapularis as a tenotomy over time in his practice.

Strength outcomes

Postoperative strength outcomes were reported in both studies. de Boer et al Measured abduction and internal rotation strength (in kg) using an electric spring balance with patients standing.⁷ Abduction strength was measured with the arm in 90° of abduction. Abduction strength was not measured in 5 patients (4 no repair, 1 repair) unable to reach 90° of abduction. Internal rotation strength was measured in 0° of abduction in the shoulder and 90° of flexion in the elbow. Abduction strength ($P = .39$) and internal rotation strength ($P = .09$) were not significantly different among the present, absent, and no repair groups.

Vourazeris et al measured external rotation strength (in lbs) using a handheld dynamometer (TBS 2000 Functional Testing Systems Software; Quest Medical Group, West Jordan, UT, USA) with no shoulder abduction.¹⁶ No difference was observed between repair and nonrepair groups ($P = .463$).

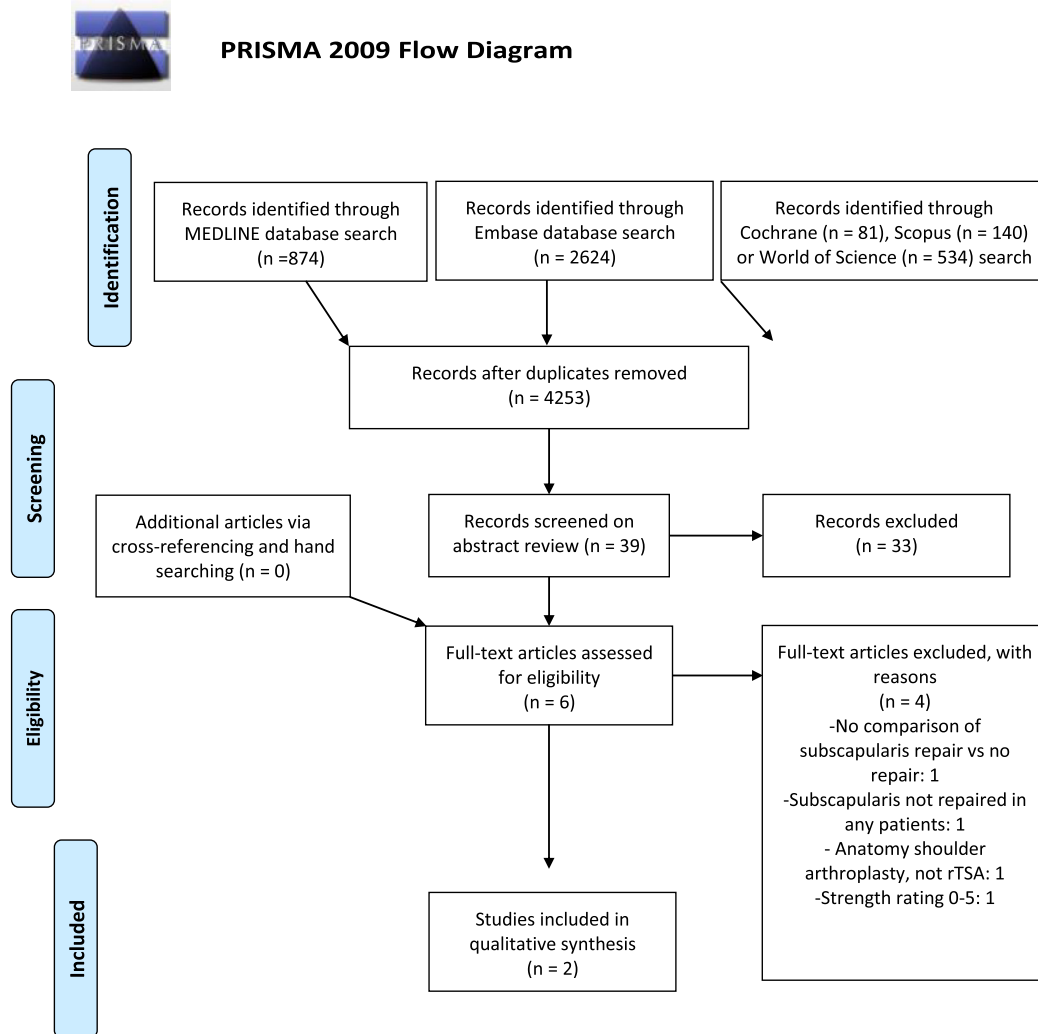


Figure 1 PRISMA flow diagram.

Table 1
Patient demographics.

Study	Study population (N)	Average patient age	Average follow-up time
de Boer et al, 2016 ⁷	25 repair (10 present, 15 absent) 40 no repair	Total: 73.8 yr Present: 74.2 yr Absent: 71.9 yr No repair: 74.4 yr P = .55	Total: 36 mo Present: 34 mo Absent: 27 mo No repair: 40 mo P = .10
Vourazeris et al, 2017 ¹⁶	86 repair 116 no repair	Repair: 71.6 yr No Repair: 71.1 yr P = .46	Repair: 3.3 yr No Repair: 3.1 yr P = .20

Discussion

In the studies that met inclusion criteria, no differences were found in internal rotation, external rotation, and abduction strength outcomes when comparing rTSA with and without subscapularis repair.^{7,16} In both studies, the decision whether to repair the subscapularis was made intraoperatively by the primary surgeon, based on compliance of the tendon and ability to reach the

reattachment site without significant tension. Notably, de Boer et al conducted an ultrasound examination for all patients in whom the subscapularis was reattached, at mean follow-up of 30 months, to check the integrity of the repaired tendon.⁷ These tendons had been repaired using nonabsorbable TiCron sutures (Medline Inc., Mundelein, IL, USA) with a transosseous and tendon-to-tendon combination technique. Only 40% of repaired tendons were intact, with no significant differences in follow-up time between patients

with and without subscapularis tendon ($P = .46$).⁷ Vourazeris et al did not describe the technique chosen for subscapularis repair, and it was noted that as the primary surgeon gained experience with rTSA using a lateralized design, he routinely left the subscapularis as tenotomy without repair.¹⁶

Vourezaris et al had zero dislocations in the subscapularis repair group, and three in the no repair group, although these differences were not significant.¹⁶ de Boer et al had no instances of shoulder instability in either group.⁷ Available literature is divided based on risk of dislocation after subscapularis repair, with some studies finding no relation between repair and dislocation,^{6,17} while other studies describe a significantly increased risk of dislocation when the subscapularis is irreparable.^{1,9,14} Further studies in this area are needed, given the risk of required repeat surgery to address dislocation after rTSA.

In this systematic review focused on strength outcomes, it was found that repair of the subscapularis has no clinical advantages with respect to postoperative strength. Only two studies in this systematic review met our inclusion criteria, and more research is needed before definitive conclusions regarding strength outcomes of subscapularis repair in rTSA can be drawn. In one included study, there was low survivability of repaired tendons at follow-up ultrasound examination,⁷ and in both studies, the decision to repair was guided by individual surgeon preference. Randomized prospective studies, with defined tendon parameters indicating repair, assessing subscapularis repair techniques and evaluating tendon repair survival will enable more definitive conclusions to be drawn regarding whether or not subscapularis repair does indeed affect strength outcomes.

Limitations

There are limitations to this study inherent in all systematic reviews. First, relevant articles may not have been identified with our search criteria, despite taking multiple steps to limit this possibility. Second, there was heterogeneity in measuring techniques and reporting of objective strength outcomes after the surgical procedure, which did not allow for true cross-comparison between the included studies. The generalizability of the findings in this systematic review and descriptive synthesis are limited by heterogeneity of outcome measurements and rTSA surgical techniques.

Conclusion

In this meta-analysis and descriptive synthesis, no differences in strength outcomes were found when comparing rTSA with and without subscapularis repair. As a result, the individual clinician may choose whether or not to repair the subscapularis based on preference and other considerations, with the knowledge that strength outcomes are not affected.

Disclaimers:

Funding: No funding was disclosed by the authors.
Conflicts of interest: The authors, their immediate families, and any research foundation with which they are affiliated have not received any financial payments or other benefits from any commercial entity related to the subject of this article.

Supplementary Data

Supplementary data to this article can be found online at <https://doi.org/10.1016/j.xrtr.2021.11.004>.

References

- Boileau P, Watkinson DJ, Hatzidakis AM, Balg F. Grammont reverse prosthesis: design, rationale, and biomechanics. *J Shoulder Elbow Surg* 2005;14:147s–61s. <https://doi.org/10.1016/j.jse.2004.10.006>.
- Bramer WM, Giustini D, de Jonge GB, Holland L, Bekhuis T. De-duplication of database search results for systematic reviews in EndNote. *J Med Libr Assoc* 2016;104:240–3. <https://doi.org/10.3163/1536-5050.104.3.014>.
- Buckley T, Miller R, Nicandri G, Lewis R, Voloshin I. Analysis of subscapularis integrity and function after lesser tuberosity osteotomy versus subscapularis tenotomy in total shoulder arthroplasty using ultrasound and validated clinical outcome measures. *J Shoulder Elbow Surg* 2014;23:1309–17. <https://doi.org/10.1016/j.jse.2013.12.009>.
- Budge MD, Nolan EM, Wiater JM. Lesser tuberosity osteotomy versus subscapularis tenotomy: technique and rationale. *Oper Tech Orthop* 2011;21:39–43. <https://doi.org/10.1053/j.oto.2010.09.010>.
- Bullock GS, Garrigues GE, Ledbetter L, Kennedy J. A systematic review of proposed rehabilitation guidelines following anatomic and reverse shoulder arthroplasty. *J Orthop Sports Phys Ther* 2019;49:337–46. <https://doi.org/10.2519/jospt.2019.8616>.
- Clark JC, Ritchie J, Song FS, Kissenberth MJ, Tolan SJ, Hart ND, et al. Complication rates, dislocation, pain, and postoperative range of motion after reverse shoulder arthroplasty in patients with and without repair of the subscapularis. *J Shoulder Elbow Surg* 2012;21:36–41. <https://doi.org/10.1016/j.jse.2011.04.009>.
- de Boer FA, van Kampen PM, Huijsmans PE. The influence of subscapularis tendon reattachment on range of motion in reversed shoulder arthroplasty: a clinical study. *Musculoskelet Surg* 2016;100:121–6. <https://doi.org/10.1007/s12306-016-0401-8>.
- Edwards PK, Ebert JR, Morrow MM, Goodwin BM, Ackland T, Wang A. Accelerometry evaluation of shoulder movement and its association with patient-reported and clinical outcomes following reverse total shoulder arthroplasty. *J Shoulder Elbow Surg* 2020;29:2308–18. <https://doi.org/10.1016/j.jse.2020.03.030>.
- Edwards TB, Williams MD, Labriola JE, Elkousy HA, Gartsman GM, O'Connor DP. Subscapularis insufficiency and the risk of shoulder dislocation after reverse shoulder arthroplasty. *J Shoulder Elbow Surg* 2009;18:892–6. <https://doi.org/10.1016/j.jse.2008.12.013>.
- Erşen A, Birişik F, Bayram S, Şahinkaya T, Demirel M, Atalar A, et al. Isokinetic evaluation of shoulder strength and endurance after reverse shoulder arthroplasty: a comparative study. *Acta Orthop Traumatol Turc* 2019;53:452–6. <https://doi.org/10.1016/j.aott.2019.08.001>.
- Franceschetti E, de Sanctis EG, Ranieri R, Palumbo A, Paciotti M, Franceschi F. The role of the subscapularis tendon in a lateralized reverse total shoulder arthroplasty: repair versus nonrepair. *Int Orthop* 2019;43:2579–86. <https://doi.org/10.1007/s00264-018-4275-2>.
- Malahias MA, Gerogiannis D, Chronopoulos E, Kaseta MK, Brilakis E, Antonogiannakis E. Is subscapularis repair associated with better outcome compared to non-repair in reverse total shoulder arthroplasty? A systematic review of comparative trials. *Orthop Rev (Pavia)* 2019;11:7948. <https://doi.org/10.4081/or.2019.7948>.
- Oh JH, Sharma N, Rhee SM, Park JH. Do individualized humeral retroversion and subscapularis repair affect the clinical outcomes of reverse total shoulder arthroplasty? *J Shoulder Elbow Surg* 2020;29:821–9. <https://doi.org/10.1016/j.jse.2019.08.016>.
- Oh JH, Shin SJ, McGarry MH, Scott JH, Heckmann N, Lee TQ. Biomechanical effects of humeral neck-shaft angle and subscapularis integrity in reverse total shoulder arthroplasty. *J Shoulder Elbow Surg* 2014;23:1091–8. <https://doi.org/10.1016/j.jse.2013.11.003>.
- Shafritz AB, Flieger S. Reverse total shoulder arthroplasty: early results of forty-one cases and a review of the literature. *Hand Clin* 2012;28:469–79. <https://doi.org/10.1016/j.hcl.2012.08.009>.
- Vourazeris JD, Wright TW, Struk AM, King JJ, Farmer KW. Primary reverse total shoulder arthroplasty outcomes in patients with subscapularis repair versus tenotomy. *J Shoulder Elbow Surg* 2017;26:450–7. <https://doi.org/10.1016/j.jse.2016.09.017>.
- Wall B, Nové-Josserand L, O'Connor DP, Edwards TB, Walch G. Reverse total shoulder arthroplasty: a review of results according to etiology. *J Bone Joint Surg Am* 2007;89:1476–85. <https://doi.org/10.2106/JBJS.F.00666>.