



A Prospective Trial to Measure Contralateral Breast Dose during Breast Radiotherapy Using Cherenkov Imaging and *in vivo* Dosimetry

REDISCOVERING RADIATION MEDICINE AND EXPLORING NEW INDICATIONS

A.L. MATOUS,¹ M. CLARK,^{2, 3} R. VASYLTSIV,³ S.M. MCVORRAN,^{1, 4} A.K. FARISS,¹ P. BRUZA,³ D.J. GLADSTONE,^{1,3} L.A. JARVIS¹

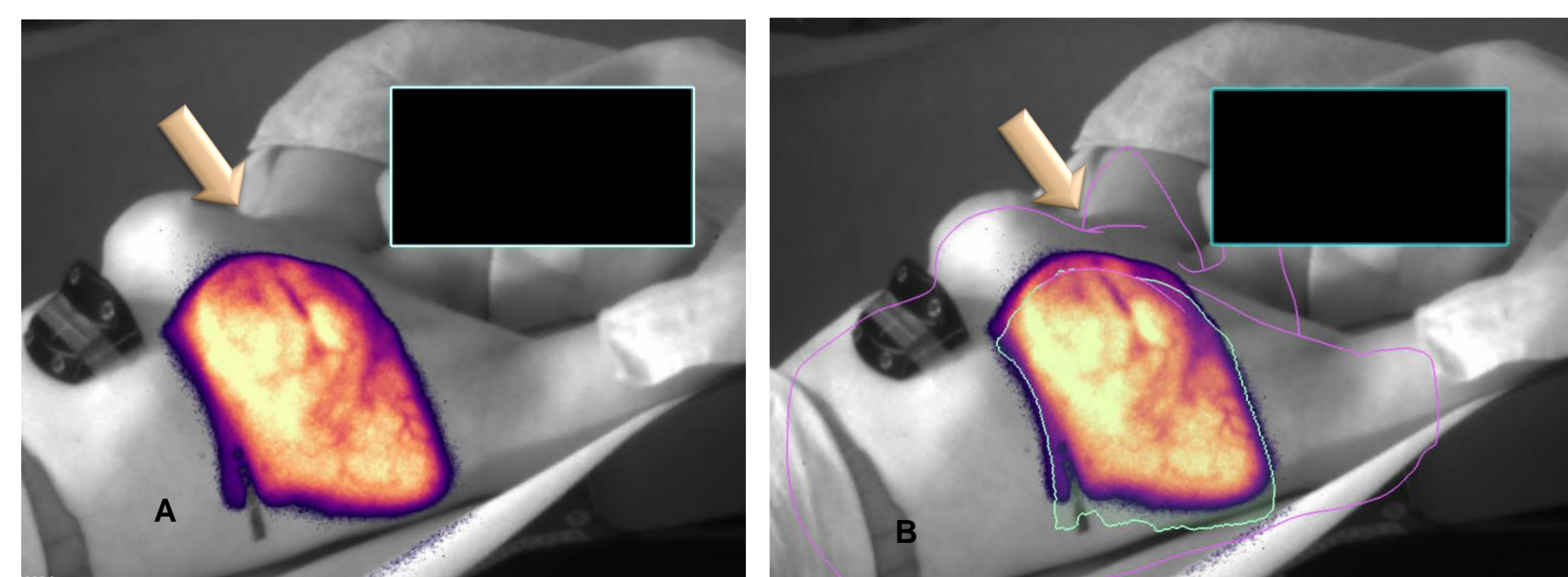
¹ Department of Radiation Oncology & Applied Sciences, Dartmouth Cancer Center, Lebanon, NH; ² Department of Radiation Oncology, Stanford Medicine, Palo Alto, CA; ³ Thayer School of Engineering at Dartmouth College, Hanover, NH; ⁴ Division of Radiation Oncology, Fred Hutch Cancer Center, Seattle, WA

PURPOSE / OBJECTIVES

- Minimizing radiation dose to the contralateral breast is a critical treatment goal in breast radiotherapy, as extraneous dose can contribute to subsequent malignancies.
- Prior studies assessing contralateral breast dose (CBD) lack on-patient dosimetry data, and treatment techniques have evolved since this work was completed.
- The baseline incidence, causes, and clinical implications of CBD in routine clinical practice therefore remain unclear.
- We hypothesize that Cherenkov imaging**, which enables direct visualization of radiotherapy beams on patients and detects dose to off-target tissues, can be used to identify the incidence and root causes of CBD in routine clinical practice.

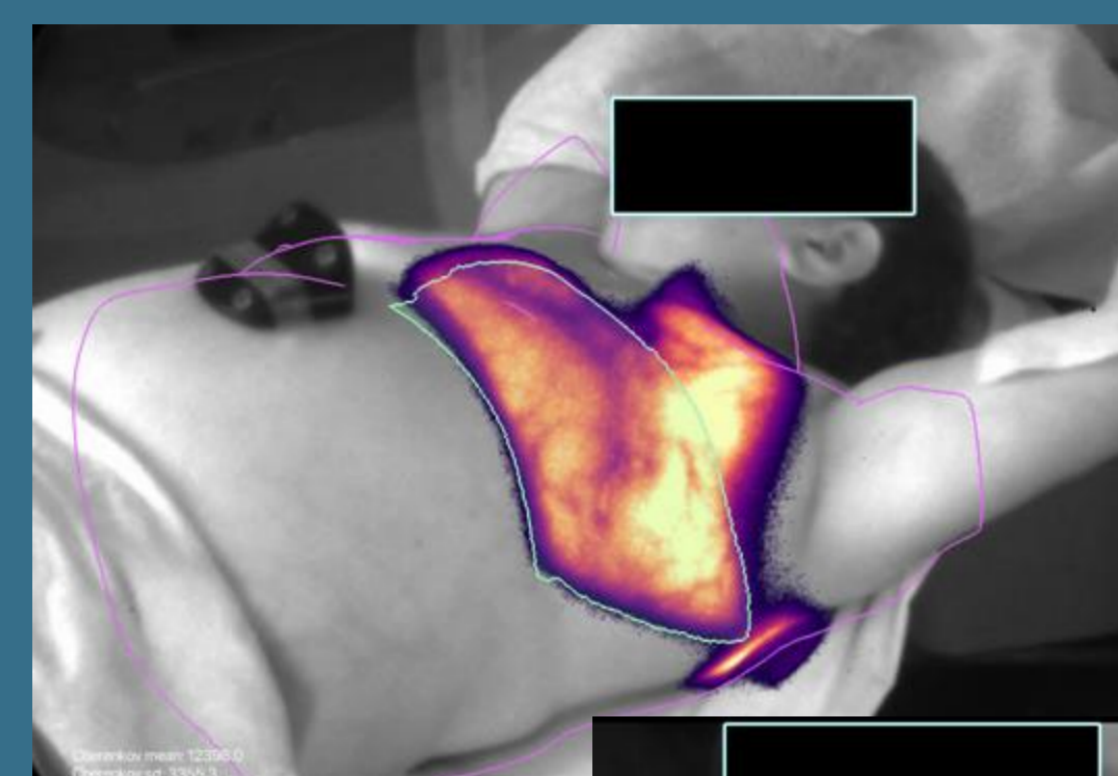
MATERIAL & METHODS

- Cherenkov images were prospectively reviewed for 167 unique patients receiving supine breast radiotherapy across 2,269 fractions at 2 institutions.
- When CBD was identified on imaging, 1) a root cause analysis was conducted to determine the cause of CBD and 2) patients were consented to an IRB-approved trial for dose measurement at the site of CBD.
- Cherenkov images with CBD were compared to the plan overlay, and cause of CBD was determined to be 1) planned, 2) unplanned, or 3) a combination of planned and unplanned.

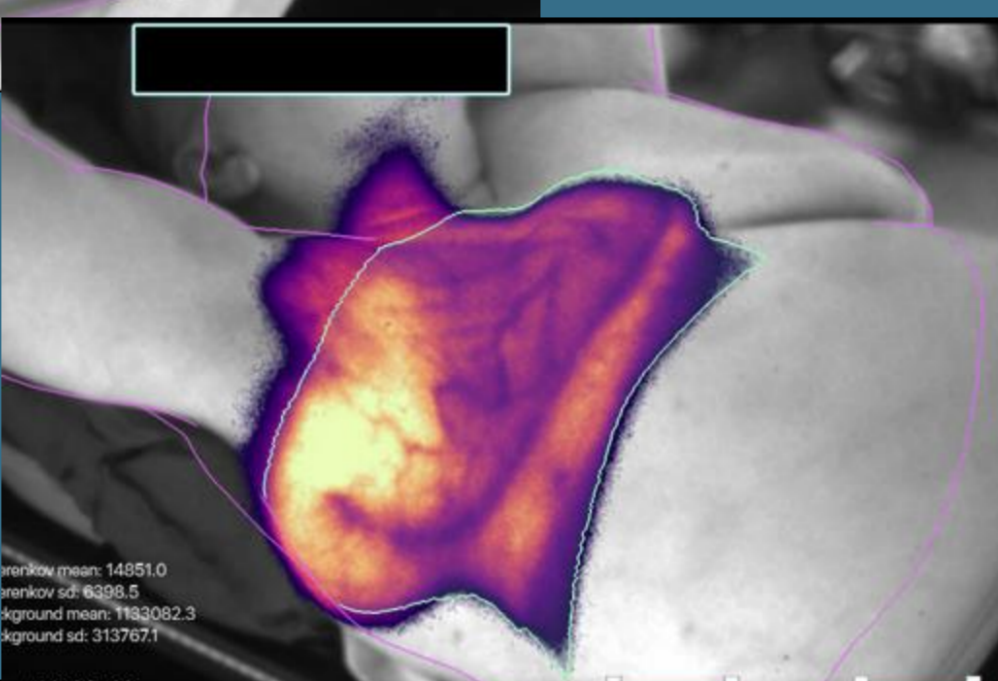


A: Cumulative Cherenkov image showing CBD. B: Discordance between cumulative image and overlay of predicted Cherenkov distribution (green outline) indicating CBD is unplanned.

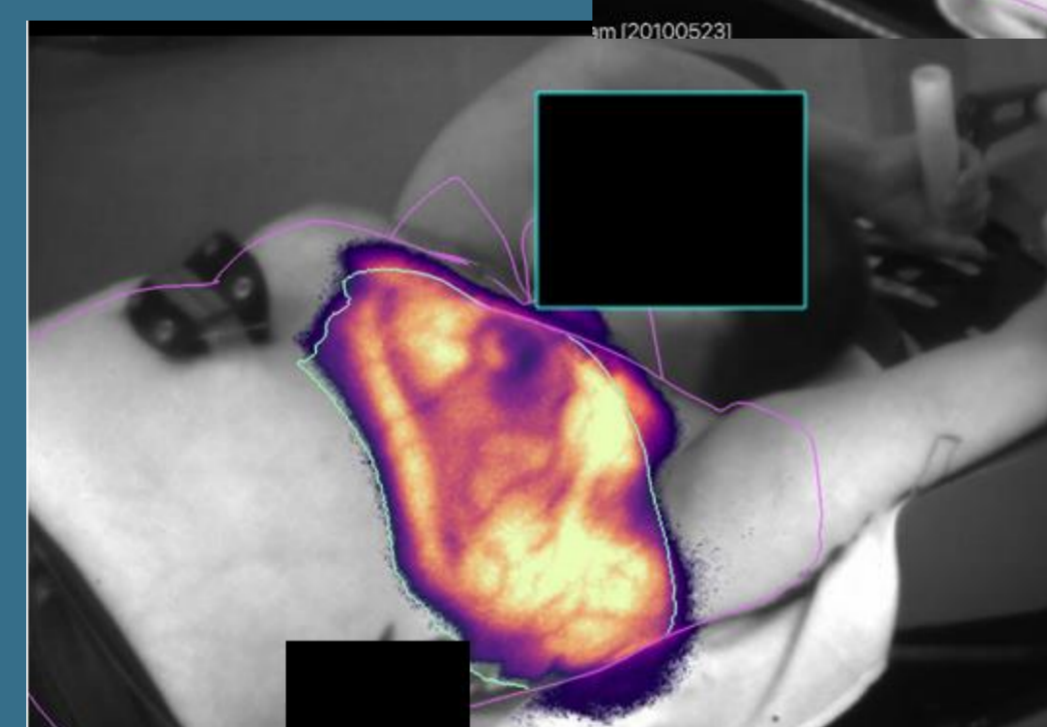
Treatment deliveries for 43% of patients showed CBD on Cherenkov imaging!



14% of CBD instances were unplanned



57% of CBD instances were planned



29% of CBD instances showed planned CBD with additional unplanned CBD

Cause of CBD	
Planned / predicted in overlay	57% (41 / 72) of CBD instances
Unplanned / not predicted in overlay	14% (10 / 72) of CBD instances
Combination of planned and unplanned causes	29% (21 / 72) of CBD instances

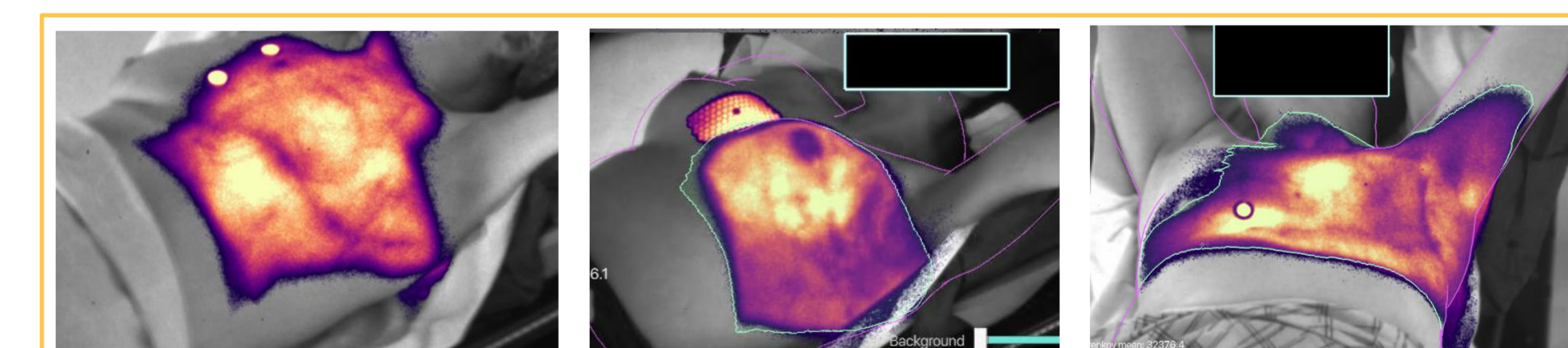
Table 2: Right column gives the percentage of CBD instances that were planned, unplanned, or planned with additional unplanned contribution.

RESULTS

CBD was identified on treatment deliveries for **43%** (72 / 167) of patients

Treatment Technique	
Tangents	17% (12 / 72) of CBD instances
Wide tangents	26% (19 / 72) of CBD instances
Tangents with medial electrons	3% (2 / 72) of CBD instances
Non-tangent 3D	1% (1 / 72) of CBD instances
VMAT Whole breast or chest wall + regional nodal irradiation	7% (5 / 72) of CBD instances
VMAT Accelerated partial breast irradiation (aPBI)	42% (30 / 72) of CBD instances
Photon boost	4% (3 / 72) CBD instances

Table 1: Radiotherapy techniques with visualized CBD on Cherenkov imaging. Right column gives the number of cases - as a percent - of a given technique with visualized CBD out of the total number of cases with CBD.



41 patients have undergone CBD measurement with *in vivo* dosimetry

SUMMARY / CONCLUSION

- Cherenkov imaging can help identify CBD during breast radiotherapy treatments, including cases where CBD is unexpected and unplanned.
- Cherenkov imaging can guide *in vivo* dosimetry, making dose measurement at the exact site of CBD feasible.