



# Cherenkov Imaging Combined with Scintillation Dosimetry Provides Real-Time Positional and Dose Monitoring for Patients with Cardiac Implanted Electronic Devices

Dartmouth Cancer Center



A. MATOUS,<sup>1</sup> S. DECKER,<sup>2</sup> R. ZHANG,<sup>3</sup> D. GLADSTONE,<sup>4</sup> E. GROVE,<sup>1</sup> B. WILLIAMS,<sup>1</sup> M. JERMYN,<sup>5</sup> S. MCVORRAN,<sup>1</sup> L. JARVIS.<sup>1</sup>

<sup>1</sup> Dartmouth Health; <sup>2</sup> UC San Diego Health; <sup>3</sup> New York Medical College; <sup>4</sup> Thayer School of Engineering at Dartmouth; <sup>5</sup> DoseOptics LLC

## PURPOSE / OBJECTIVES

- Cardiac implanted electronic devices (CIED) require dose monitoring during each fraction of radiotherapy, but current methodologies to do so are time consuming and often have delayed read-out times.
- Cherenkov imaging combined with scintillation dosimetry may be an efficient, accurate, real-time on-patient verification system for monitoring treatment delivery to patients with CIEDs.

## MATERIALS & METHODS

- A Cherenkov imaging system with 2 time-gated iCMOS cameras was used to collect video images of an anthropomorphic phantom and patients undergoing radiation treatment near chest wall CIEDs.
- Scintillator discs and optically-stimulated luminescence dosimeters (OSLDs) were used for dose measurement at points of interest.
- Accuracy of spatial delivery was assessed by overlaying predicted surface dose outlines derived from the treatment planning system (TPS) with Cherenkov images.
- Dose measurements from OSLDs were compared with measurements from scintillator discs.

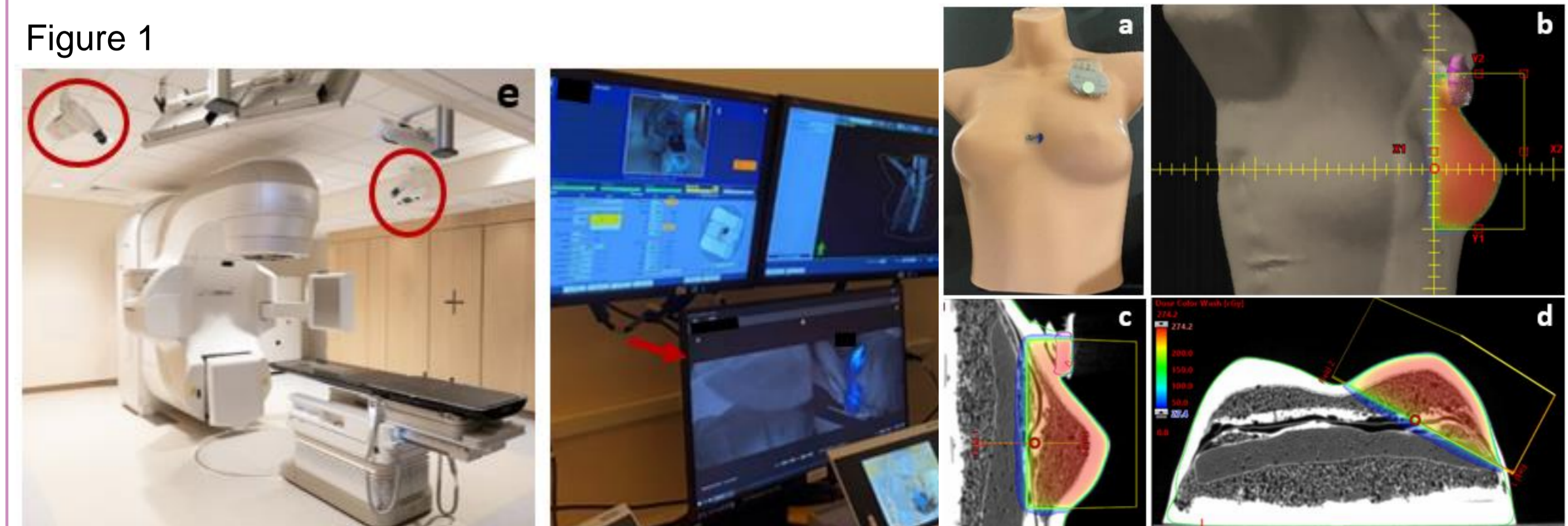
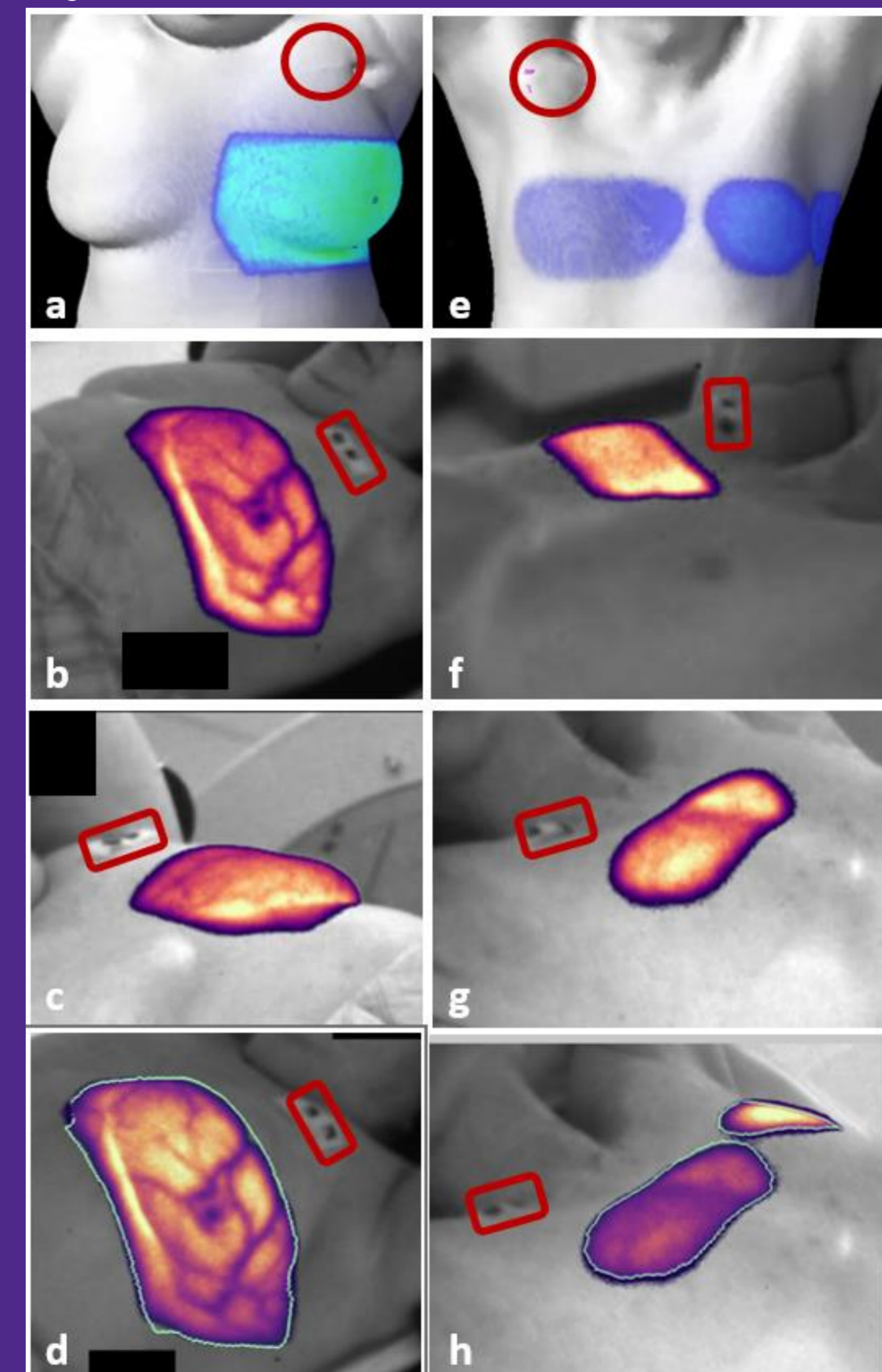


Figure 5



## CONCLUSION

Cherenkov imaging combined with scintillation dosimetry presents a methodology for CIED monitoring. Benefits include instantaneous detection of deviations, easy integration into clinical workflow, and no additional radiation exposure to the patient.

## RESULTS

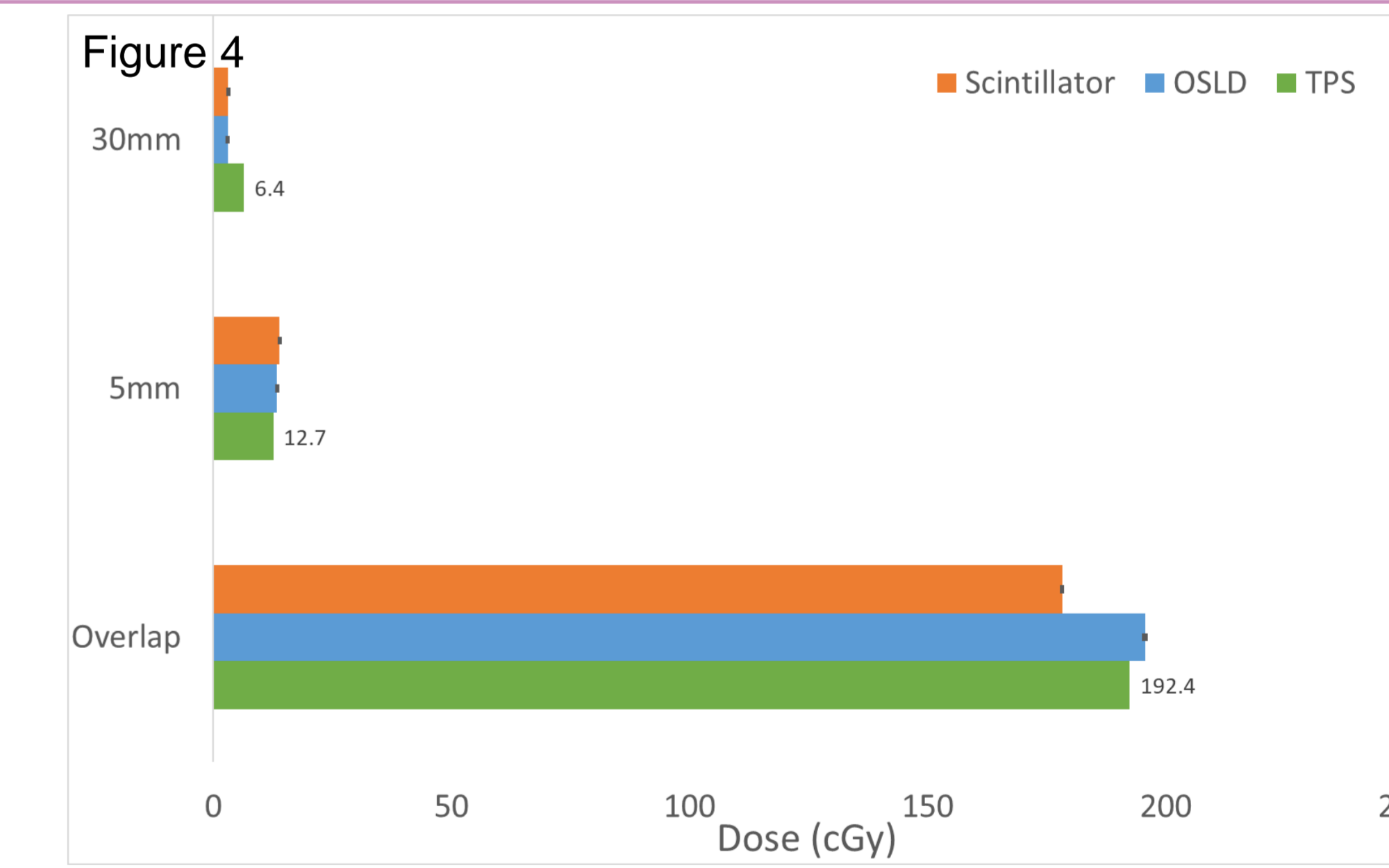
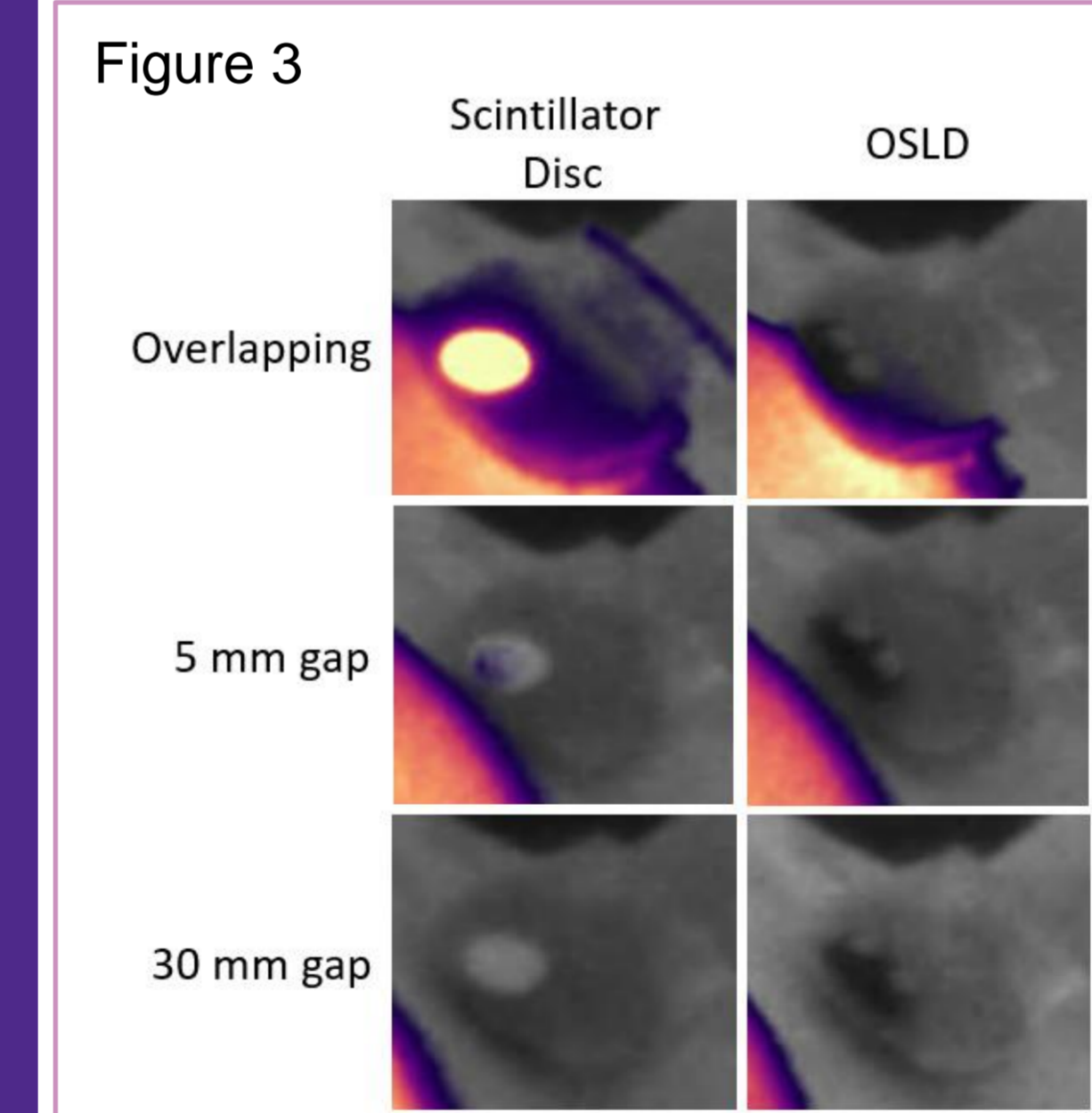



Figure 1: Clinical Cherenkov imaging setup and radiotherapy plan for phantom treatments. Figure 2: Cherenkov images of breast tangent fields delivered to phantom with pacemaker on left chest wall. Figure 3: Treatment deliveries in relation to CIED and dosimeter placements. Figure 4: OSLD and scintillator disc measurements compared to estimated TPS dose. Figure 5: Clinical Cherenkov imaging of 2 patients with CIEDs.