

2018 AAST-OIS - LIVER

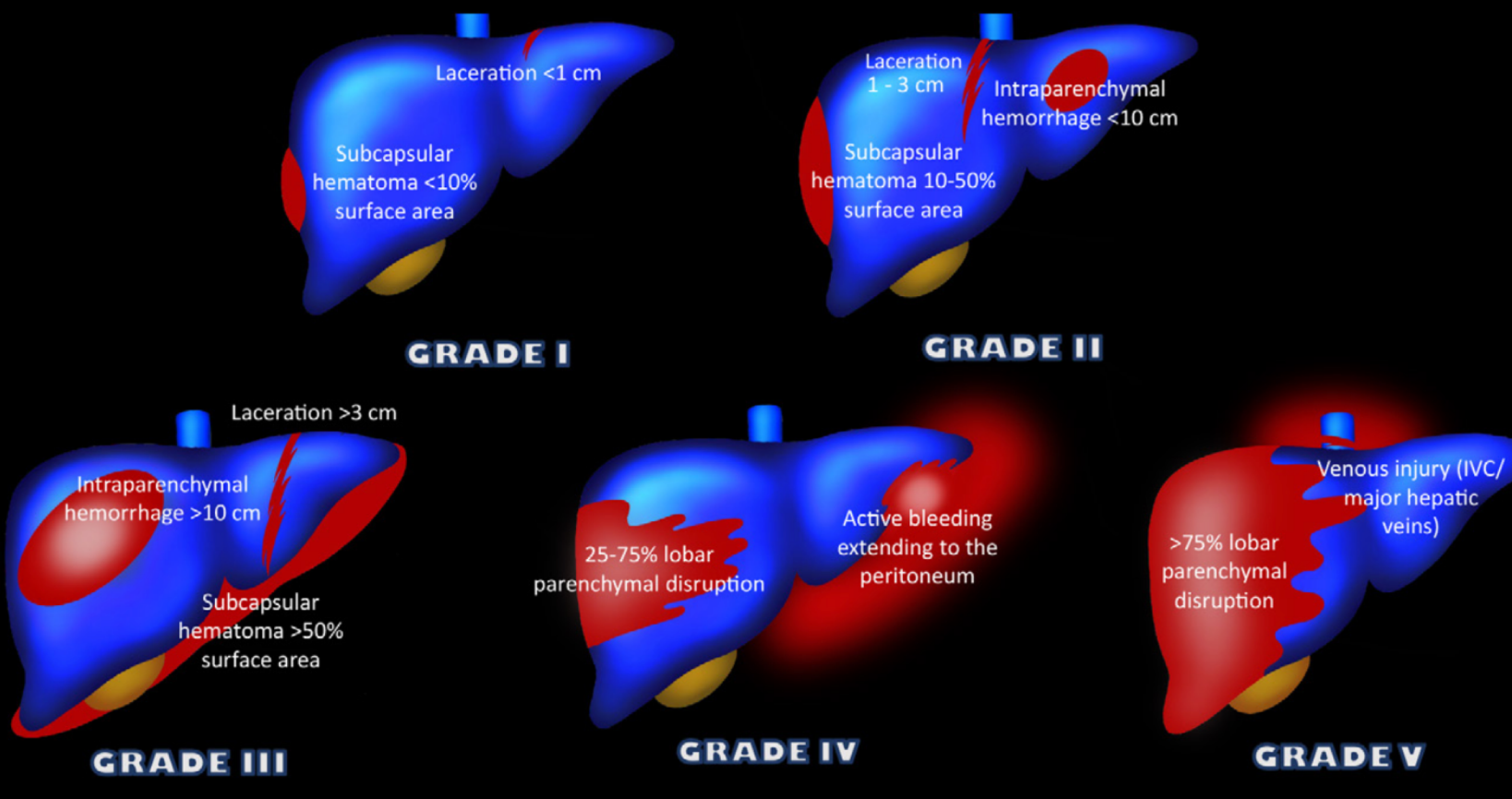


Figure 10. Schematic representation shows the revised 2018 AAST-OIS for liver injuries. /VC = inferior vena cava.

Liver Injury Scale (2018 revision)

AAST Grade	AIS Severity	Imaging Criteria (CT Findings)	Operative Criteria	Pathologic Criteria
I	2	Subcapsular hematoma <10% surface area	Subcapsular hematoma <10% surface area	Subcapsular hematoma <10% surface area
		Parenchymal laceration <1 cm depth	Parenchymal laceration <1 cm depth Capsular tear	Parenchymal laceration <1 cm depth Capsular tear
II	2	Subcapsular hematoma 10-50% surface area; intraparenchymal hematoma <10 cm in diameter	Subcapsular hematoma 10-50% surface area; intraparenchymal hematoma <10 cm in diameter	Subcapsular hematoma 10-50% surface area; intraparenchymal hematoma <10 cm in diameter
		Laceration 1-3 cm in depth and ≤10 cm length	Laceration 1-3 cm in depth and ≤10 cm length	Laceration 1-3 cm in depth and ≤10 cm length
III	3	Subcapsular hematoma >50% surface area; ruptured subcapsular or parenchymal hematoma	Subcapsular hematoma >50% surface area or expanding; ruptured subcapsular or parenchymal hematoma	Subcapsular hematoma >50% surface area; ruptured subcapsular or intraparenchymal hematoma
		Intraparenchymal laceration >10 cm	Intraparenchymal hematoma >10 cm	Intraparenchymal hematoma >10 cm
		Laceration >3 cm depth	Laceration >3 cm depth	Laceration >3 cm depth
IV	4	Any injury in the presence of a liver vascular injury or active bleeding contained within liver parenchyma		
		Parenchymal disruption involving 25-75% of a hepatic lobe	Parenchymal disruption involving 25-75% of a hepatic lobe	Parenchymal disruption involving 25-75% of a hepatic lobe
V	5	Active bleeding extending beyond the liver parenchyma into the peritoneum		
		Parenchymal disruption >75% of hepatic lobe	Parenchymal disruption >75% of hepatic lobe	Parenchymal disruption >75% of hepatic lobe
		Juxtahepatic venous injury to include retrohepatic vena cava and central major hepatic veins	Juxtahepatic venous injury to include retrohepatic vena cava and central major hepatic veins	Juxtahepatic venous injury to include retrohepatic vena cava and central major hepatic veins

Vascular injury is defined as a pseudoaneurysm or arteriovenous fistula and appears as a focal collection of vascular contrast that decreases in attenuation with delayed imaging. Active bleeding from a vascular injury presents as vascular contrast, focal or diffuse, that increases in size or attenuation in delayed phase. Vascular thrombosis can lead to organ infarction.