Check for updates

Bone Tumor Risk Stratification and Management System: A Consensus Guideline from the ACR Bone Reporting and Data System Committee

CME

Jamie T. Caracciolo, MD, MBA[a], Sayed Ali, MD[b], Connie Y. Chang, MD[c], Andrew J. Degnan, MD[d], Donald J. Flemming, MD[e], Eric R. Henderson, MD[f], Mark J. Kransdorf, MD[g], George Douglas Letson, MD[h], John E. Madewell, MD[i], Mark D. Murphey, MD[j]

Credits awarded for this enduring activity are designated "CME" by the American Board of Radiology (ABR) and qualify toward fulfilling requirements for Maintenance of Certification (MOC) Part II: Lifelong Learning and Self-assessment. To access the CME activity visit https://cortex.acr.org/Presenters/CaseScript/CaseView?Info=HyIj2oYl2Wzw%2faePglhWH3iTGH1Ley%2f1PXe1wlOLCs0%253d. CME credit for this article expires October 2, 2026. All CME articles can be found on JACR.org by navigating to CME on the dropdown menu.

Abstract

The assessment and subsequent management of a potentially neoplastic bone lesion seen at diagnostic radiography is often complicated by diagnostic uncertainty and inconsistent management recommendations. Appropriate clinical management should be directed by risk of malignancy. Herein, the ACR-sponsored Bone Reporting and Data System (Bone-RADS) Committee, consisting of academic leaders in the fields of musculoskeletal oncology imaging and orthopedic oncology, presents the novel Bone-RADS scoring system to aid in risk assignment and provide risk-aligned management suggestions. When viewed in the proper clinical context, a newly identified bone lesion can be risk stratified as having very low, low, intermediate, or high risk of malignancy. Radiographic features predictive of risk are reviewed include margination, pattern of periosteal reaction, depth of endosteal erosion, pathological fracture, and extra-osseous soft tissue mass. Other radiographic features predictive of histopathology are also briefly discussed. To apply the Bone-RADS scoring system to a potentially neoplastic bone lesion, radiographic features predictive of risk are each given a point value. Point values are summed to yield a point total, which can be translated to a Bone-RADS score (1-4) with corresponding risk assignment (very low, low, intermediate, high). For each score, evidence-based and best practice consensus management suggestions are outlined. Examples of each Bone-RADS scores are presented, and a standardized diagnostic radiography report template is provided.

Key Words: Bone tumor, lytic lesion, management of bone lesions, risk stratification, scoring system

J Am Coll Radiol 2023;20:1044-1058. © 2023 Published by Elsevier Inc. on behalf of American College of Radiology

[a]Senior Member and Professor, Diagnostic Imaging, Section Head, Musculoskeletal Imaging, Moffitt Cancer Center, Tampa, Florida.
[b]Professor of Radiology, Section Chief of Musculoskeletal Radiology, Temple University Hospital, Philadelphia, Pennsylvania.
[c]Associate Professor of Radiology, Massachusetts General Hospital and Harvard Medical School, Boston, Massachusetts.
[d]Radiologist, Section Chief of Pediatric Radiology, Abington Hospital—Jefferson Health, UPMC Children's Hospital of Pittsburgh, Abington, Pennsylvania.
[e]Professor of Radiology and Orthopaedics and Diagnostic Radiology Residency Program Director, Department of Radiology, Penn State Milton S. Hershey Medical Center, Hershey, Pennsylvania.
[f]Associate Professor of Orthopaedic Surgery Adjunct Associate Professor of Engineering, Norris Cotton Cancer Center, Dartmouth-Hitchcock Health, Lebanon, New Hampshire.
[g]Professor, Mayo Clinic, Phoenix, Arizona.
[h]Physician in Chief of the Moffitt Medical Group, Moffitt Cancer Center, Tampa, Florida.
[i]Professor and Chair ad interim Musculoskeletal Imaging, MD Anderson Cancer Center, Houston, Texas.
[j]Physician-in-Chief, American Institute for Radiologic Pathology, Silver Spring, Maryland.
Corresponding author and reprints: Jamie T. Caracciolo, MD, MBA, Moffitt Cancer Center, 12902 Magnolia Drive, Tampa FL 33612; e-mail: Jamie.caracciolo@moffitt.org.

Dr Henderson reports paid educational consultant for Stryker Orthopaedics funded by National Institutes of Health, Hitchcock Foundation. Dr Letson reports consultant for Stryker Orthopedics. The other authors state that they have no conflict of interest related to the material discussed in this article. Dr Degnan is on a partnership track; Dr Henderson and Dr Letson are partners; and the other authors are non-partner/non-partnership track/employees.

© 2023 Published by Elsevier Inc. on behalf of American College of Radiology

1546-1440/23/$36.00 ■ https://doi.org/10.1016/j.jacr.2023.07.017

INTRODUCTION

With increasing utilization of diagnostic imaging, most health care professionals will face the challenging assessment and management of a newly identified potentially neoplastic bone lesion. The human skeleton plays essential roles in body form and function including soft tissue support and movement, protection of vital internal organs, hematopoiesis, and mineral regulation. Any bone may be affected by a wide range of primary and secondary bone tumors, infection, trauma, developmental, and metabolic disorders. Among the list of pathologies, potentially neoplastic bone lesions are often difficult to evaluate by imaging alone, comprising a broad spectrum of morbidity including both benign and malignant neoplasms. For clinicians and radiologists alike, the workup and management of a newly diagnosed bone lesion can be a source of uncertainty and may result in variable management recommendations. In an effort to standardize the radiographic assessment and reporting of potentially neoplastic bone lesions, our team developed the Bone Reporting and Data System (Bone-RADS) scoring system to radiographically stratify bone lesions based upon the likelihood of malignancy and provide consensus management recommendations. The Bone-RADS scoring system intends to (1) provide the interpreting radiologist with a systematic framework to evaluate a bone lesion and (2) facilitate unambiguous communication of risk of malignancy and suggested management recommendations to referring health care providers.

PROJECT RATIONALE AND CONSENSUS PROCESS

The skeleton may be affected by numerous benign and malignant primary neoplasms, metastatic cancers, and nonneoplastic entities that can be developmental, metabolic, or traumatic. The resulting breadth of diagnostic considerations, some with overlapping radiographic features, can contribute to confusion and uncertainty. A thorough and thoughtful evaluation of a potentially neoplastic bone lesion includes orthogonal radiographs to assess:

- Size, location, radiodensity, and number of lesion(s)
- Features predictive of risk of malignancy
- Features predictive of histopathology
- Consideration of patient demographics and past medical history

Identifying a particular bone lesion's likelihood of malignancy is critical to inform risk-aligned patient management recommendations. Risk stratification relies on several radiographic findings accepted as correlates of biologic activity that form the basis of the Bone-RADS scoring system. When viewed in the appropriate clinical context, the risk of malignancy can be stratified as very low, low, intermediate, or high, which in turn helps direct appropriate patient care.

In this context, the ACR assembled the Bone-RADS Committee to:

- Develop a standardized scoring system and define the lexicon used in the evaluation of a potentially neoplastic bone lesion incorporating pertinent radiographic features predictive of risk of malignancy;
- Provide consensus and evidence-based management suggestions for each score;
- Construct a standard imaging reporting template for skeletal radiographs.

The Bone-RADS Committee is composed of a diverse group of experts from leading academic institutions and cancer centers specializing in diagnosis, imaging, and treatment of adult and pediatric musculoskeletal tumors. The Bone-RADS scoring system, sponsored by the ACR and co-endorsed by the Musculoskeletal Tumor Society, was developed in consensus via telephone and teleconference calls, personal communications, and email correspondence. Management suggestions were based on existing literature, evidence-based best practice, and expert opinions of the committee members. A diagnostic radiography report template for potentially neoplastic bone lesions that includes the Bone-RADS (Bone) scoring system is included as an e-only appendix.

BONE-RADS SCORING SYSTEM

Evaluation of a potentially neoplastic bone lesion relies on close inspection of several key radiographic features that help predict *biologic activity* and *risk of malignancy*. Other radiographic features contribute to differential diagnostic considerations, tumor cell lineage, and histopathology. Evidence-based radiographic features predictive of risk are assigned a point value, which are summed to yield a point total (Table 1). Individual point values for each radiographic feature were established in consensus by expert opinions of the committee and would benefit from future validation. The point total is converted to a Bone-RADS score (1-4) to convey risk and help guide appropriate management (Table 2). The Bone-RADS scoring system includes four levels of risk—very low, low, intermediate, and high—with corresponding scores of 1, 2, 3, and 4 denoting increasing risk of malignancy while providing risk-aligned management recommendations.

RADIOGRAPHIC FEATURES PREDICTIVE OF RISK AND HISTOPATHOLOGY

Key radiographic features including in the Bone-RADS scoring system predictive of *risk of malignancy* include: (1)

Table 1. Point values for radiographic features used to predict risk of malignancy

Margin	Periosteal Reaction	Endosteal Erosion	Pathological Fracture	Extra-Osseous Soft Tissue Mass	History of Primary Cancer
IA = 1	None = 0	Mild = 0	No = 0	No = 0	No = 0
IB = 3	Nonaggressive = 2	Moderate = 1	Yes = 2	Yes = 4	Yes = 2
II = 5	Aggressive = 4	Deep = 2			
IIIA-C = 7					

IA = geographic well-defined lesions with marginal sclerosis; IB = geographic well-defined lesions without marginal sclerosis; II = geographic lesions with ill-defined margins, originally designated IC by Lodwick, found to carry an intermediate risk of malignancy (approximately 50%); IIIA-C = lesions with changing margins (IIIA), nongeographic margins with moth-eaten or permeative osteolysis (IIIB), and radiographically occult lesions with invisible margins (IIIC) identified by other imaging modalities.

margination, or zone of transition; (2) pattern of periosteal reaction; (3) depth of endosteal erosion; (4) presence or absence of pathological fracture; and (5) presence or absence of soft tissue mass. After risk assessment, additional imaging features such as radiodensity, internal matrix, and location can help predict *histopathology*.

Radiographic Features to Predict Risk of Malignancy

Margins. Lesion margination has long been a crucial feature in the radiographic assessment of osteolytic bone lesions. Initial work by Lodwick in the 1960s established an early understanding of lesion margination as a predictor of tumor biology and rate of growth [1]. Madewell et al subsequently formalized Lodwick's original classification system while at the Armed Forces Institute of Pathology (AFIP) [2]. More recently, the modified Lodwick-Madewell grading system was proposed to incorporate additional patterns of disease and more closely match margin grade with risk of malignancy [3].

Lodwick was first to recognize that different patterns of bone destruction seen at bone radiography correlated with patient survival. While studying cases of fibrosarcoma from the Codman Bone Sarcoma Registry at the AFIP, he identified three patterns of osteolysis—geographic, moth-eaten, and permeated—and defined 14 descriptive variables that could be applied to each pattern of bone destruction. He then correlated these patterns with 5-year survival and found that patient survival was greatest among patients with geographic lesions and lowest among patients with permeated lesions. Years later, Lodwick et al proposed a grading system for osteolytic bone lesions as an expression of rate of tumor growth and, by extension, risk of malignancy [4]. Grade assignment was used to suggest which lesions could be safely followed and which should be biopsied. The pattern of osteolysis and tumor margin formed the basis of this original classification system, which defined five grades with increasing rate of growth and risk—geographic and well defined with marginal sclerosis (IA) or without marginal sclerosis (IB), geographic yet ill defined (IC), and nongeographic with moth-eaten (II) or permeative (III) osteolysis. Although several modifications have emerged over time, this original classification system remains widely accepted in the radiographic assessment of osteolytic bone lesions.

During his tenure as chairman at the AFIP, Madewell consolidated Lodwick's grading system and descriptive terminology and incorporated his work into the course curriculum. In the early 1980s, Madewell et al defined two additional patterns of disease—combined or changing margins and invisible margins [2]. Changing margination was applied to lesions with two distinct zones of transition—for example, a lesion with both well-defined and ill-defined borders, as may be seen in the setting of malignant transformation of a pre-existing benign bone lesion. Changing margins suggest an area of increased biologic activity within a bone tumor and the concept follows

Table 2. Point values from Table 1 are summed to yield a point total that corresponds with a Bone-RADS score

Point Total	Bone-RADS Score	Description
NA	0	Incompletely characterized
1-2	1	Very low risk—very likely benign
3-4	2	Low risk—probably benign
5-6	3	Intermediate risk—potentially malignant
7 or greater	4	High risk—highly suspicious for malignancy

Bone-RADS = Bone Reporting and Data System; NA = not applicable.

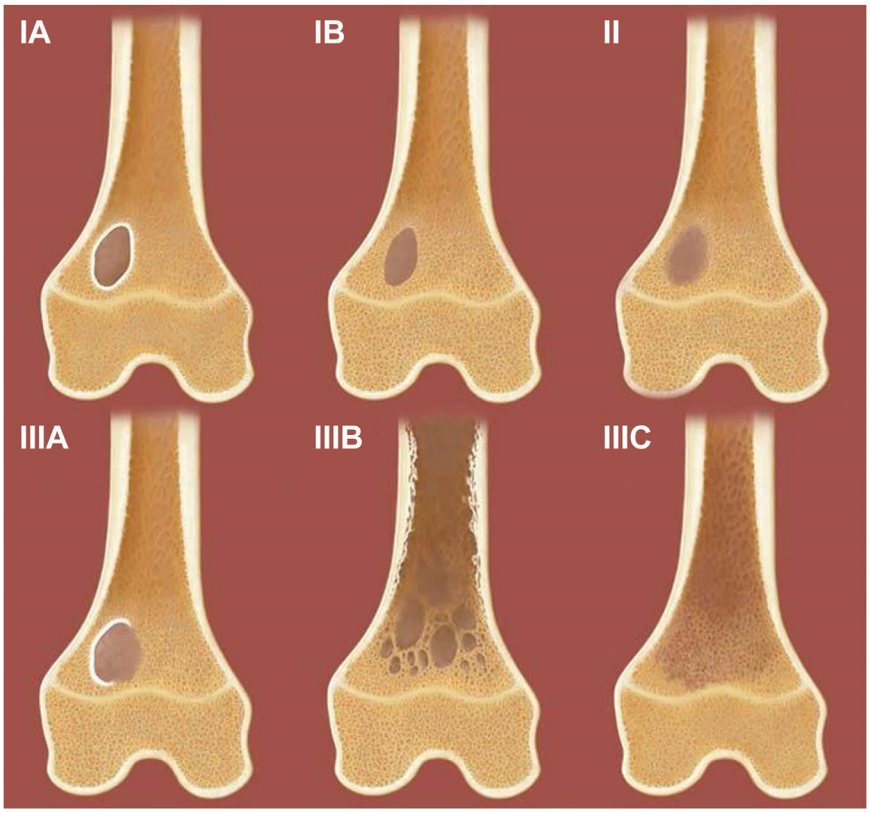

Fig. 1. Bone tumor risk stratification and management system: a consensus guideline from the ACR Bone Reporting and Data System Committee. Illustration of the modified Lodwick-Madewell Grading System of bone lesion margination. IA = geographic well-defined lesions with marginal sclerosis; IB = geographic well-defined lesions without marginal sclerosis; II = geographic lesions with ill-defined margins, originally designated IC by Lodwick, found to carry an intermediate risk of malignancy (approximately 50%); IIIA = lesions with changing margins; IIIB = nongeographic margins with moth-eaten or permeative osteolysis; IIIC = radiographically occult lesions with invisible margins.

the notion that grade assignment should reflect the highest and most concerning pattern of bone destruction. They also introduced the concept of invisible margins to include aggressive, infiltrative tumors advancing through the medullary canal and cancellous bone more rapidly than host osteoclastic activity resulting in an absence of visible osteolysis at radiography. The development and utilization of modern imaging technologies such as MRI and PET has provided increasing support to this concept.

Recently, the modified Lodwick-Madewell grading system (Fig. 1) was developed to include original designations proposed by Lodwick and incorporate concepts defined by Madewell, while classifying solitary osteolytic bone lesions as having a low, intermediate, or high risk of malignancy [3]. Caracciolo et al proposed a modified grading system that was retrospectively applied to 183 osteolytic bone lesions with a wide range of both benign and malignant histopathologic diagnoses [3]. This system defined grade I lesions as geographic well-defined lesions with (IA) or without (IB) marginal sclerosis, similar to Lodwick's original classification, and which were found to carry a low risk of malignancy (less than 10%). Grade II lesions defined as geographic lesions with ill-defined margins, originally designated IC by Lodwick, were found to carry an intermediate risk of malignancy (approximately 50%). Grade III lesions were found to have an increased risk of malignancy (greater than 80%) and included lesions with changing margins (IIIA), nongeographic margins with moth-eaten or permeative osteolysis (IIIB), and radiographically occult lesions with invisible margins (IIIC) identified by other imaging modalities. This grading system is used in the Bone-RADS scoring system.

Periosteal Reaction. Periosteal reaction occurs as a result of external or intrinsic mechanical forces applied to cortical bone and is the process by which bones respond to stress, known as Wolff's Law, which states that the pattern of periosteal reaction is a result of the duration or rate of change and intensity of the inciting factor [2,5]. For example, chronic alterations in weight-bearing forces lead

to cortical buttressing and solid periosteal new bone formation. In the case of an underlying bone neoplasm, the rate of growth and endosteal forces placed on the host bone result in variable patterns of cortical remodeling or periosteal reaction. Indolent, slow-growing neoplasms allow for cortical remodeling to keep pace with tumor growth resulting in continuous smooth, undulating, or solid periosteal reaction. Aggressive, malignant bone neoplasms typically advance more rapidly than the host bone response often resulting in irregular or complex periosteal reaction [2,6]. On average, periosteal reaction requires 10 days to 3 weeks from the initial stimulus to become visible by radiographs, often more rapid in younger patients [2,7]. As with other bone imaging features, periosteal reaction should be classified as *indolent* or *aggressive*, rather than benign or malignant—with osteomyelitis an oft-cited example of a benign but aggressive process [2,8]. Although characterization of periosteal reaction can be challenging, particularly when a complex pattern is present, it is an important component of the radiographic assessment of tumor growth rate and risk of malignancy [2-8].

The system first described in 1981 by Ragsdale et al for the classification of periosteal reaction is still used today [2]. When interpreting periosteal reaction, the bone cortex should be categorized as either *remodeled* or *present with periosteal reaction*. Cortical remodeling is typical of indolent bone lesions (Fig. 2). When the native cortex is present, the pattern of periosteal reaction helps predict aggressiveness of the underlying lesion (Figs. 3-5) [2].

Remodeling is typically associated with slow-growing lesions and is seen when outward pressure from an indolent lesion results in synchronous endosteal resorption and periosteal new bone formation [2]. As a result, a neocortex, typically a thin shell, replaces the original thicker cortex. Although this process is often described as "bone expansion," this is in fact a misnomer as the original cortex is slowly replaced over time by new bone along the outer cortical layer [2]. Pressure that is uniform in both time and space results in a smooth thin cortical shell (Fig. 2a). A ridged and septated shell suggests that there have been variations in temporal and spatial growth rate (Fig. 2b), and more focal variations in growth rate result in a thin shell that appears more lobulated than ridged (Fig. 2c). Finally, a thick shell indicates slow, indolent growth allowing for solid dense periosteal new bone formation [2].

If the original cortex is wholly or partially present—although possibly disrupted in the case of aggressive bone tumors—attempted new bone formation along the cortical surface results in one of several patterns of periosteal reaction. A smooth solid periosteal reaction indicates chronicity with layers of dense new bone being added slowly over time (Fig. 3a) [2]. Other patterns of periosteal reaction in increasing order of aggressiveness include lamellated, parallel spiculated, and divergent spiculated [2]. Lamellated periosteal reaction (Fig. 3c) has been described as having an "onion skin" appearance and can be seen in benign but aggressive conditions such as Langerhans cell histiocytosis as well as malignant small round blue cell tumors. Parallel spiculated periosteal reaction (Fig. 4a) having a "hair-on-end" appearance is typically an indication of malignancy, such as osteosarcoma, and is rarely seen with benign tumors. The spicules may be coarse or fine and close inspection may reveal a fine network of bridging mineralization resulting in a honeycomb appearance. Divergent spiculated periosteal reaction (Fig. 4b) has been described as having a

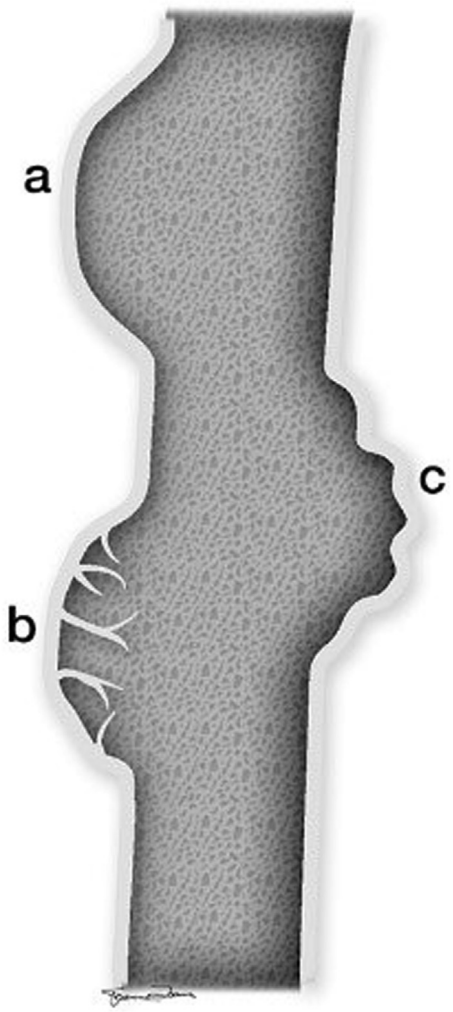

Fig. 2. Nonaggressive patterns of bony remodeling—the native cortex has slowly been replaced by a thin cortical shell, or neocortex, due to gradual concurrent endosteal resorption and periosteal new bone formation. (a) Smooth cortical shell. (b) Ridged and septated cortical shell. (c) Lobulated cortical shell.

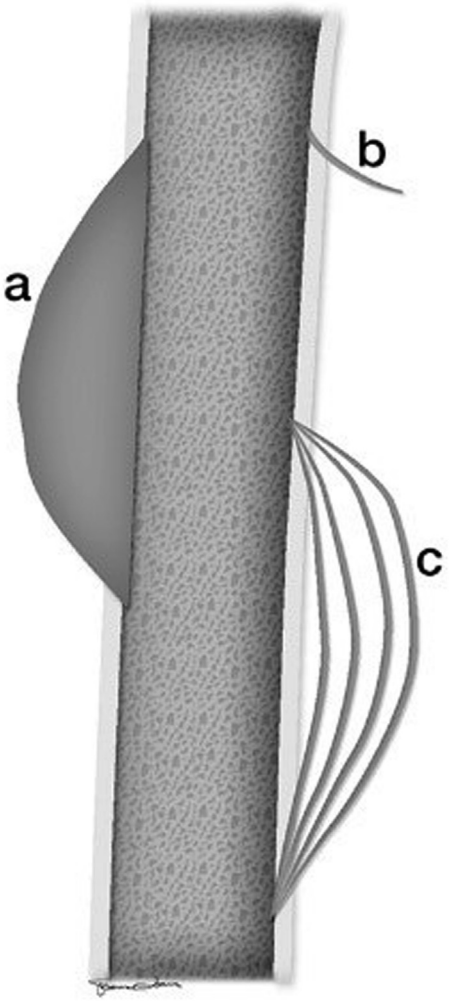

Fig. 3. Patterns of periosteal reaction with intact native cortex. (a) Dense and solid layers of periosteal new bone formation typical of an indolent bone lesion. (b) Codman's angle, elevated and acutely disrupted periosteum, typical of an aggressive bone tumor with extra-osseous mass lifting and breaking through the surface periosteum. (c) Lamellated periosteal reaction, or "onion-skinning," is often seen in aggressive etiologies including malignant neoplasms such as Ewing sarcoma but also benign etiologies such as osteomyelitis.

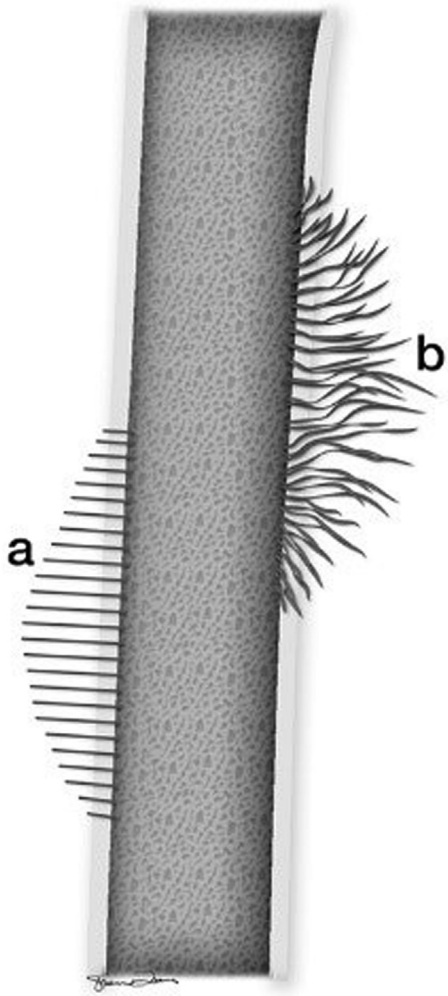

Fig. 4. Aggressive patterns of periosteal reaction. (a) Parallel spiculated, or "hair-on-end," periosteal reaction often seen in osteosarcoma. (b) Divergent spiculated, or "sunburst," periosteal reaction also typical of aggressive neoplasms.

"sunburst" appearance and results from a combination of periosteal reaction and mineralized tumor matrix [2].

In cases of aggressive tumors with neoplastic soft tissue breaking through cortical bone, the periosteum may appear elevated and interrupted. A specific example of this is Codman's angle, seen as elevated and acutely disrupted periosteal reaction at the shoulder of a soft tissue mass (Fig. 3b). Finally, complex or combined patterns (Fig. 5a and b) of periosteal reaction occur suggesting variable growth rate as may be seen with malignant transformation of a benign bone lesion [2].

Endosteal Erosion. Endosteal pressure from a medullary bone lesion often results in endosteal erosions, or endosteal scalloping [9]. The degree of erosion is graded as mild, moderate, and severe (grade 1, 2, and 3) and is relative to cortical thickness. Grade 1 or mild endosteal erosion is considered to be less than one-third of cortical thickness. Grade 2 or moderate endosteal erosion is between one- and two-thirds of cortical thickness. Grade 3 or severe endosteal erosion is greater than two-thirds cortical thickness or cortical disruption. Greater degree or depth of scalloping suggests increased biologic activity and increased risk of malignancy [10,11].

Pathological Fracture. Pathological fracture can occur with benign bone tumors as well as primary and secondary malignant bone tumors; however, the risk of fracture is

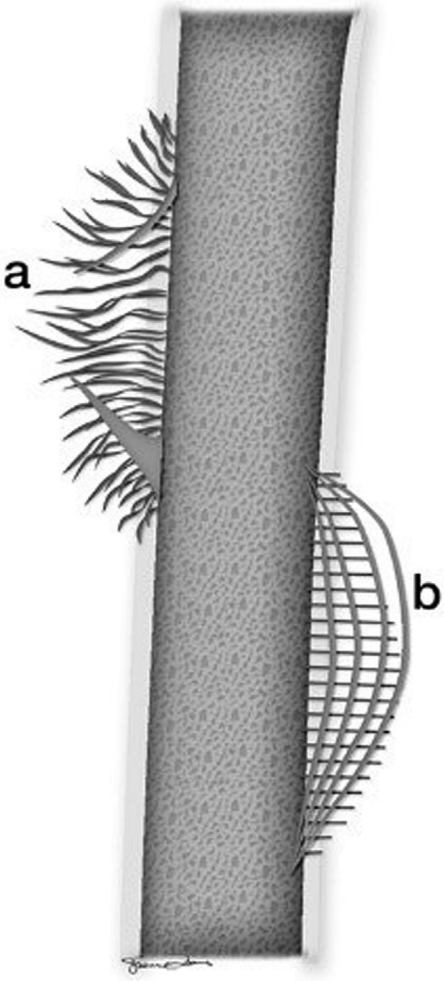

Fig. 5. Complex or mixed patterns of periosteal reaction often seen in tumors with variable growth rates as may been seen in malignant transformation of a pre-existing benign bone tumor. (a) Divergent spiculated periosteal reaction with Codman's angles. (b) Lamellated and parallel spiculated periosteal reaction.

greatest in the setting of metastatic disease. Pathological fracture is fraught with significant negative clinical implications including pain, reduced limb function, and, most importantly, decreased survival [12-15]. It is estimated that 3% to 6% of cancer patients, approximately 50,000 to 100,000 people, present annually with an initial complaint of bone pain [16-19]. Meanwhile, of 1.7 million new US cancer diagnoses each year, approximately 733,000 demonstrate propensity for osseous metastatic disease including breast, lung, prostate, renal, and thyroid cancers [20]. The number of patients in the United States currently living with bony metastatic disease is estimated to be between 280,000 and >400,000 [16,21]. Although the incidence of pathological fracture secondary to primary bone malignancy is lower than metastatic disease, fractures are often associated with tumor contamination of the surrounding soft tissues, leading to higher rates of local recurrence sometimes necessitating amputation [14,15,22,23]. For these reasons, the presence of a pathological fracture is considered a high-risk feature for malignant bone disease.

All patients presenting with a bone lesion should be evaluated for risk of impending or pathological fracture. Risk assessment begins with a thorough history and physical examination and is followed by diagnostic radiography. Orthogonal radiographs are performed to evaluate radiodensity (osteolytic or osteoblastic), site and extent of bone involvement, and proximity to articular surfaces. Snell and Beals first described a pathological fracture risk stratification system based on the radiographic appearance of bone lesions [24]. A subsequent scoring system described by Mirels is most commonly used today and relies on four radiographic and clinical variables: lesion size (cortical involvement), location, radiodensity, and pain [25].

Extra-Osseous Soft Tissue Mass. Identification of cortical breakthrough with an associated extra-osseous soft tissue mass is an extremely concerning finding that should raise high suspicion of malignancy [26]. Primary and secondary osseous malignancies may present an extra-osseous soft tissue mass [27]. In the case of chondrosarcoma, early detection of extra-osseous extension of disease may be the first indication of malignant transformation of a pre-existing benign cartilaginous lesion. At radiography, soft tissue fullness, distortion of fat planes, and asymmetry or increased density relative to adjacent tissues may indicate the presence of a soft tissue mass. In other cases, subtle cortical or periosteal discontinuity may suggest early extra-osseous extension of disease. However, it must be noted that cross-sectional imaging, particularly MRI, is far superior in delineating soft tissue masses than radiographs.

Radiographic Features to Predict Histopathology

Radiographic Density. Osseous lesions are visible on skeletal radiography due to differences in density and photon attenuation between the lesion and the surrounding normal bone. Radiographic density of a bone lesion may be less predictive of benignity or malignancy, but density directly impacts differential considerations. In this regard, bone lesions should be categorized as lytic, sclerotic, or mixed in an effort to construct an appropriate differential diagnosis [28]. Lytic lesions (osteolytic or radiolucent lesions) carry the broadest differential diagnosis including numerous primary and secondary benign and malignant neoplasms, infection, and metabolic bone disorders among

other etiologies. They may be best appreciated when involving the metaphysis or epiphysis of a long bone due to osteoclastic bone resorption in response to an underlying tumor outlined by intact bone trabeculae. Lytic lesions involving the diaphysis are more often identified as a result of cortical involvement such as endosteal scalloping due to a relative lack of trabeculae in the mid shaft of long bones [29].

Benign bone tumors with a radiolucent appearance would include giant cell tumor, simple and aneurysmal bone cyst, fibrous dysplasia, and Brown tumor of hyperparathyroidism among others; associated findings such as matrix and periosteal reaction help narrow the differential diagnosis [28]. Malignant bone tumors with a purely lytic appearance would include multiple myeloma, metastatic disease, fibrosarcoma of bone, and rare subtypes of osteosarcoma (fibroblastic) and chondrosarcoma (dedifferentiated).

Sclerotic lesions (osteoblastic or radiodense lesions) demonstrate density greater than surrounding bone when seen at skeletal radiography. Radiodensity results from either reactive osteoblastic new bone formation by the host bone or intrinsic tumor matrix of a primary bone neoplasm. Sclerotic bone lesions are less common than lytic lesions, and the differential diagnosis is narrower. Common considerations for an osteoblastic lesion include reactive sclerosis of healing fracture; sclerotic response to chemotherapy; primary benign and malignant osteoid-forming tumors such as osteoid osteoma, osteoblastoma, and osteoblastic osteosarcoma; osteoblastic metastatic disease; osseous lymphoma; and chronic osteomyelitis. Evaluation of the pattern and margins of sclerosis help narrow the differential diagnosis [30]. Common osteoblastic metastases include breast, prostate, urothelial, and neuroendocrine cancers.

Mixed lytic and sclerotic bone lesions, as the descriptor implies, have both radiolucent and radiodense components. Evaluation of the radiographic features of the osteolytic elements including margins and matrix as well as the pattern of sclerosis helps suggest etiology. As mentioned, sclerosis may be reactive or represent internal tumor matrix. An organized or geometric pattern of sclerosis often suggests benignity. For example, linear sclerosis may be related to fracture healing, and serpentine or peripheral sclerosis is typical of osteonecrosis. Amorphous radiodensity within an osteolytic lesion is less specific but may raise concern for a bone-forming tumor including subtypes of osteosarcoma such as chondroblastic and telangiectatic osteosarcoma. Primary lymphoma of bone also commonly demonstrates mixed density including areas of ill-defined osteolysis and patchy sclerosis [31].

Matrix Mineralization. Tumor matrix represents the internal composition of a tumor and reflects the cell line of origin. Mineralized tumor matrix may be classified as osteoid or chondroid with corresponding cell lines consisting of osteoblastic (bone-forming) or chondrocytic (cartilage-forming) tissue. Fibrous, lipomatous, angiomatous, and cystic bone lesions typically demonstrate no mineralized matrix, appearing purely lucent on bone radiographs. Additionally, skeletal metastases and multiple myeloma are most often radiolucent without intrinsic mineralization.

Osteoid is a proteinaceous precursor substrate secreted by osteoblasts that becomes mineralized during the process of new bone formation. Benign and malignant bone-forming tumors are histologically defined by the presence of osteoid at microscopy. Common examples include osteoid osteoma, osteoblastoma, and osteosarcoma. At radiography, osteoid-forming neoplasms typically appear radiodense with amorphous and cloudlike mineralization [32]. Although visualization of osteoid matrix is indicative of a bone-forming lesion, patient demographics, location, and associated radiographic features such as periosteal reaction are critical to construct an appropriate differential diagnosis.

Cartilaginous neoplasms are typically centrally located, intramedullary radiolucent lesions with a lobular morphology and "rings and arcs," flocculent or flecklike calcifications [33]. Cartilaginous tumors tend to be slow growing and may demonstrate marginal sclerosis. Cortical remodeling and buttressing are common. Cartilaginous tumors include enchondroma, chondroblastoma, osteochondroma, and chondrosarcoma, among others [11]. The cartilaginous cap of an osteochondroma typically demonstrates chondroid mineralization.

Absence of mineralized matrix results in a purely radiolucent appearance at radiography [34,35]. Many benign and malignant primary and secondary bone tumors present as purely lytic lesions including most fibrous, lipomatous, and vascular neoplasms as well as multiple myeloma and metastatic disease. The common dominant constituent cell of fibrous neoplasms is the fibroblast [36]. Most fibrous bone lesions including fibrosarcoma demonstrate a purely lytic appearance without intrinsic mineralization. Fibrous dysplasia is a common exception, often described as having a "ground glass" appearance with hazy radiodensity, absence of internal mineralization, and often a peripheral sclerotic rim (eg, "rind sign"). Fibrous dysplasia may also demonstrate a mixed radiolucent and radiodense appearance due to the presence of fibrous- and bone-forming elements. Meanwhile, internal calcifications may be seen in intraosseous lipoma with fat necrosis and dystrophic calcifications [37,38] and intraosseous hemangioma with thickened trabeculae [39].

Lesion Location. Anatomic localization of a bone lesion is extremely important when predicting histopathology.

Lesion location is defined by the (1) specific bone involved as well as (2) longitudinal and (3) transverse position within the bone itself [40]. Viewing these three location parameters in unison with other imaging characteristics and clinical information is crucial to construct an accurate differential diagnosis for both benign and malignant entities.

Certain musculoskeletal tumors demonstrate known predilection for specific sites within the axial or appendicular skeleton and individual bones often carry unique differential diagnoses [28,41-45]. For example, multiple well-circumscribed, lytic lesions within the small tubular bones of the hand most often represent enchondromas [26]. Adamantinoma almost exclusively involves the anterior cortex of the proximal to mid tibia, and parosteal osteosarcoma frequently occurs along the posterior aspect of the distal femur [46,47]. Marrow-based malignancies such as Ewing sarcoma are more common in flat bones than other primary bone cancers such as osteosarcoma [28,48,49]. These are simply a few examples; numerous tables and references demonstrating location propensity of bone neoplasms can be found in the existing literature.

It is important to note a fundamental guiding principle in the assessment of skeletal diseases as it relates to location of a potentially neoplastic lesion—determination of solitary versus multifocal bone involvement. Plurality of bone involvement significantly increases risk of malignancy (consider myeloma, metastases, and lymphoma), although several benign processes may present with polyostotic disease including Langerhans cell histiocytosis, enchondromatosis, and fibrous dysplasia [50,51].

Lesion pathophysiology frequently is reflected by its longitudinal position within bone, whether epiphyseal, metaphyseal, or diaphyseal. A metaphyseal position suggests an entity related to bone turnover (eg, osteosarcoma) or rich vascularity (eg, processes spread through a hematogenous route such as osteomyelitis or metastatic disease). Diaphyseal lesions often portend neoplasms based in a hematopoietic marrow distribution with small, round, blue cell tumors such as Ewing sarcoma and lymphoma often involving the long bone shafts [28]. Epiphyseal location, on the other hand, generally connotes a benign entity with malignant lesions rarely presenting in the epiphyses [28]. As an epiphyseal equivalent, the apophysis is considered to have the same differential diagnosis considerations as other "end of bone" lesions [28]. It is also important to note that longitudinal position is helpful in ascertaining nonneoplastic bone lesions that may mimic bone tumors [28,52]. For example, apophyseal lesions in adolescents may suggest avulsion injury in the absence of contradicting imaging features.

Position of a lesion within bone should also be characterized based on its anatomic position in the short axis, whether the epicenter of the lesion is central (intramedullary), eccentric (intramedullary), cortical, or surface based [28]. Although sometimes challenging in larger, ill-defined lesions, determination of transverse location can be particularly useful in determining probability of a specific entity. For example, consider an intracortical lesion with surrounding cortical thickening in an adolescent with pain relieved by salicylates consistent with osteoid osteoma [46]. Given precise anatomic location and clinical history, biopsy and ablative treatment can often be performed in conjunction without awaiting immediate histologic confirmation.

APPLICATION OF THE BONE-RADS SCORING SYSTEM

As discussed previously and shown in Tables 1 and 2, bone lesions seen at diagnostic radiography can be assessed for features predictive of risk of malignancy and features suggestive of histopathology. Point values are assigned to risk predictive features and summed to yield a point total. The point total is translated to a Bone-RADS score of 1 to 4 to convey increasing risk of malignancy and provide management suggestions (Table 3).

Bone-RADS 0—Incompletely Characterized

Poorly visualized or incompletely evaluated bone lesions that require further assessment before risk assignment (Fig. 6).

Example: lucent bone lesions involving the axial skeleton faintly or incompletely seen at diagnostic radiography.

Margins, periosteal reaction, and cortical involvement may be difficult to adequately evaluate in the scapula, spine, and pelvis. These lesions should not yet be assigned risk of malignancy. Additional radiographic views or cross-sectional imaging should be performed for further evaluation before risk assignment.

Bone-RADS 1—Very Low Risk of Malignancy

Very likely benign bone lesions with typical imaging features of a benign bone tumor (Fig. 7).

Examples: a classic pathognomonic benign "do not touch" bone lesions with circumferential marginal sclerosis such as nonossifying fibroma; a cortically based lucent lesion with solid smooth surrounded periosteal reaction consistent with osteoid osteoma.

Classic pathognomonic benign bone lesions may not require surveillance or may be surveilled annually to ensure expected stability, unless there is a change in clinical symptoms such as new pain or fracture. In cases of symptomatic benign bone lesions, orthopedic oncology referral or cross-sectional imaging may be indicated before treatment of a benign bone tumor, which may include curettage and bone augmentation. For example, in osteoid osteoma, CT is

Table 3. Bone-RADS scoring system with management suggestions

Bone-RADS Score	Risk Assessment, Description, and Examples	Management Suggestions
0 = Incompletely characterized Point total = N/A	▪ Risk cannot be adequately predicted ▪ Further workup is necessary ▪ Example: lucent lesions of the axial skeleton such as scapula, spine, or pelvis	▪ Additional radiographic views or cross-sectional imaging for further evaluation
1 = Very low risk Point total = 1-2	▪ Pathognomonic benign bone lesion ▪ Classic "do not touch" lesion ▪ Examples: nonossifying fibroma, osteoid osteoma	▪ If asymptomatic, consider workup to be complete vs annual surveillance to ensure expected stability ▪ If symptomatic or change in clinical presentation, consider advanced imaging and orthopedic oncology referral for treatment of benign tumor
2 = Low risk Point total = 3-4	▪ Asymptomatic geographic lytic lesion without suspicious periosteal reaction or deep endosteal erosion ▪ Typical location or matrix of a common benign bone lesion ▪ Examples: chondroblastoma, giant cell tumor, aneurysmal bone cyst	▪ Short-interval (3-6 months) surveillance to ensure stability ▪ Consider advanced imaging to assess tumor composition and possibly biopsy to confirm benignity if needed ▪ Consider orthopedic oncology referral for surveillance or treatment of benign tumor
3 = Intermediate risk Point total = 5-6	▪ Geographic lytic lesion in a patient with known primary malignancy elsewhere ▪ Geographic, but ill-defined lytic lesion	▪ Orthopedic oncology referral for probable biopsy and treatment planning ▪ Recommend advanced imaging such as CT, MRI, or bone scan for further characterization
4 = High risk Point total = 7 or greater	▪ Malignant until proven otherwise ▪ Geographic lytic lesion with aggressive periosteal reaction or soft tissue mass ▪ Nongeographic osteolytic lesion	▪ Orthopedic oncology referral for recommended biopsy and treatment planning ▪ Advanced imaging for tumor staging including additional sites of disease

Bone-RADS = Bone Reporting and Data System; N/A = not applicable.

commonly performed for nidus localization and guidance of radiofrequency ablation.

Bone-RADS 2—Low Risk of Malignancy

Probably benign bone lesions without any aggressive radiographic features or known history of primary malignancy elsewhere (Fig. 8).

Examples: an incidental asymptomatic geographic lucent bone lesion in patient without history of primary cancer elsewhere; a geographic lucent lesion without marginal sclerosis extending to subchondral bone most suggestive of giant cell tumor; an asymptomatic lucent medullary lesion with chondroid matrix and minimal endosteal scalloping most consistent with enchondroma; a geographic eccentric expansile lucent lesion with solid cortical remodeling suggestive of aneurysmal bone cyst.

A broad range of diagnoses comprise this category and require careful consideration of radiographic features and patient history. In asymptomatic cases, short-interval (3-6 months) surveillance could be performed to ensure stability; radiographic changes would prompt further evaluation for a change in biologic activity such as malignant transformation. In some cases, patient anxiety or uncertainty may direct biopsy to confirm benignity. For benign but symptomatic or locally aggressive bone tumors such as giant cell tumor, orthopedic oncology referral for treatment with curative intent is suggested. Advanced imaging such as CT, MRI, skeletal scintigraphy, or PET scan could be performed to provide additional information regarding tumor morphology and composition or physiologic activity, which may better inform the treatment plan.

Bone-RADS 3—Intermediate Risk of Malignancy

Potentially malignant bone lesions with one or more suspicious radiographic features or history of primary malignancy elsewhere (Fig. 9).

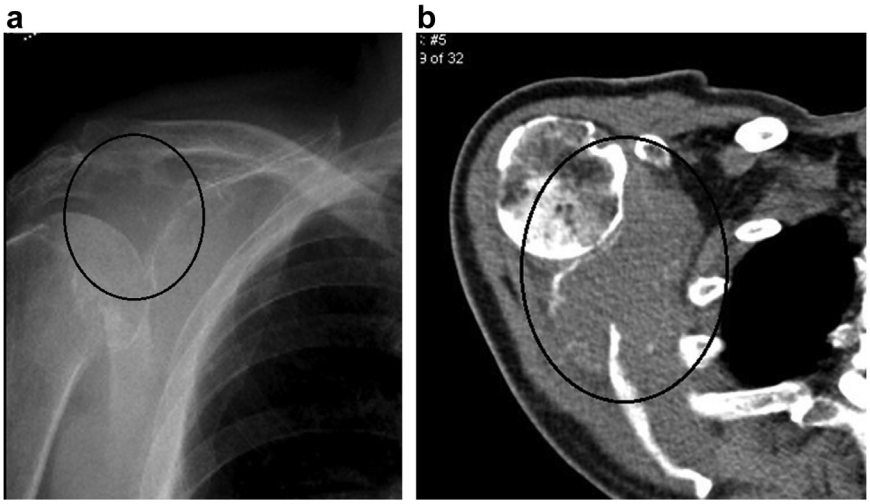

Fig. 6. Bone-RADS 0. (a) Anteroposterior radiograph of the right shoulder demonstrates an osteolytic lesion of the scapula, partially obscured by overlying humeral head—margins and cortical breakthrough are not well evaluated and therefore additional imaging was recommended. (b) Axial CT demonstrates soft tissue mass with cortical destruction and extra-osseous extension of disease; subsequent biopsy confirmed plasmacytoma. Bone-RADS = Bone Reporting and Data System.

Examples: a geographic, but ill-defined lytic lesion that could be neoplastic or represent osteomyelitis in the appropriate scenario; a geographic, well-defined lytic lesion in a patient with a known history of lung cancer.

This category includes bone lesions that are indeterminate but worrisome for possible malignancy. Many will require percutaneous imaged-guided or surgical biopsy to establish a definite diagnosis. As such, orthopedic oncology referral is recommended. Additionally, advanced imaging may be suggested for further evaluation of the tumor itself and treatment or surgical planning. It is recommended that biopsy be performed in consultation with the orthopedic oncologist, who would provide definitive treatment if malignancy is confirmed.

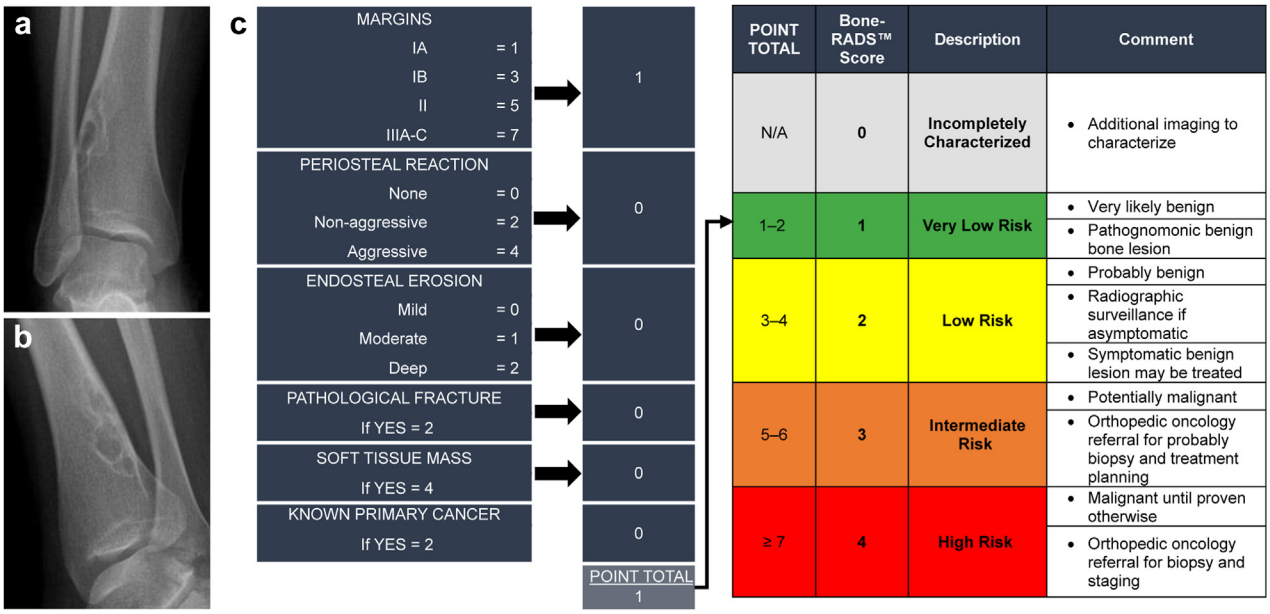

Fig. 7. Bone-RADS 1. (a) Anteroposterior radiograph of the right ankle of a 15-year-old female patient demonstrating an eccentric distal tibial bone lesion with circumferential sclerosis (modified Lodwick-Madewell grade IA lesion) pathognomonic for nonossifying fibroma. (b) Oblique radiograph with similar findings. (c) Application of Bone-RADS system giving 1 point for margins and 0 points for all other features yielding point total = 1 and Bone-RADS score of 1. Bone-RADS = Bone Reporting and Data System; IA = geographic well-defined lesions with marginal sclerosis.

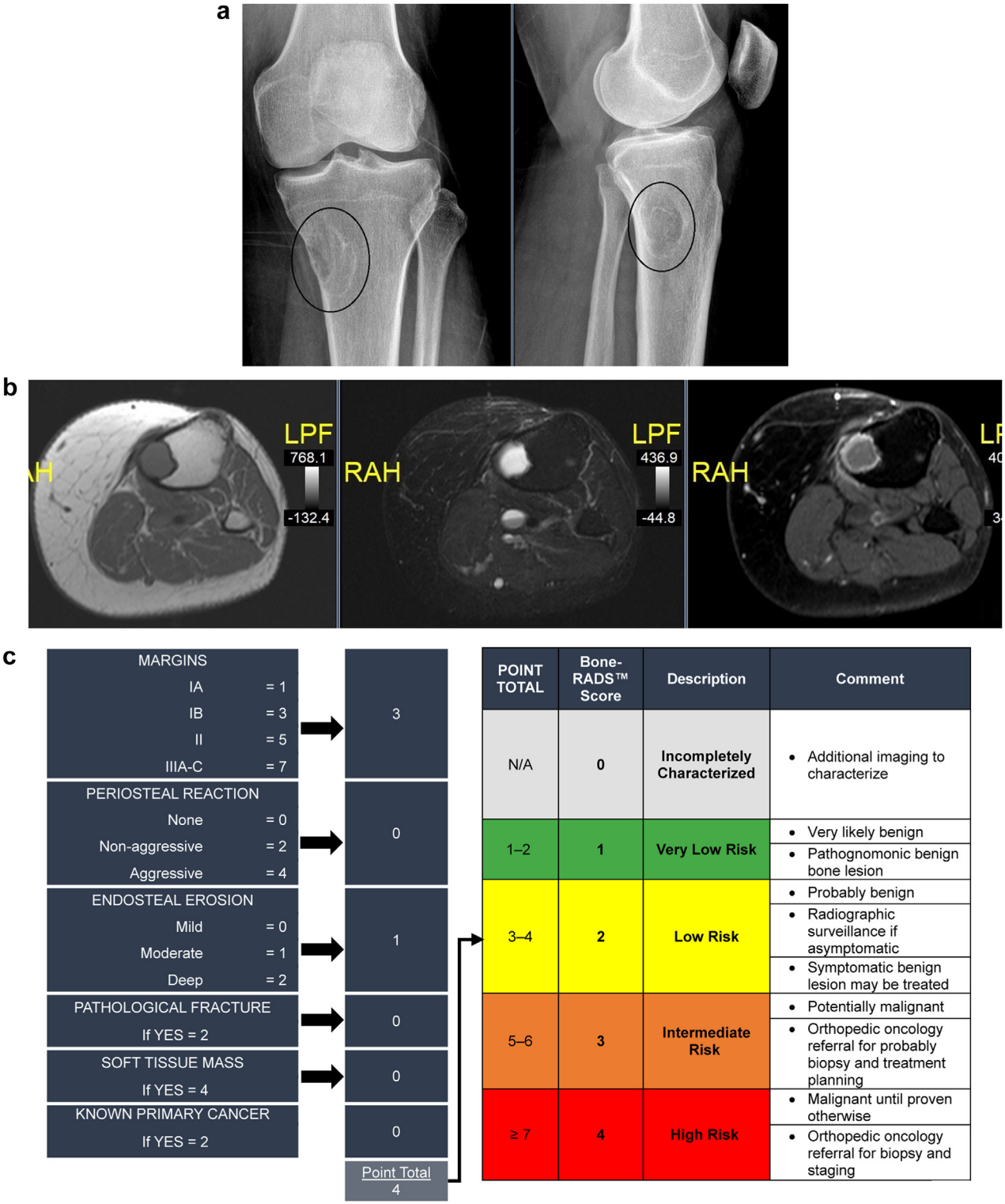

Fig. 8. Bone-RADS 2. (a) Anteroposterior and lateral radiographs of the left knee of a 59-year-old woman demonstrating a well-defined geographic osteolytic proximal tibial bone lesion with incomplete marginal sclerosis (modified Lodwick-Madewell grade IB lesion) and moderate medial endosteal scalloping. Given patient age, routine blood work including complete blood count, complete metabolic profile, lactate dehydrogenase, alkaline phosphatase, erthrocyte sedimentation rate, C-reactive protein, serum protein electrophoresis and urinalysis was performed, and an MRI was requested for further evaluation of the bone lesion. (b) Axial T1-weighted, short tau inversion recovery, and contrast-enhanced MR images demonstrate a simple appearing unicameral bone cyst with mild cortical thinning and minimal periostitis. (c) Application of Bone-RADS system

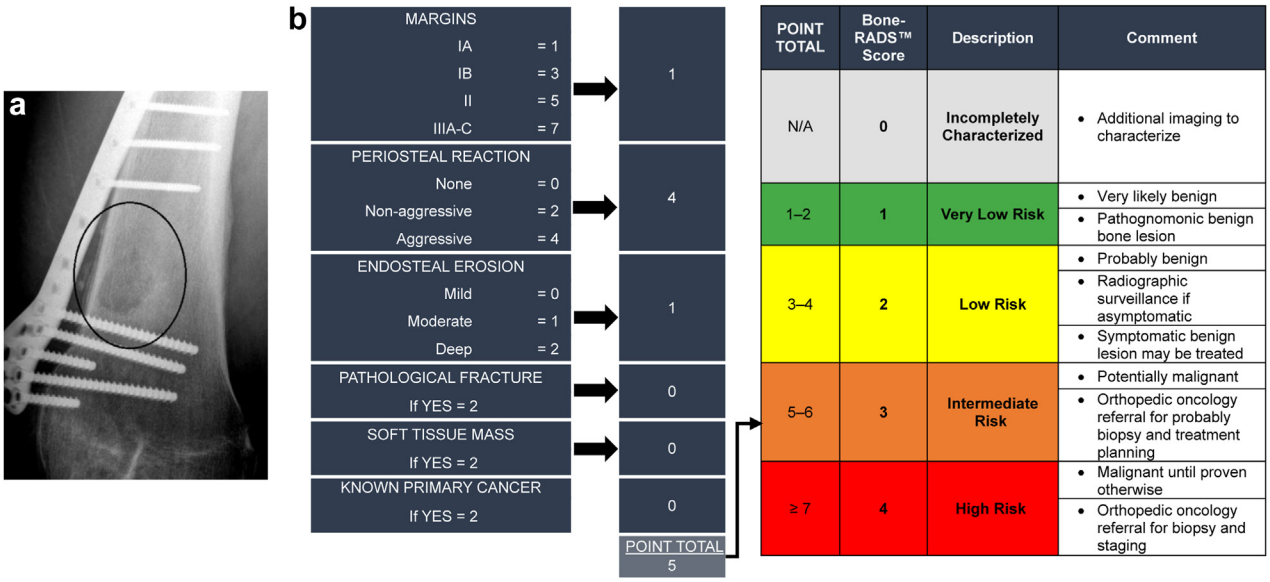

Fig. 9. Bone-RADS 3. (a) Anteroposterior radiograph of the knee of an elderly patient status post–remote lateral plate of screw fixation of the femur demonstrating a geographic well-defined osteolytic lesion with hazy surrounding marginal sclerosis (modified Lodwick-Madewell grade IA lesion) and lamellated periosteal reaction. (b) Application of Bone-RADS system giving 1 point for margins, 4 points for periosteal reaction, and 0 points for all other features yielding point total = 5 and Bone-RADS score of 3. Subsequent biopsy revealed inflammatory cells with positive cultures consistent with Brodie's abscess. Bone-RADS = Bone Reporting and Data System; IA = geographic well-defined lesions with marginal sclerosis; IB = geographic well-defined lesions without marginal sclerosis; II = geographic lesions with ill-defined margins, originally designated IC by Lodwick, found to carry an intermediate risk of malignancy (approximately 50%); IIIA-C = lesions with changing margins, nongeographic margins with moth-eaten or permeative osteolysis, and radiographically occult lesions with invisible margins identified by other imaging modalities.

Bone-RADS 4—High Risk of Malignancy

Highly suspicious bone lesions that are considered malignant until proven otherwise (Fig. 10).

Examples: a nongeographic osteolytic lesion with moth-eaten or permeative osteolysis; an osteolytic lesion with an associated soft tissue mass.

These lesions demonstrate highly worrisome radiographic features typical of malignancy such as nongeographic permeative or moth-eaten osteolysis, aggressive periosteal reaction, or cortical breakthrough with an associated extra-osseous soft tissue mass. Orthopedic oncology referral is recommended for clinical assessment, advanced imaging as clinically indicated, confirmatory biopsy, tumor staging, and treatment planning.

CONCLUSION

The Bone-RADS scoring system was developed via consensus by an ACR-sponsored committee of leading experts in the fields of musculoskeletal oncology imaging and orthopedic oncology. The system incorporates several radiographic features of a potentially neoplastic bone lesion and pertinent patient history to risk stratify bone lesions and provide risk-directed recommendations for management. As discussed, features predictive of risk of malignancy include lesion margination, pattern of periosteal reaction, depth of endosteal erosion, evidence of impending or pathological fracture, and signs of extra-osseous extension of disease. Meanwhile, radiodensity, matrix, and location help inform tumor histopathology. Assigned point values for risk predictive features are summed to yield a point total, which forms the foundation of the Bone-RADS scoring system. The Bone-RADS scoring system can be applied to any newly diagnosed potentially neoplastic bone lesion with score assignment designed to convey risk of malignancy and in turn direct appropriate patient management. It is the hope and opinion of the Bone-RADS Committee that careful evaluation of the radiographic features of a

giving 3 points for margins, 1 point for endosteal erosion, and 0 points for all other features yielding point total = 4 and Bone-RADS score of 2. Bone-RADS = Bone Reporting and Data System; IB = geographic well-defined lesions without marginal sclerosis.

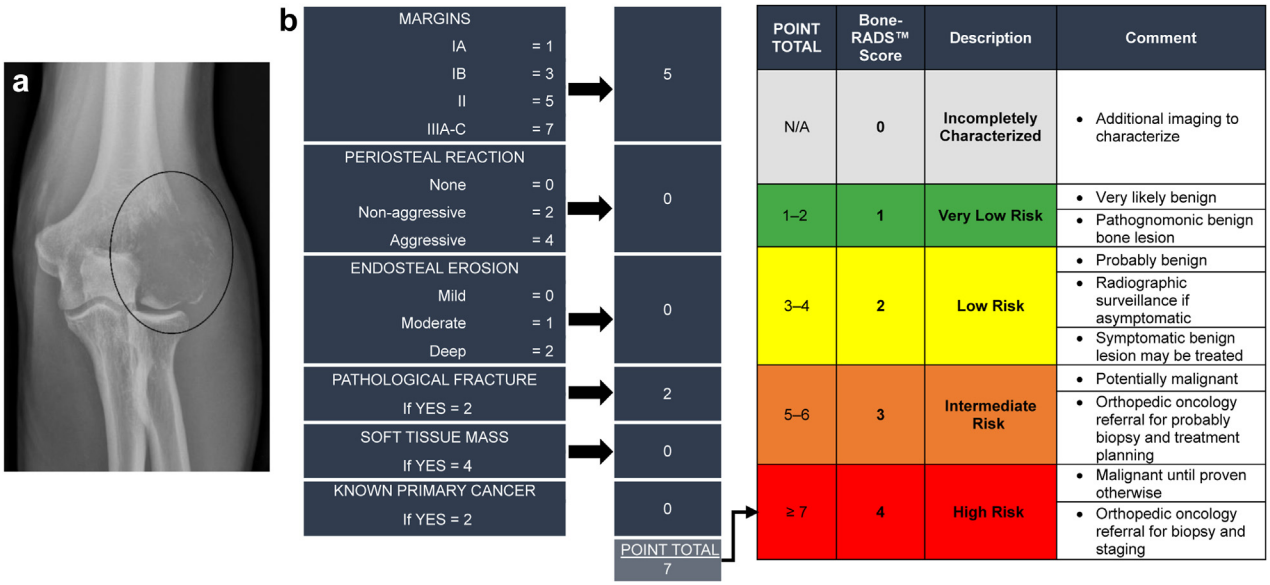

Fig. 10. Bone-RADS 4. (a) Anteroposterior radiograph of the elbow of a 66-year-old male patient presenting with elbow pain and no known history of malignancy demonstrating a geographic but ill-defined osteolytic lesion of the distal humerus (modified Lodwick-Madewell grade II lesion) with pathological cortical fractures. (b) Application of Bone-RADS system giving 5 points for margins, 2 points for pathological fracture, and 0 points for all other features yielding point total = 7 and Bone-RADS score of 4. Subsequent biopsy confirmed poorly differentiated carcinoma of unknown primary site. Further workup revealed other osseous and abdominal visceral metastases as well as a scalp lesion, which was biopsied and consistent with carcinoma. Bone-RADS = Bone Reporting and Data System; IA = geographic well-defined lesions with marginal sclerosis; IB = geographic well-defined lesions without marginal sclerosis; II = geographic lesions with ill-defined margins, originally designated IC by Lodwick, found to carry an intermediate risk of malignancy (approximately 50%); IIIA-C = lesions with changing margins, nongeographic margins with moth-eaten or permeative osteolysis, and radiographically occult lesions with invisible margins identified by other imaging modalities.

potentially neoplastic bone lesion will allow for accurate assessment of risk of malignancy and assignment of a corresponding Bone-RADS score to facilitate more effective patient triage, utilization of advanced imaging, and treatment planning.

A standardized imaging report template for diagnostic radiography is included as an e-only appendix.

TAKE-HOME POINTS

- Assessment and management of potentially neoplastic bone lesions should be directed by risk of malignancy.
- Risk stratification is based on several key radiographic features and clinical risk factors.
- Radiographic features and clinical risk factors can each be assigned points to yield a Bone-RADS score with corresponding risk of malignancy.
- Based on Bone-RADS score and risk, appropriate management recommendations, such as surveillance or biopsy, can be presented to referring clinicians in effort to improve communication and patient treatment planning.

ACKNOWLEDGMENTS

The Bone-RADS Committee acknowledges and thanks the ACR staff members (Cassandra Vivian-Davis, David Kurth, Valerie Kasdan, and Lauren Attridge) for their invaluable guidance and assistance throughout the term of our committee and Susanne Loomis for her contribution of illustrations of patterns of periosteal reaction.

ADDITIONAL RESOURCES

Additional resources can be found online at: https://doi.org/10.1016/j.jacr.2023.07.017.

REFERENCES

1. Lodwick GS. Radiographic diagnosis and grading of bone tumors, with comments on computer evaluation. Proc Natl Cancer Conf 1964;5:369-80.
2. Madewell JE, Ragsdale BD, Sweet DE. Radiologic and pathologic analysis of solitary bone lesions. Part II: periosteal reactions. Radiol Clin North Am 1981;19:749-83.
3. Caracciolo JT, Temple HT, Letson GD, Kransdorf MJ. A modified Lodwick-Madewell grading system for the evaluation of lytic bone lesions. AJR Am J Roentgenol 2016;207:150-6.
4. Lodwick GS, Wilson AJ, Farrell C, Virtama P, Dittrich F. Determining growth rates of focal lesions of bone from radiographs. Radiology 1980;134:577-83.

5. Hillmann A, Link TM, Ozaki T, Vestring T, Winkelmann W. Computed direct magnification radiography of bone tumors. J Cancer Res Clin Oncol 2001;127:116-22.
6. Nichols RE, Dixon LB. Radiographic analysis of solitary bone lesions. Radiol Clin North America 2011;49:1095-114. v.
7. Priolo F, Cerase A. The current role of radiography in the assessment of skeletal tumors and tumor-like lesions. Eur J Radiol 1998;27(Suppl 1):S77-85.
8. Edeiken J, Hodes PJ, Caplan LH. New bone production and periosteal reaction. Am J Roentgenol Radium Ther Nucl Med 1966;97:708-18.
9. Sanders TG, Parsons TW 3rd. Radiographic imaging of musculoskeletal neoplasia. Cancer Control 2001;8:221-31.
10. Douis H, Parry M, Vaiyapuri S, Davies AM. What are the differentiating clinical and MRI-features of enchondromas from low-grade chondrosarcomas? Eur Radiol 2018;28:398-409.
11. Murphey MD, Flemming DJ, Boyea SR, Bojescul JA, Sweet DE, Temple HT. Enchondroma versus chondrosarcoma in the appendicular skeleton: differentiating features. Radiographics 1998;18:1213-37; quiz 44-5.
12. Biermann JS, Holt GE, Lewis VO, Schwartz HS, Yaszemski MJ. Metastatic bone disease: diagnosis, evaluation, and treatment. J Bone Joint Surg Am 2009;91:1518-30.
13. Macedo F, Ladeira K, Pinho F, et al. Bone metastases: an overview. Oncol Rev 2017;11:321.
14. Natarajan MV, Govardhan RH, Williams S, Raja Gopal TS. Limb salvage surgery for pathological fractures in osteosarcoma. Int Orthop 2000;24:170-2.
15. Salunke AA, Chen Y, Tan JH, Chen X, Khin LW, Puhaindran ME. Does a pathological fracture affect the prognosis in patients with osteosarcoma of the extremities? A systematic review and meta-analysis. Bone Joint J 2014;96-b:1396-403.
16. Li S, Peng Y, Weinhandl ED, et al. Estimated number of prevalent cases of metastatic bone disease in the US adult population. Clin Epidemiol 2012;4:87-93.
17. Destombe C, Botton E, Le Gal G, et al. Investigations for bone metastasis from an unknown primary. Joint Bone Spine 2007;74:85-9.
18. Katagiri H, Takahashi M, Inagaki J, Sugiura H, Ito S, Iwata H. Determining the site of the primary cancer in patients with skeletal metastasis of unknown origin: a retrospective study. Cancer 1999;86:533-7.
19. Piccioli A, Maccauro G, Spinelli MS, Biagini R, Rossi B. Bone metastases of unknown origin: epidemiology and principles of management. J Orthop Traumatol 2015;16:81-6.
20. Siegel RL, Miller KD, Jemal A. Cancer statistics, 2019. CA Cancer J Clin 2019;69:7-34.
21. Ashford R, Randall RL. Bone metastases: epidemiology and societal effect. Metastic Bone Disease 2016:3-11.
22. Xie L, Guo W, Li Y, Ji T, Sun X. Pathologic fracture does not influence local recurrence and survival in high-grade extremity osteosarcoma with adequate surgical margins. J Surg Oncol 2012;106:820-5.
23. Yin K, Liao Q, Zhong DA, et al. Meta-analysis of limb salvage versus amputation for treating high-grade and localized osteosarcoma in patients with pathological fracture. Exp Ther Med 2012;4:889-94.
24. Snell W, Beals RK. Femoral metastases and fractures from breast cancer. Surg Gynecol Obstet 1964;119:22-4.
25. Mirels H. Metastatic disease in long bones. A proposed scoring system for diagnosing impending pathologic fractures. Clin Orthop Relat Res 1989:256-64.
26. Melamud K, Drapé JL, Hayashi D, Roemer FW, Zentner J, Guermazi A. Diagnostic imaging of benign and malignant osseous tumors of the fingers. Radiographics 2014;34:1954-67.
27. Moulopoulos LA, Dimopoulos MA, Vourtsi A, Gouliamos A, Vlahos L. Bone lesions with soft-tissue mass: magnetic resonance imaging diagnosis of lymphomatous involvement of the bone marrow versus multiple myeloma and bone metastases. Leuk Lymphoma 1999;34:179-84.
28. Miller TT. Bone tumors and tumorlike conditions: analysis with conventional radiography. Radiology 2008;246:662-74.
29. Ragsdale BD, Sweet DE, Vinh TN. Radiology as gross pathology in evaluating chondroid lesions. Hum Pathol 1989;20:930-51.
30. Onitsuka H. Roentgenologic aspects of bone islands. Radiology 1977;123:607-12.
31. Krishnan A, Shirkhoda A, Tehranzadeh J, Armin AR, Irwin R, Les K. Primary bone lymphoma: radiographic-MR imaging correlation. Radiographics 2003;23:1371-83; discussion 84-7.
32. Resnick D, Kransdorf MJ. Bone and joint imaging. 3rd edition. New York: Elsevier; 2005.
33. Walden MJ, Murphey MD, Vidal JA. Incidental enchondromas of the knee. AJR Am J Roentgenol 2008;190:1611-5.
34. Hipfl C, Schwabe P, Märdian S, Melcher I, Schaser KD. [Benign cystic bone lesions]. Der Unfallchirurg 2014;117:892-904.
35. Tan E, C TM, Baker M. Benign osteolytic lesions in children with previously normal radiographs. J Pediatr Orthop 2017;37:e282-5.
36. Kumar R, Madewell JE, Lindell MM, Swischuk LE. Fibrous lesions of bones. Radiographics 1990;10:237-56.
37. Kheok SW, Ong KO. Benign periarticular, bone and joint lipomatous lesions. Singapore Med J 2017;58:521-7.
38. Eyzaguirre E, Liqiang W, Karla GM, Rajendra K, Alberto A, Gatalica Z. Intraosseous lipoma. A clinical, radiologic, and pathologic study of 5 cases. Ann Diagn Pathol 2007;11:320-5.
39. Lomasney LM, Martinez S, Demos TC, Harrelson JM. Multifocal vascular lesions of bone: imaging characteristics. Skeletal Radiol 1996;25:255-61.
40. Wodajo FMGF, Murphey MD. Visual guide to musculoskeletal tumors: a clinical-radiologic-histologic approach. Philadelphia, PA: Saunders Elsevier Health Sciences; 2010.
41. Hansford BG, Smith ZC, Stacy GS. Imaging of benign fibular tumours and their mimics. Can Assoc Radiol J 2018;69:293-302.
42. Thommesen P, Poulsen JO. Primary tumours in the spine and pelvis in adolescents: clinical and radiological features. Acta Orthop Scand 1976;47:170-4.
43. Marsh BW, Bonfiglio M, Brady LP, Enneking WF. Benign osteoblastoma: range of manifestations. J Bone Joint Surg Am 1975;57:1-9.
44. Sakellaridis T, Gaitanakis S, Piyis A. Rib tumors: a 15-year experience. Gen Thorac Cardiovasc Surg 2014;62:434-40.
45. Arikan Y, Misir A, Ozer D, et al. The incidence and distribution of primary fibula tumors and tumor-like lesions: a 35-year experience. J Orthop Surg (Hong Kong) 2018;26:2309499018798180.
46. Özkan EA, Göret CC, Özdemir ZT, et al. Pattern of primary tumors and tumor-like lesions of bone in children: retrospective survey of biopsy results. Int J Clin Exp Pathol 2015;8:11543-8.
47. Houdek MT, Sherman CE, Inwards CY, Wenger DE, Rose PS, Sim FH. Adamantinoma of bone: long-term follow-up of 46 consecutive patients. J Surg Oncol 2018;118:1150-4.
48. Nouri MM, Hashemian H. Ewing's tumor. Review of 73 cases. Int Surg 1975;60:478-81.
49. Patnaik S, Yarlagadda J, Susarla R. Imaging features of Ewing's sarcoma: special reference to uncommon features and rare sites of presentation. J Cancer Res Ther 2018;14:1014-22.
50. Motamedi K, Seeger LL. Benign bone tumors. Radiol Clin North Am 2011;49:1115-34. v.
51. Letson D, Falcone R, Muro-Cacho CA. Pathologic and radiologic features of primary bone tumors. Cancer control 1999;6:283-93.
52. Stacy GS, Dixon LB. Pitfalls in MR image interpretation prompting referrals to an orthopedic oncology clinic. Radiographics 2007;27:805-26; discussion 27-8.