DHMC Body MRI Protocol Book

Last Updated 11/28/2023

©2023 Dartmouth-Hitchcock Medical Center
The contents of DHMC's Body MRI Protocol Book may not be reproduced without permission, but we are usually able – and happy – to extend such permission.

Key Points on Using this Protocol Book

- This protocol book was built using Siemens as the main brand of machine in mind.
- The parameters listed in this book are required parameters from the radiologist. Other parameters such as matrix size, averages, and acceleration are unique and will not work the same on every brand (GE, Siemens, Philips) or strength (1.5T, 3T) of machine. It is recommended that you start with a stock sequence and adjust from this point.

BODY MRI PROTOCOLS INDEX

Abdomen		Pelvis	
Adrenal	Renal Mass	Anal Fistula	Gyn Onc BT Plan
Basic Abdomen	Urogram	Appendicitis Pregnant	Ovarian/Adnexal Mass
Dynamic Liver		Basic Pelvis	Penile
Enterography		Cervical CA Staging	Rectal Cancer
Eovist Liver		Defogram	Routine Female Pelvis
Liver for Hemochromatosis		Dynamic (Multiparametric) Prostate	RT Prostate
MRCP		Endometrial Cancer	
Pancreas / MRCP		Female Pelvis Mullerian	
Pancreas		Female Pelvis -Urethral	
MRA/MRV		**Other**	
Aorta (CAP) MRA	MRA Popliteal Entrapment	Body AVM	MRV Pelvis DVT
Mesenteric MRA	Renal MRA		

Adrenal

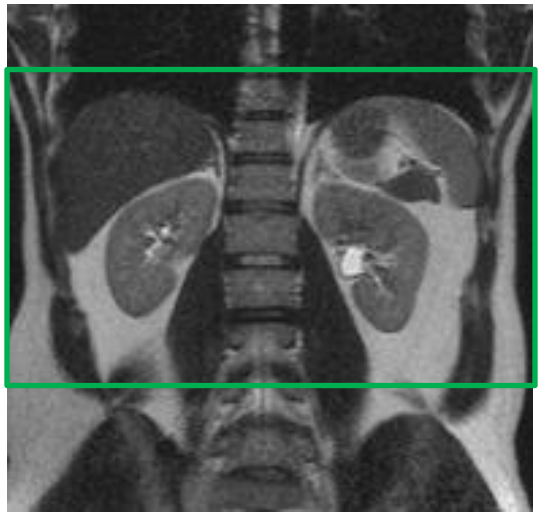

Coronal T2: diaphragm to aortic bifurcation
Axial IN/OUT PHASE Adrenals
Coronal IN/OUT PHASE Adrenals
Axial T2 FS: diaphragm to aortic bifurcation
Axial VIBE FS Pre: diaphragm to aortic bifurcation
Axial VIBE FS **Post**: diaphragm to aortic bifurcation ***Subtractions***
(35 SEC/70 SEC)
Coronal VIBE FS **Post**
(3 MIN)

Sequence	TR	TE	FOV:		Slice Thickness (mm)	Gap (mm)	Phase Direction	Scan Direction	OTHER
			Frequency	Phase %					
COR T2	1600	91	440	100	5	1	R/L	P->A	
AX IN/OUT PHASE	170	1.2/2.4 (3T) 2.2/4.4(1.5T)	380	75	4	1	A/P	S->I	
COR IN/OUT PHASE	170	1.2/2.4 (3T) 2.2/4.4(1.5T)	380	75	4	1	A/P	S->I	
AX T2 FS	1600	95	380	75	5	1	A/P	S->I	
AX VIBE FS PRE	4.3	1.8	380	80	3	0.6	A/P	S->I	
AX VIBE FS POST	4.3	1.8	380	80	3	0.6	A/P	S->I	
COR VIBE FS POST	4	1.7	400	100	3	0.6	R/L	P->A	

Basic Abdomen

(Cancer surveillance, non-specific clinical history)

Coronal T2 Abdomen
Axial In/Out Phase Abdomen
Axial T2 FS Abdomen
Axial DWI Abdomen
Axial VIBE FS Pre Abdomen
Axial VIBE FS Post Abdomen (60-70sec) ***Subtractions***
Coronal VIBE FS Post Abdomen

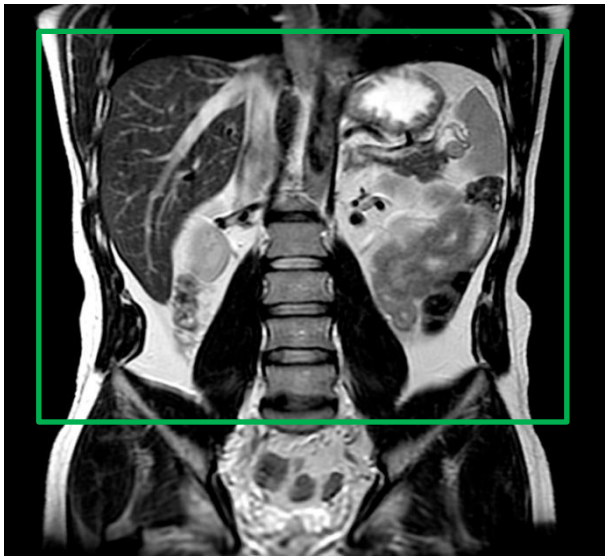

Sequence	TR	TE	FOV		SLICE	GAP	PHASE DIR	SCAN DIR	OTHER
			FREQ	PHASE					
COR T2 ABD	1400	91	440	100%	5	1	R/L	P->A	
AX IN/OUT PHASE ABD	170	1.2 and 2.4	380	80%	5	1	A/P	S->I	
AX T2 FS ABD	1600	95	380	80%	5	1	A/P	S->I	
AX DWI ABD	5800	61	380	80	5	1	A/P	S->I	B VALUE: 50/400/750
AX VIBE FS PRE ABD	4.3	1.89	380	80%	3	0.6	A/P	S->I	
AX VIBE FS POST ABD (60-70 SEC)	4.3	1.89	380	80%	3	0.6	A/P	S->I	
COR VIBE FS POST ABD	4.3	1.89	440	100%	3	0.6	R/L	P->A	

Dynamic Liver

(HCC, Cholangiocarcinoma, lesion characterization, Hypervascular metastases)

Coronal T2

Axial T2

Axial T2 FS

Axial IN/OUT PHASE

Axial VIBE FS Pre

Axial VIBE FS **Post ***Subtractions*****

(30 SEC/1 MIN/3 MIN/5 MIN)

Coronal VIBE FS **Post**

(4 MIN)

Axial DIFFUSION (b value 50, 400, and 750)

Need ADC maps

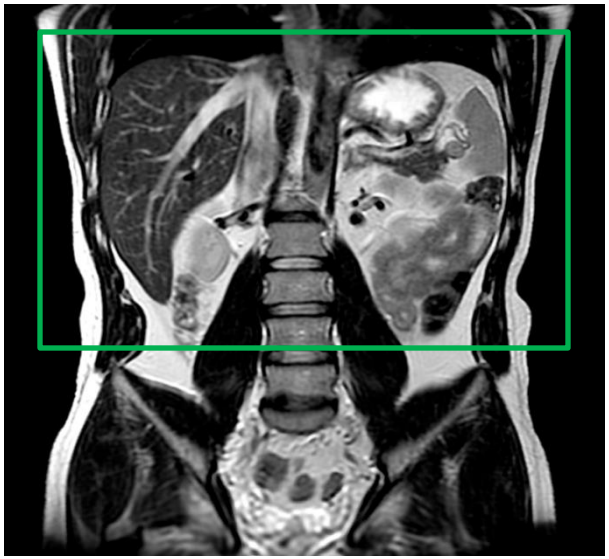

Sequence	TR	TE	FOV		Slice Thickness (mm)	Gap (mm)	Phase Direction	Scan Direction	OTHER
			Frequency	Phase %					
COR T2	1600	91	440	100	5	1	R/L	P->A	
AX T2	1600	95	380	75	5	1	A/P	S->I	
AX T2 FS	1600	95	380	75	5	1	A/P	S->I	
AX IN/OUT PHASE	170	1.2/2.4 (3T) 2.2/4.4(1.5T)	380	75	5	1	A/P	S->I	
AX VIBE FS PRE	4.3	1.8	380	80	3	0.6	A/P	S->I	
AX VIBE FS POST	4.3	1.8	380	80	3	0.6	A/P	S->I	
COR VIBE FS POST	4	1.7	400	100	3	0.6	R/L	P->A	
AX DIFFUSION	5800	61	380	80	5	1	A/P	S->I	B VALUE: 50/400/750

Enterography

Patient prep: BREEZA, 3 bottles, 90 minutes prior

Glucagon – 0.5 mg IM after CISS

Coronal T2 CISS

CHECKED BY RADIOLOGIST (SEE NOTE)

*Have RN inject glucagon

Coronal T2 BH

Axial T2 BH (Combine/Stitch if applicable)

Axial T2 FS BH (Combine/Stitch if applicable)

Axial VIBE FS Pre

Coronal VIBE FS Pre

Coronal VIBE FS **Post** (35 SEC/ 70 SEC)

*****Subtractions*****

Axial VIBE FS **Post ***Subtractions*****

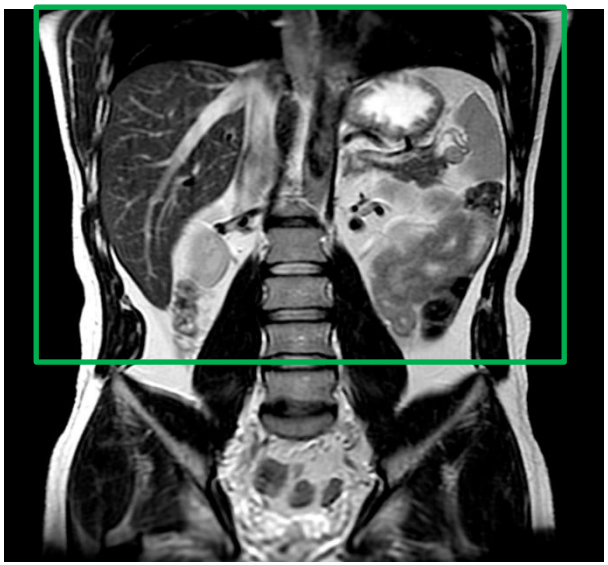

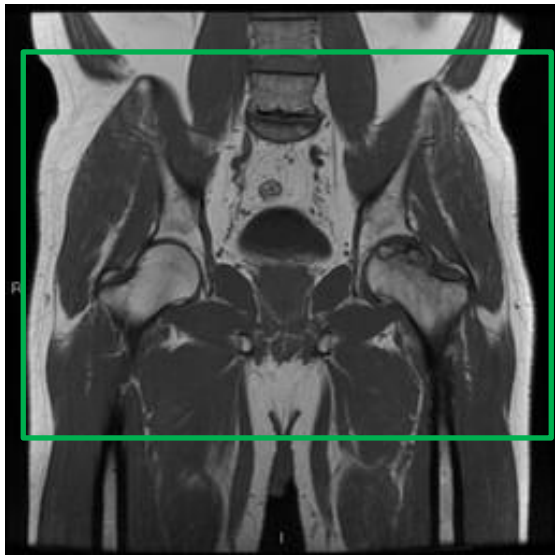

*****IF UNABLE TO READ MD AFTER 5 MINUTES, PROCEED WITH EXAM AND DOCUMENT*****

Sequence	TR	TE	FOV		SLICE	GAP	PHASE DIR	SCAN DIR	OTHER
			FREQ	PHASE					
COR T2 CISS	186	1.15	430	100	5.5	0	R->L	P->A	
*****CHECK FOR GLUCAGON*****									
COR T2	1600	91	440	100	5	1	R/L	P->A	
AX T2	1600	95	380	75	5	1	A/P	S->I	
AX T2 FS	1600	95	380	75	5	1	A/P	S->I	
AX VIBE FS PRE	4.3	1.8	380	80	3	0.6	A/P	S->I	
COR VIBE FS PRE	4	1.7	440	100	3	0.6	R/L	P->A	
COR VIBE FS POST (35 and 70 sec)	4	1.7	440	100	3	0.6	R/L	P->A	
AX VIBE FS Post	4.3	1.8	380	80	3	0.6	A/P	S->I	

Eovist Liver

(Differentiate FNH/adenoma, strongly consider for female with lesion, Hypovascular liver mets, biliary leaks)

Coronal T2

Axial IN/OUT PHASE

Axial VIBE FS Pre

Axial VIBE FS **Post** ***Subtractions***

(2 phase arterial/1 MIN/3 MIN)

Coronal VIBE FS **Post** (4 MIN)

Axial VIBE FS **Post** (5 MIN)

Axial DIFFUSION **Post** (b value 50, 400, and 750) ***Need ADC Maps***

Axial T2 **Post**

Axial T2 FS **Post**

Axial VIBE FS **Post** (20 MIN)

Coronal VIBE FS **Post** (20 MIN) ***INCLUDE SUBTRACTIONS***

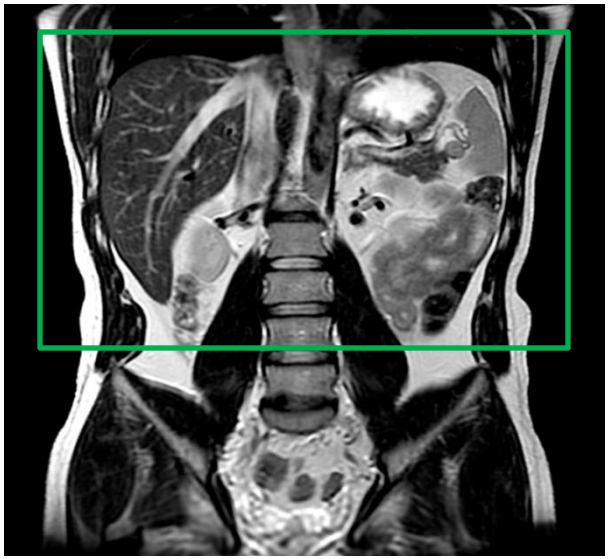

Sequence	TR	TE	FOV:		Slice Thickness (mm)	Gap (mm)	Phase Direction	Scan Direction	OTHER
			Frequency	Phase %					
COR T2	1600	91	440	100	5	1	R/L	P->A	
AX IN/OUT PHASE	170	1.2/2.4 (3T) 2.2/4.4(1.5T)	380	75	5	1	A/P	S->I	
AX VIBE FS PRE	4.3	1.8	380	80	3	0.6	A/P	S->I	
AX VIBE FS POST	4.3	1.8	380	80	3	0.6	A/P	S->I	
AX T2 Post	1600	95	380	75	5	1	A/P	S->I	
AX T2 FS Post	1600	95	380	75	5	1	A/P	S->I	
COR VIBE FS POST	4	1.7	400	100	3	0.6	R/L	P->A	
AX DIFFUSION	5800	61	380	80	5	1	A/P	S->I	B VALUE: 50/400/750

Liver for Hemochromatosis

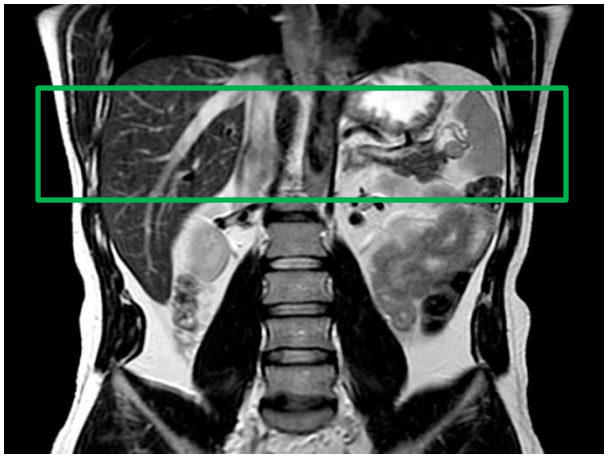

1.5T ONLY – DHMC Siemens Aera (Scanner 3) ONLY

Full abdomen/liver/spleen coverage:

Coronal T2

Axial T2

Axial IN/OUT PHASE

3-5 slices through the liver and spleen:

Axial Multi TE GRE

Coverage for **Multi TE GRE:** Limited Coverage: 3-5 slices through liver and spleen

Sequence	TR	TE	FOV		SLICE	GAP	PHASE DIR	SCAN DIR	OTHER
			FREQ	PHASE					
COR T2	1600	91	440	100%	5	1	R/L	P->A	Whole Liver Coverage
AX T2	1600	95	380	75%	5	1	A/P	S->I	
AX IN/OUT PHASE	170	1.2/2.4 (3T) 2.2/4.4(1.5T)	380	75	5	1	A/P	S->I	
AX Multi TE GRE	120	*Multi TE Values	380	85%	10	2	A/P	S->I	Limited Coverage – 3-5 slices through liver and spleen

MRCP

Patient prep: NPO 4 hours prior. Arrive 20-30 min early for 6 oz's of PO pineapple juice

Coronal T2

Axial T2

Thick Slab SSFSE – 3 Oblique planes through pancreas/CBD/GB 40mm Thick

Coronal 3D Volume Respiratory Triggered MRCP *

1. Thin Coronal MIP images created at 1.6/0.8
2. Thin Axial MIP images created at 1.6/0.8

*Do breath hold Coronal 3D acquisition if the respiratory triggered is poor

IF SECRETIN EXAM:

*SECRETIN**:** **ADULT**: 0.2µg/kg IV slowly pushed over 1 minute

PEDIATRIC: 0.2µg/kg (MAX DOSE 16 µg)

*ADMINISTERED BY ANGIO RN – IV PUSH

THICK SLAB SSFSE THROUGH PLANE OF PANCREATIC DUCT EVERY MINUTE FOR 10 MINUTES (STACKED)

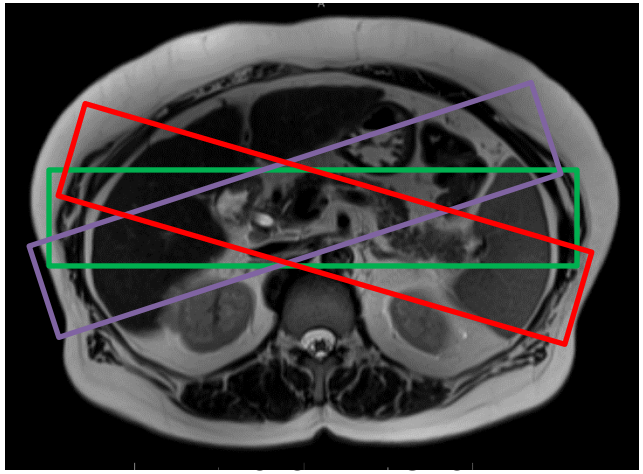

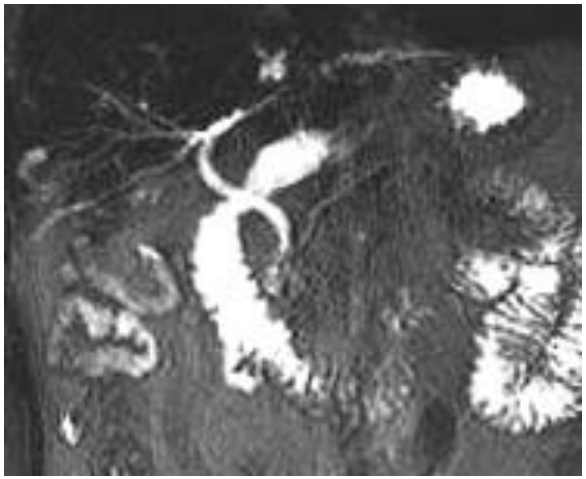

THICK SLAB:
Coronal and Coronal Oblique x2

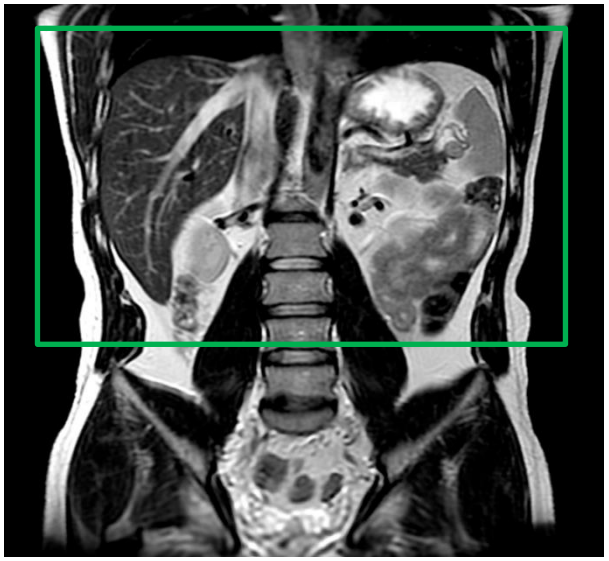

Axial Coverage

MRCP continued

Sequence	TR	TE	FOV:		Slice Thickness (mm)	Gap (mm)	Phase Direction	Scan Direction	OTHER
			Frequency	Phase %					
COR T2	1600	91	440	100	5	1	R/L	P->A	
AX T2	1600	95	380	75	5	1	A/P	S->I	
COR THICK SLAB	4500	735	300	100	50	25	L/R	P->A	
COR OBLIQ SLAB 1	4500	735	300	100	50	25	L/R	P->A	
COR OBLIQ SLAB 2	4500	735	300	100	50	25	L/R	P->A	
COR 3D RESP TRIGGERED	5800	698	380	100	1	0	R/L	P->A	
COR 3D BREATH HOLD	2000	697	380	100	1	.5	R/L	P->A	
*****IF SECRETIN USED*****									
COR THK SLAB POST SECRETIN	4500	735	300	100	50	25	P/A	P->A	RUN X 10

Pancreas / MRCP

Patient prep: NPO 4 hours prior. Arrive 20-30 min early for 6oz's of PO pineapple juice

Coronal T2 FS

Axial T2

Axial T2 FS Thin Pancreas ONLY

Axial IN/OUT PHASE

Thick Slab SSFSE – 3 Oblique planes through pancreas/CBD/GB 40mm Thick

Coronal 3D Volume Respiratory Triggered MRCP *

1. Thin Coronal MIP images created at 1.6/0.8
2. Thin Axial MIP images created at 1.6/0.8

*Do breath hold Coronal 3D acquisition if the respiratory triggered is poor

Axial VIBE FS Pre

Axial VIBE FS **Post** (35 SEC/70 SEC/3 MIN) ***Subtractions***

Coronal VIBE FS **Post** (3 MIN)

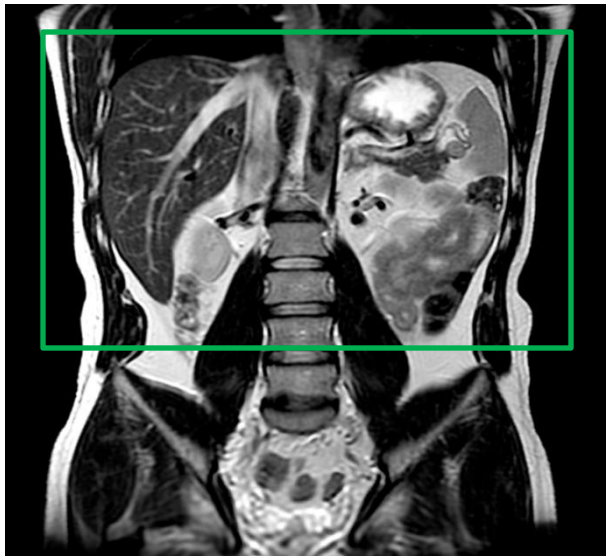

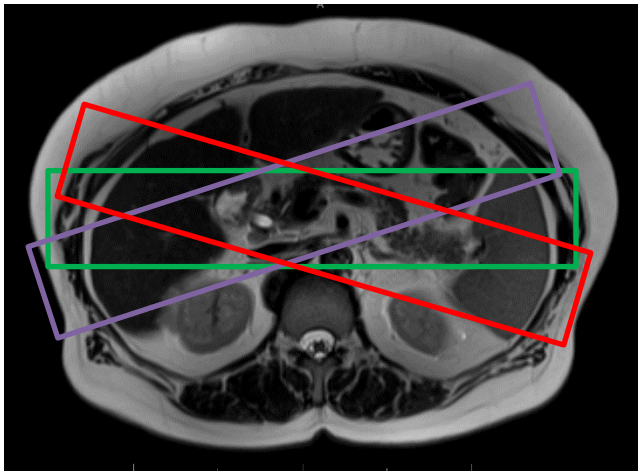

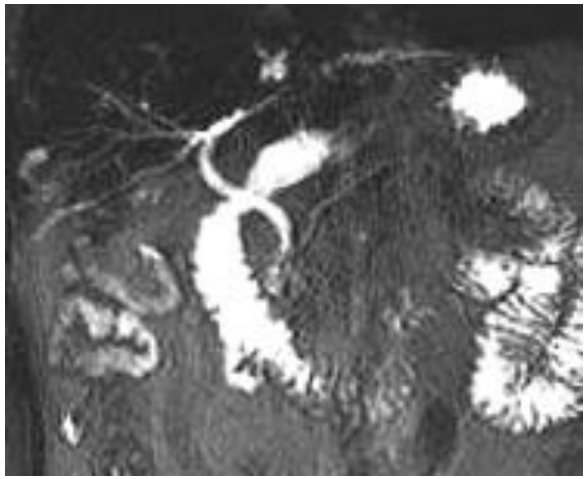

THICK SLAB:
Coronal and Coronal Oblique x2

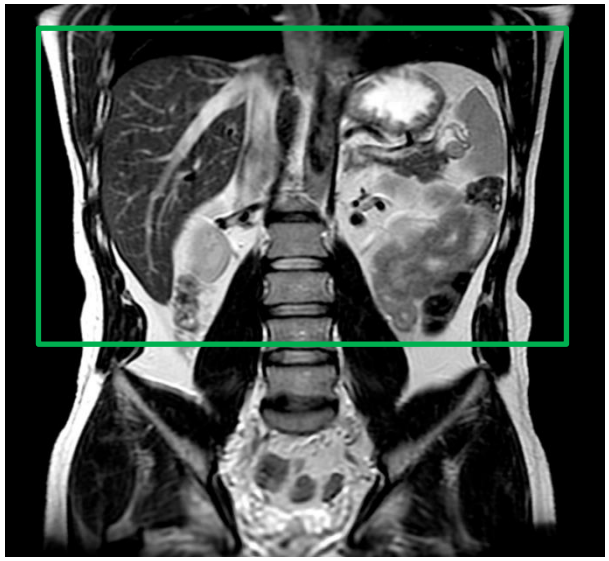

Axial Coverage

Pancreas / MRCP Continued

Sequence	TR	TE	FOV:		Slice Thickness (mm)	Gap (mm)	Phase Direction	Scan Direction	OTHER
			Frequency	Phase %					
COR T2 FS	1600	91	440	100	5	1	R/L	P->A	
AXIAL T2	1600	95	380	75	5	1	A/P	S->I	
AX T2 FS Thin	1600	95	380	75	3	1	A/P	S->I	Pancreas Only
AX IN/OUT PHASE	170	1.2/2.4 (3T) 2.2/4.4(1.5T)	380	75	5	1	A/P	S->I	
AX VIBE FS PRE	4.3	1.8	380	80	3	0.6	A/P	S->I	
COR THICK SLAB	4500	735	300	100	50	25	L/R	P->A	
COR OBLIQ SLAB 1	4500	735	300	100	50	25	L/R	P->A	
COR OBLIQ SLAB 2	4500	735	300	100	50	25	L/R	P->A	
COR 3D RESP TRIGGERED	5800	698	380	100	1	0	R/L	P->A	
COR 3D BREATH HOLD	2000	697	380	100	1	.5	R/L	P->A	
AX VIBE FS POST	4.3	1.8	380	80	3	0.6	A/P	S->I	
COR VIBE FS POST	4	1.7	400	100	3	0.6	R/L	P->A	

Pancreas

(Tumors, staging, follow up cystic lesions, Pancreatitis)

Patient Prep: NPO for 4 hours, If MRCP NOT requested, 24oz's of water (PO) 30 min. prior

Coronal T2 FS

Axial T2

Coronal T2 Thin Pancreas ONLY

Axial T2 FS Thin Pancreas ONLY

Axial IN/OUT PHASE

Axial VIBE FS Pre

Axial VIBE FS **Post** (35 SEC/70 SEC/3 MIN) ***Subtractions***

Coronal VIBE FS **Post** (3 MIN)

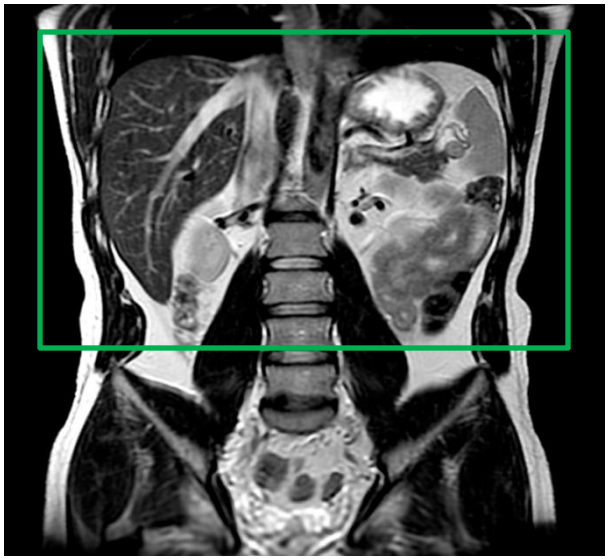

Sequence	TR	TE	FOV:		Slice Thickness (mm)	Gap (mm)	Phase Direction	Scan Direction	OTHER
			Frequency	Phase %					
COR T2 FS	1600	91	440	100	5	1	R/L	P->A	
AX T2	1600	95	380	75	5	1	A/P	S->I	
COR T2 Thin	1600	91	440	100	3	1	R/L	P->A	Pancreas ONLY
AX T2 FS Thin	1600	95	380	75	3	1	A/P	S->I	
AX IN/OUT PHASE	170	1.2/2.4 (3T) 2.2/4.4(1.5T)	380	75	5	1	A/P	S->I	
AX VIBE FS PRE	4.3	1.8	380	80	3	0.6	A/P	S->I	
AX VIBE FS POST	4.3	1.8	380	80	3	0.6	A/P	S->I	
COR VIBE FS POST	4	1.7	400	100	3	0.6	R/L	P->A	

Renal Mass

FOV limited to kidneys

Coronal T2

Axial T2

Axial T2 FS

Axial IN/OUT PHASE

Axial VIBE FS Pre

Coronal VIBE FS Pre

Coronal VIBE FS **Post ***Subtractions*****

(25 SEC/90 SEC/3 MIN) *with subtractions

Axial VIBE FS MIN **Post ***Subtractions*****

Axial DIFFUSION (b value of 50 and 800) and ADC maps

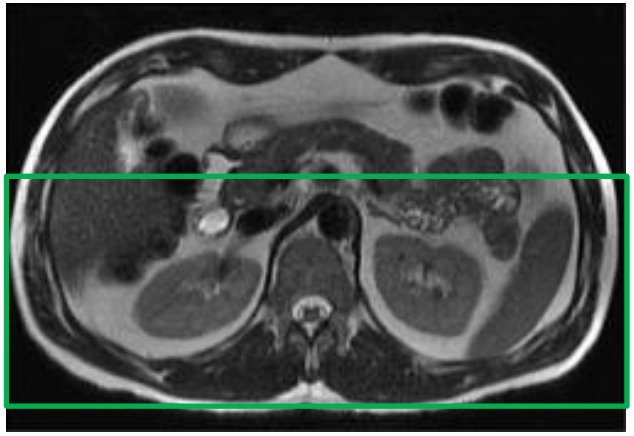

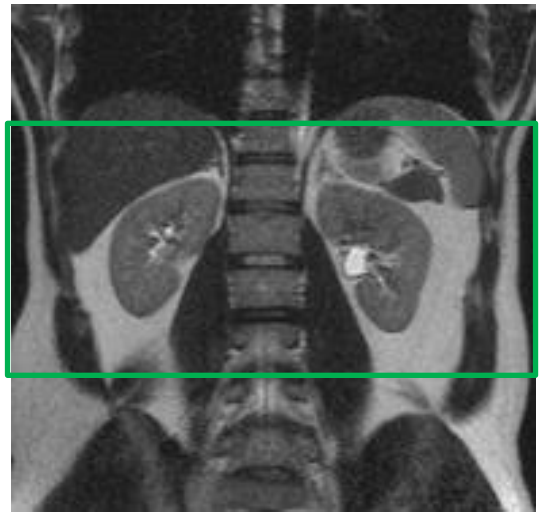

Sequence	TR	TE	FOV:		Slice Thickness (mm)	Gap (mm)	Phase Direction	Scan Direction	OTHER
			Frequency	Phase %					
COR T2	1600	91	440	100	5	1	R/L	P->A	
AXIAL T2	1600	95	380	75	5	1	A/P	S->I	
AXIAL T2 FS	1600	95	380	75	5	1	A/P	S->I	
AXIAL IN/OUT PHASE	170	1.2/2.4 (3T) 2.2/4.4(1.5T)	380	75	5	1	A/P	S->I	
AXIAL VIBE FS PRE	4.3	1.8	380	80	3	0.6	A/P	S->I	
COR VIBE FS PRE	4.3	1.8	380	80	3	0.6	A/P	S->I	
COR VIBE FS POST	4.3	1.8	380	80	3	0.6	R/L	P->A	
AX VIBE FS POST	4	1.7	400	100	3	0.6	A/P	S->I	
AXIAL DIFFUSION	5800	61	380	80	5	1	A/P	S->I	B VALUE: 50/800

Urogram

Patient Prep: Arrive 1 hour prior to get IVF

Empty bladder prior to getting on table

Adult: 500mL NS bolus immediately before scan

Pediatric: weight based IVF:

4mL/kg/hr. 1st 10kg

2mL/kg/hr. next 10kg

1mL/kg/hr. for each kg above 20kg

Blood Pressure needs to be taken and document in EPIC before and after Lasix Injection

Adults: arrive 1 hour prior to angio for IV placement, fluids, possible catheter placement (optional)

**Lasix dose: 20-40mg slow IV push*

Pediatrics: Requires Pain Free and catheter (can administer Lasix)

**Lasix dose: 1mg/kg (up to max dose 20mg) slow IV push*

Coronal T2 Abdomen/Pelvis

Axial T2 Abdomen/Pelvis

Axial T2 FS Abdomen/Pelvis

Sagittal T2 FS Abdomen/Pelvis

Inject Lasix

Coronal T2 Thick Slab (straight coronal)

Coronal T2 Thin (1mm) Respiratory Triggered Kidneys/Ureters

Axial VIBE FS Pre-Abdomen/Pelvis

Coronal VIBE FS Pre

Coronal VIBE FS **Post ***Subtractions*****

- Coronal oblique plane to include kidneys and bladder (2mm slice thickness)
- Arterial (~30 sec), 100 SEC (nephrographic), 8 MIN (excretory)
- Automatic MIP images of each volume acquired

Axial VIBE FS **Post ***Subtractions*****

- 6 MIN (Between 100 SEC and 8 MIN Coronal Vibes)

Sagittal VIBE FS **Post** 10 MIN (need to see ureters to bladder)

Urogram continued

Sequence	TR	TE	FOV:		Slice Thickness (mm)	Gap (mm)	Phase Direction	Scan Direction	OTHER
			Frequency	Phase %					
COR T2	1600	91	440	100	5	1	R/L	P->A	
AXIAL T1 FS	572	20	380	75	5	1	A/P	S->I	
AXIAL T2	1600	95	380	75	5	1	A/P	S->I	
AXIAL T2 FS	1600	95	380	75	5	1	A/P	S->I	
SAGITTAL T2 FS	1600	95	380	75	5	1	A/P	L->R	
COR T2 THK Slabs	4500	564	420	80	50	0	R/L	P->A	Straight Coronal
COR T2 Thin RESP TRIG	2400	698	380	100	1.0		R/L	P->A	
AXIAL VIBE FS PRE Post	4.3	1.8	380	80	3	0.6	A/P	S->I	
COR VIBE FS PRE 30 SEC (Arterial), 100 SEC (Nephrographic), 8 MIN (Excretory)	4.3	1.8	400	80	2	0.4	R/L	P->A	
SAG VIBE FS POST	4.3	1.8	400	80	2	0.4	R/L	P->A	

Anal Fistula (3T ONLY)

Sagittal T2 (Full FOV, 2.5mm/gap 0mm)

*Use to establish oblique planes –

Axial and coronal to long axis of anal canal

MD to check planes if unsure

Small FOV (26cm):

Axial Oblique T1 (4mm/0.8)

Axial Oblique T2 FS (4mm/0.8)

Axial Oblique T2 (4mm/0.8)

Axial DWI Resolve OBL (B-Values 100, 500, 800), ADC Maps

Coronal Oblique T2 FS (4mm/0.8)

Coronal Oblique T2 (4mm/0.8)

Axial Oblique VIBE FS Pre

Axial Oblique VIBE FS **Post ***Subtractions*****

Coronal Oblique VIBE FS **Post**

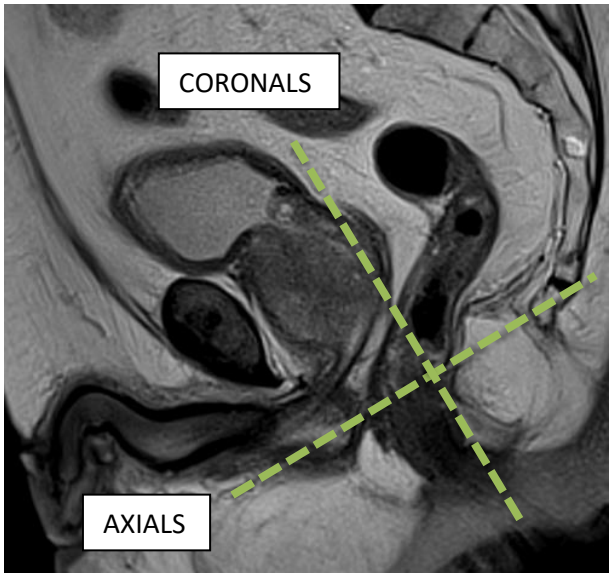

Sequence	TR	TE	FOV:		Slice Thickness (mm)	Gap (mm)	Phase Direction	Scan Direction	OTHER
			Frequency	Phase %					
SAG T2	2570	92	300	100	2.5	0	S/I	L->R	*Coverage should include the entire anal canal through the soft tissue of the buttocks*
AXIAL OBL T1	527	20	260	100	4	0.8	R/L	S->I	
AXIAL OBL T2 FS	3000	86	260	100	4	0.8	R/L	S->I	
AXIAL OBL T2	3000	86	260	100	4	0.8	R/L	S->I	
AX DWI-RESOLVE OBL	8500	99	300	100	3	0	A/P	S->I	
COR OBL T2 FS	3000	86	260	100	4	0.8	R/L	P->A	
COR OBL T2	3000	86	260	100	4	0.8	R/L	P->A	
AX VIBE FS PRE	7.4	3.8	260	80	3	0.6	A/P	S->I	
AX VIBE FS POST	7.4	3.8	260	80	3	0.6	A/P	S->I	
COR VIBE FS POST	7.2	3.8	260	100	3	0.6	R/L	P->A	

Appendicitis Pregnant

(R/O APPENDICITIS)

Coronal T2 SSFSE

Axial T2 SSFSE

Sagittal T2 SSFSE

Coronal T2 FS BH

Axial T2 FS BH

Coronal CISS

Axial CISS (Optional if questioning a kidney stone)

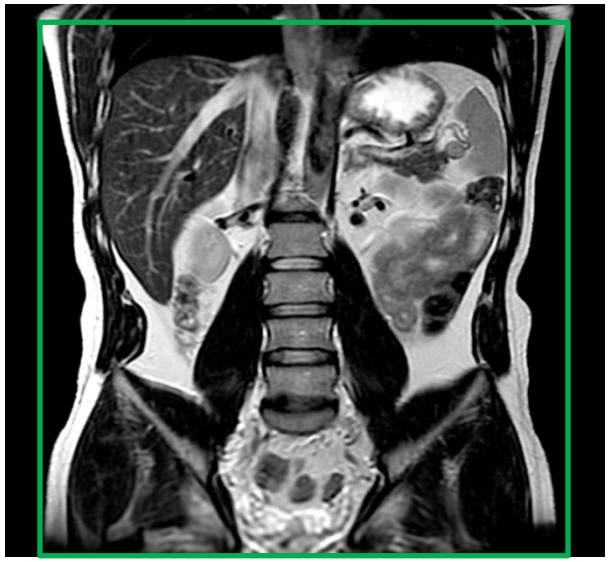

Sequence	TR	TE	FOV:		Slice Thickness (mm)	Gap (mm)	Phase Direction	Scan Direction	OTHER
			Frequency	Phase %					
COR T2 SSFSE	1600	132	440	100	3	0.3	R/L	P->A	
AX T2 SSFSE	1600	132	380	75	3	0.3	A/P	S->I	
SAG T2 SSFSE	1600	132	440	100	6	1	A/P	L->R	
COR T2 FS BH	1600	132	380	194	3	0.3	R/L	P->A	
AX T2 FS	1600	135	380	75	3	0.3	A/P	S->I	
COR CISS	191	1.18	400	100	8	2	R/L	P->A	
AX CISS	191	1.18	400	100	8	2	A/P	S->I	

Basic Pelvis

(Cancer surveillance, non-specific clinical history)

Coronal T2 Pelvis

Axial DWI Pelvis

Axial Stir Pelvis

Axial VIBE FS Pre Pelvis

Axial VIBE FS **Post** Pelvis ***Subtractions***

Coronal VIBE FS **Post** Pelvis

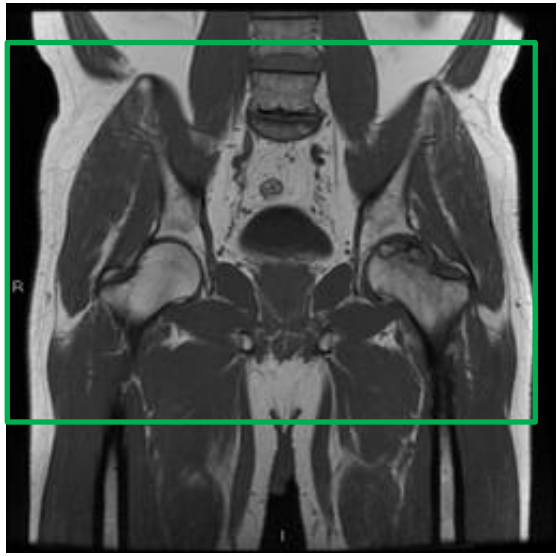

Sequence	TR	TE	FOV		SLICE	GAP	PHASE DIR	SCAN DIR	OTHER
			FREQ	PHASE					
COR T2 PELVIS	1400	91	440	100%	5	1	R/L	P->A	
AXIAL DWI PELVIS	5800	61	380	80	5	1	A/P	S->I	B VALUE: 50/400/750
AX STIR PELVIS	3500	95	380	80%	5	1	A/P	S->I	
AX VIBE FS Pre PELVIS	4.3	1.89	380	80%	3	0.6	A/P	S->I	
AX VIBE FS POST PELVIS	4.3	1.89	380	80%	3	0.6	A/P	S->I	
COR VIBE FS POST PEL	4.3	1.89	440	100%	3	0.6	R/L	P->A	

Cervical Cancer Staging (3T Preferred)

Please have patient evacuate bladder and rectum immediately prior to starting MRI

Please call body radiologist for selection of *planes for small FOV axial images in relation to the cervix UNLESS they have had priors, then copy angles from previous exam*

Coronal T2 SSFSE (Pelvis)

Sagittal T2 (acetabulum to acetabulum)

Axial Oblique T2

Axial Oblique DWI Resolve

Axial T1 (Large FOV – top of L5 through perineum)

Sagittal VIBE Pre (acetabulum to acetabulum)

IF CONTRAST

Axial VIBE **Pre**

Axial VIBE **Post ***Subtractions*****

Sagittal VIBE **Post**

Optional Axial T2 FS (Large FOV – top of L5 through perineum)

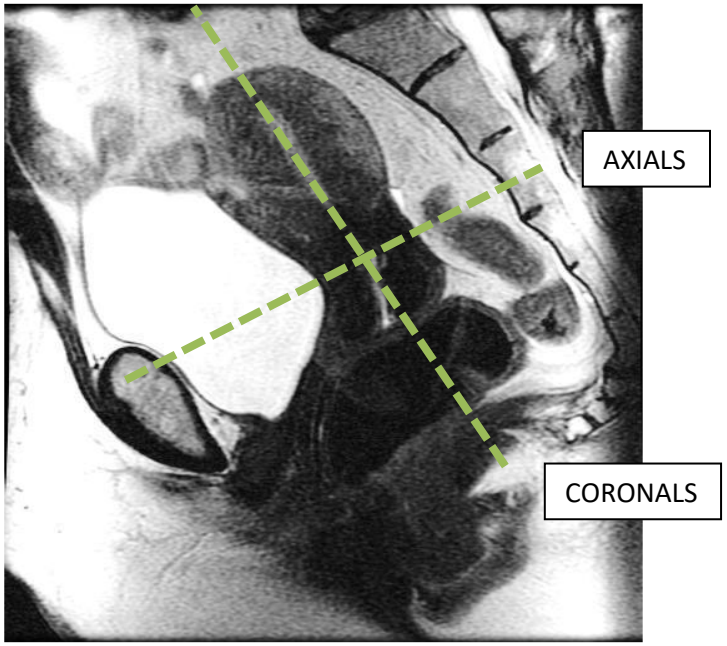

Dashed white line parallel to the long axis of the cervix on sagittal image. Solid white lines are the axial oblique scan plane, perpendicular to the long axis of the cervix.

Sequence	TR	TE	FOV:		Slice Thickness (mm)	Gap (mm)	Phase Direction	Scan Direction	OTHER
			Frequency	Phase %					
Coronal T2	1400	91	400	100	6	1	R/L	P->A	Pelvis
Sag T2	5000	91	200	100	4	1	S/I	L->R	
Ax Oblique	5000	91	200	100	3	0.5	A/P	S->I	
Ax Obl. Resolve	8500	91	200	100	3	0.5	A/P	S->I	b values 100, 500, and 800
Ax T1	500	11	320	100	5	1	R/L	S->I	
Sag VIBE Pre/Post	4.51	2.19	280	100	4	0.2	S/I	L->R	
Ax VIBE Pre/Post	4.51	2.19	280	100	4	0.2	R/L	S->I	
***Optional Ax T2 FS**	3000	90	320	100	4	0.5	R/L	S->I	

Defogram

Ax T2 Small FOV

Parallel to the line formed from the Anorectal angle to the symphysis

Insert rectal gel:

Axial T2

Sagittal T2 to obtain midline

Sagittal CISS at Rest

Sagittal CISS with Kegel

Sagittal CISS with moderate straining

Sagittal CISS with defecation x 3 attempts

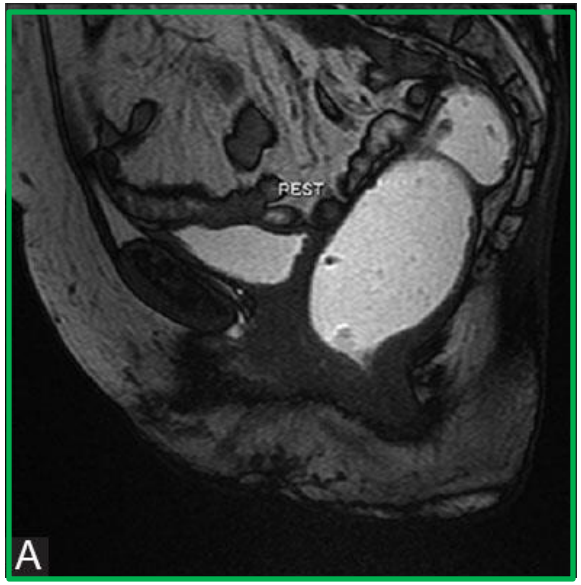

SAG CISS FOV

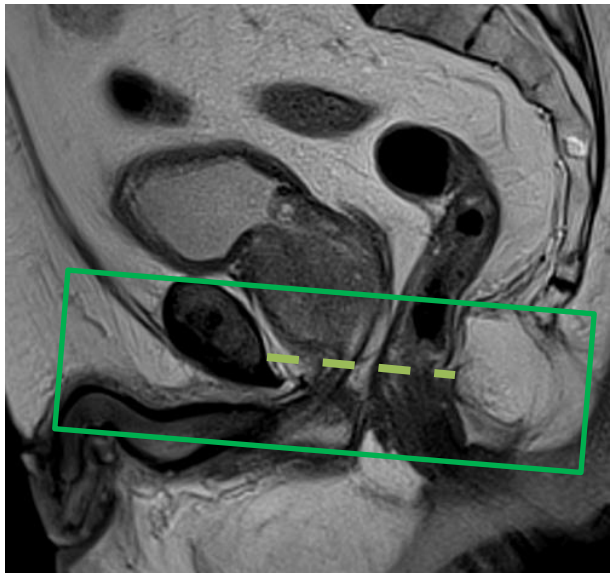

AX T2 Small FOV

Sequence	TR	TE	FOV:		Slice Thickness (mm)	Gap (mm)	Phase Direction	Scan Direction	OTHER
			Frequency	Phase %					
Ax T2 SM FOV	3100	91	200	100	3	0	A/P	S->I	Scanned prior to insertion of rectal gel
AX T2	1600	95	380	75	5	1	A/P	S->I	With gel
SAG T2	1400	91	360	100	5	1	S/I	L->R	With gel
SAG CISS (X4)	3.89	1.7	306	100	7	1	S/I	L->R	With gel 1 slice at midline

Multiparametric Prostate

Elevated PSA, negative biopsy, staging cancer

Must be done on 3T/phased array body coil

Cover entire prostate and seminal vesicles

Axial T1 (Pelvis FOV, Aortic Bifurcation-Prostate)

Axial DWI Resolve OBL (B-Values 100, 500, 800), ADC Maps

Axial T2 OBL

Sagittal T2

Coronal T2 OBL

Axial Vibe Dynamic OBL **Post** (With Subtractions)

Axial Vibe FS **Post** (Pelvis FOV)

*****Axials should cover through Seminal Vesicles Superiorly*****

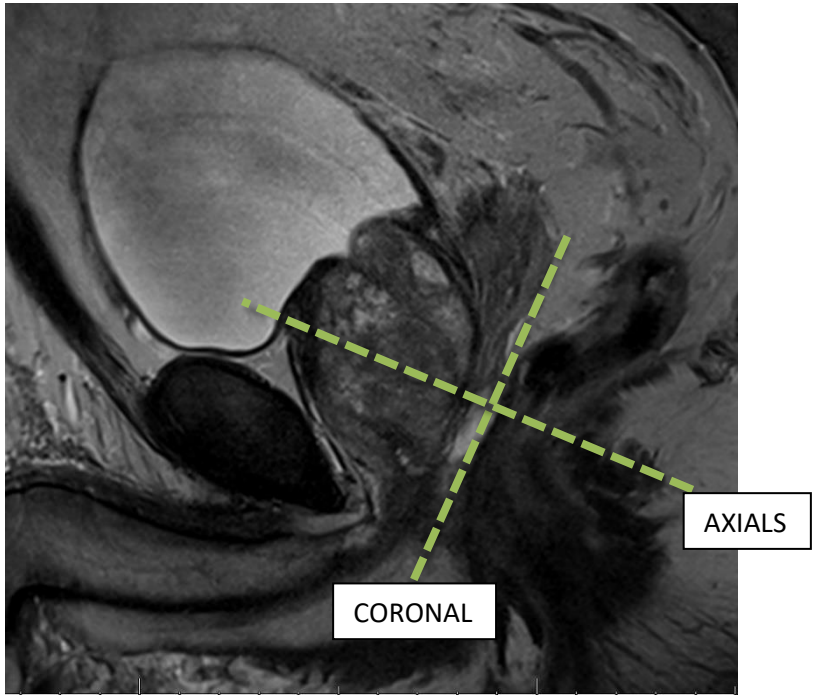

Axial plain is perpendicular to anterior wall of rectum.
Coronal plain is parallel to anterior wall of rectum.

Sequence	TR	TE	FOV:		Slice Thickness (mm)	Gap (mm)	Phase Direction	Scan Direction	OTHER
			Frequency	Phase %					
AX T1	650	10	300	100	5	1	R/L	S->I	Pelvis FOV
AX DWI-RESOLVE OBL	8500	99	300	100	3	0	A/P	S->I	b values 100, 500, and 800
AX T2 OBL	3100	91	200	100	3	0	R/L	S->I	
SAG T2	3100	91	200	100	3	0	H/F	L->R	
COR T2 OBL	3100	91	220	100	3	0	R/L	P->A	
AX Vibe Dynamic OBL Post	4.72	1.86	260	260	3	1	R/L	S->I	20 Measurements
AX Vibe FS Post	4.3	1.8	380	80	3	0.6	A/P	S->I	Pelvis FOV

Endometrial Cancer

Planes for small FOV axial/coronal images in relation to the uterus

Large FOV:

- Axial T1 Pelvis full FOV
- Axial T2 FS Pelvis full FOV

Small FOV:

- Sagittal T2 Small FOV
- Axial OBL (SAX of the uterus) T2
- Axial DWI Resolve OBL (B-Values 100, 500, 800), ADC Maps
- Axial OBL (SAX of the uterus) VIBE FS Pre
- Sagittal VIBE FS Pre
- Sagittal VIBE FS **Post** (1 MIN/3 MIN/5 MIN) ***Subtractions***
- Axial OBL (SAX) VIBE FS **Post** (4 MIN) ***Subtractions***

Axial Oblique - *Short axis to the uterus*

Sequence	TR	TE	FOV:		Slice Thickness (mm)	Gap (mm)	Phase Direction	Scan Direction	OTHER
			Frequency	Phase %					
AX T1	4.30	1.89	380	81	3		A/P	S->I	Full Pelvis
AX T2 FS	3450	96	300	100	5	1	A/P	S->I	Full Pelvis
SAG T2	500	96	220	100	5	1	A/P	L->R	
AX OBL (SAX) T2	4900	96	200	100	5	1	R/L	S->I	
AX DWI-RESOLVE OBL	8500	99	300	100	3	0	A/P	S->I	b values 100, 500, and 800
AX OBL (SAX) VIBE FS PRE	4.3	2.08	240	100	3	0.6	R/L	S->I	
SAG VIBE FS PRE	4.51	2.19	240	81	3	0.6	A/P	L->R	
SAG VIBE FS POST	4.51	2.19	240	81	3	0.6	A/P	L->R	
AX OBL (SAX) VIBE FS PRE	4.3	2.08	240	100	3	0.6	R/L	S->I	

Female Pelvis Mullerian

CALL RADIOLOGIST TO CHECK ANGLES FOR SCANNING

Axial T2 FS Full FOV
Axial T1 Full FOV
Coronal T2 Full FOV to include kidneys (7mm slice)
Sagittal T2 LG FOV (Pelvic Ring Side-Side) - Used for angle setup
Small FOV in relation to the UTERUS ONLY:
- Sagittal T2 THN (2.5mm slice)
- Axial T2 THN (2.5mm slice)
- Coronal T2 THN (2.5mm slice)

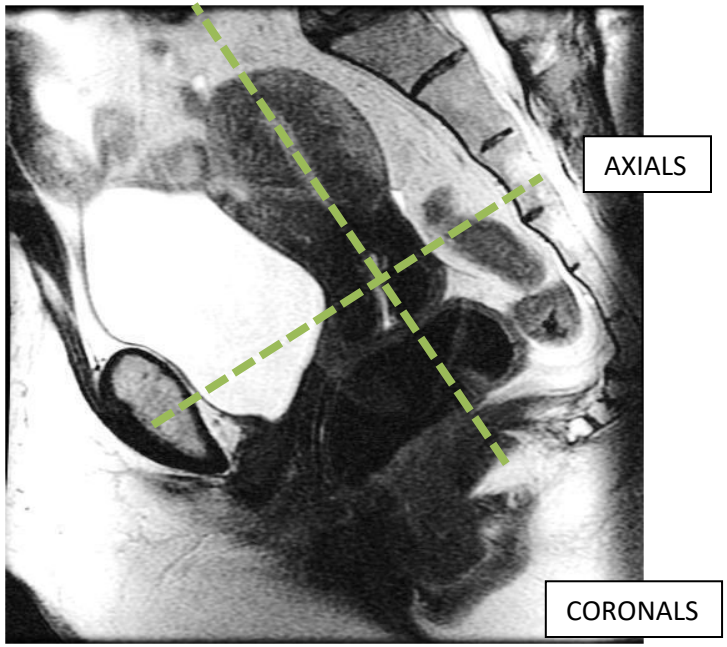

Sequence	TR	TE	FOV		Slice Thickness (mm)	Gap (mm)	Phase Direction	Scan Direction	OTHER
			Frequency	Phase %					
AX T2 FS	3450	96	300	100	5	1	A/P	S->I	Whole Pelvis
AX T1	455	20	300	100	5	1	A/P	S->I	
COR T2	1400	91	440	100	5	1	S/I	P->A	Full FOV
SAG T2	2800	101	250	100	4	1	S/I	L->R	LG FOV
SAG T2 THN	4960	91	220	100	2.5	.5	S/I	L->R	UTERUS ONLY
AX T2 THN	4960	91	200	100	2.5	.5	A/P	S->I	UTERUS ONLY
COR T2 THN	4960	91	200	100	2.5	.5	S/I	P->A	UTERUS ONLY

Female Pelvis - Urethral

Coronal T2 (wide FOV to include kidneys)

Small FOV (18cm-24cm) centered at urethra:

- Axial T2 FS (Perpendicular to urethra)
- Sagittal T2 FS
- Coronal T2 FS (Parallel to urethra)
- Axial VIBE FS Pre
- Axial VIBE FS **Post ***Subtractions*****
- Sagittal VIBE FS **Post**
- Coronal VIBE FS **Post**

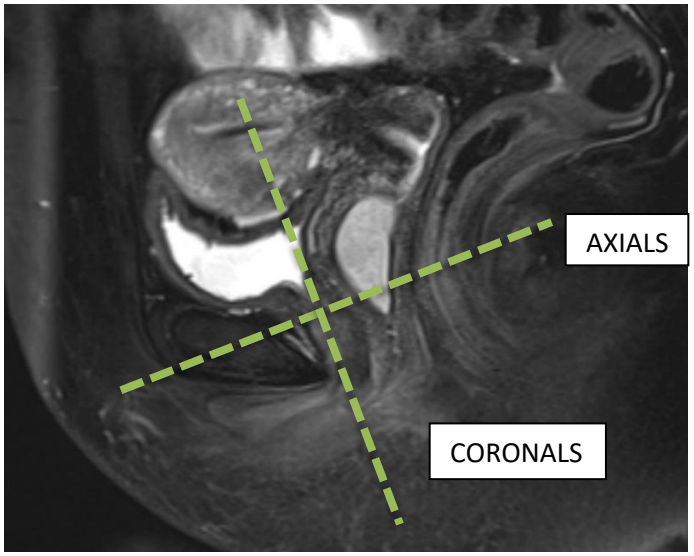

Sequence	TR	TE	FOV:		Slice Thickness (mm)	Gap (mm)	Phase Direction	Scan Direction	OTHER
			Frequency	Phase %					
COR T2	1800	95	440	100	5	1	R/L	P->A	Full FOV
AXIAL T2 FS	3000	91	200	100	3	1	R/L	S->I	
SAG T2 FS	3000	86	220	100	3	1	A/P	L->R	
COR T2 FS	3000	86	220	100	3	1	R/L	P->A	
AXIAL VIBE FS PRE	4.8	2.19	240	100	3		A/P	S->I	
AXIAL VIBE FS POST	4.8	2.19	240	100	3		A/P	S->I	
SAG VIBE FS POST	3.19	1.46	240	100	2		A/P	L->R	
COR VIBE FS POST	3.19	1.46	240	100	2		R/L	P->A	

Gyn Onc BT Plan (1.5T DHMC ONLY)

Please call body radiologist for selection of *planes for small FOV axial images in relation to the cervix UNLESS, patients has priors, then copy angles from previous exam*

LARGE FOV to Include Kidneys

Coronal T2

PELVIS FOV (L4/L5 thru Vagina)

Axial T1 Pelvis

Axial T1 Flair Pelvis

Axial T2 Pelvis

SMALL FOV Relative to Cervix

Sagittal T2

Axial Obl. T2

Coronal Obl. T2

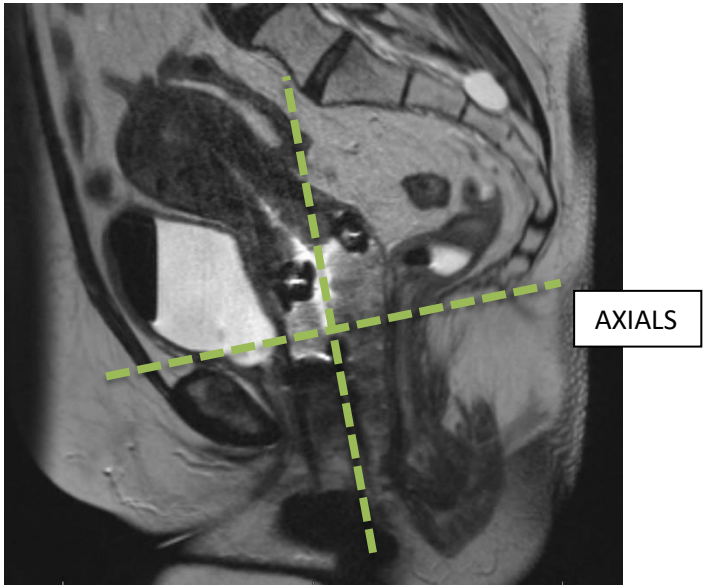

Axial plane is perpendicular to the implanted device, while the coronal plane is parallel.

Sequence	TR	TE	FOV:		Slice Thickness (mm)	Gap (mm)	CORONALS		OTHER
			Frequency	Phase %			Phase Direction	Scan Direction	
COR T2	2000-6000	80-120	400	100	6	1	R/L	P->A	Include Kidneys
AX T1	400-600	10-30	400	100	6	1	A/P	S->I	Pelvis FOV
AX T1 Flair	1576	91	400	100	6	1	A/P	S->I	Pelvis FOV
AX T2	2000-6000	80-120	400	100	5	1	A/P	S->I	Pelvis FOV
SAG T2	2000-6000	80-120	280	100	3	0.5	S/I	L->R	CERVIX FOV
AX OBL T2	2000-6000	80-120	280	100	2.8	0.5	A/P	S->I	CERVIX FOV
COR OBL T2	2000-6000	80-120	280	100	3	0.5	R/L	P->A	CERVIX FOV

Ovarian Mass (Siemens ONLY)

Planes in relation to the pelvis unless otherwise specified.

Coronal T2

Sagittal T2

Axial T2

Axial DWI Resolve

Axial T1 Dixon

Axial Dynamic **Post**

Sag Vibe FS **Post**

Axial Vibe FS **Post** (Whole Pelvis)

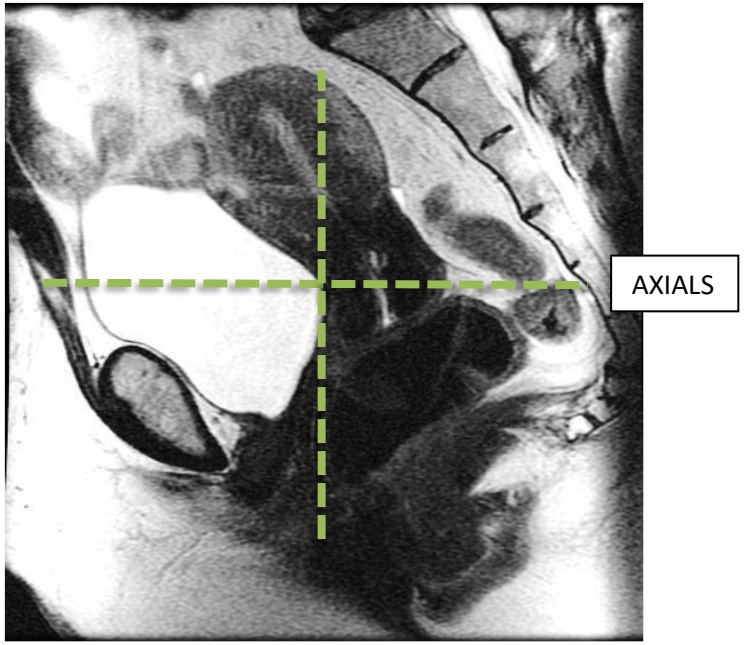

Sequence	TR	TE	FOV:		Slice Thickness (mm)	Gap (mm)	Phase Direction	Scan Direction	Scan Direction
			Frequency	Phase %					
COR T2	3100	91	220	100	3	0	R/L	P->A	
SAG T2	3100	91	200	100	3	0	H/F	R->L	
AX T2	3100	91	200	100	3	0	R/L	S->I	
DWI -RESOLVE	8500	99	300	100	3	0	A/P	S->I	
AX T1 DIXON	9.53	2.39	200	100	3	0	R/L	S->I	
Dynamic Ax Post	4.72	1.86	260	260	3	1	R/l	S->I	
SAG VIBE FS Post	4.51	2.19	240	81	3	0.6	H/F	L->R	
AX VIBE FS Post (WHOLE PELVIS)	8.87	4.77	340	100	3	0.6	R/L	S->I	Whole Pelvis

Penile (3T ONLY)

Axial T1 Large FOV
Axial T2 Small FOV
Sagittal T2 Small FOV
Coronal T2 Small FOV
Axial T2 FS Small FOV
Axial T1 In/Out Phase
Axial DWI
Axial VIBE FS Pre
Axial VIBE FS **Post**
*****Subtractions*****
Sagittal VIBE FS **Post**

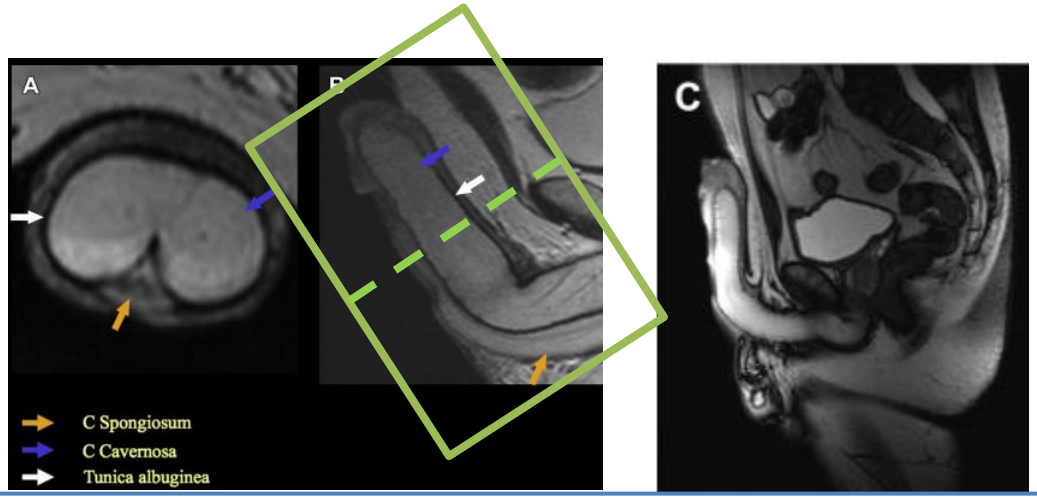

Patient positioning: Patient is imaged in a supine position. To elevate the scrotum and penis, a folded towel is placed between the patient's legs. The penis is taped to the abdomen in a dorsi-flexed position to prevent movement and pulsation artifacts. A surface coil is placed on the penis to improve signal-to-noise ratio. **Small FOV Imaging planes are in axis with the penis.**

Sequence	TR	TE	FOV:		Slice Thickness (mm)	Gap (mm)	Phase Direction	Scan Direction	OTHER
			Frequency	Phase %					
AX T1	400	11	340	100	5	1	A/P	S->I	LG FOV – Axial to the body
AXIAL T2	3000	91	160	100	4	0.5	R/L	S->I	SM FOV Angled to the axis of the penis (Interpolation or Zip512)
SAG T2	3000	86	160	100	4	0.5	A/P	L->R	
COR T2	3000	86	160	100	4	0.5	S/I	P->A	
AX T2 FS	3000	91	160	100	4	0.5	R/L	S->I	
Ax In/Out Phase	170	1.2/2.4 (3T) 2.2/4.4(1.5T)	340	100	4	1	A/P	S->I	LG FOV – Axial to the body
Ax DWI	8500	95	340	100	8	2	A/P	S->I	
AXIAL VIBE FS PRE	4.8	2.19	260	100	3	0	A/P	S->I	
AXIAL VIBE FS POST	4.8	2.19	260	100	3	0	A/P	S->I	
SAG VIBE FS POST	3.19	1.46	260	100	3	0	A/P	L->R	

Rectal Cancer (3T Preferred)

Should be performed on 3T. Must be done during the day to be monitored by a radiologist.

Planes for Small FOV axial/coronal image angles determined by radiologist, UNLESS, patients has priors, then copy angles from previous exam

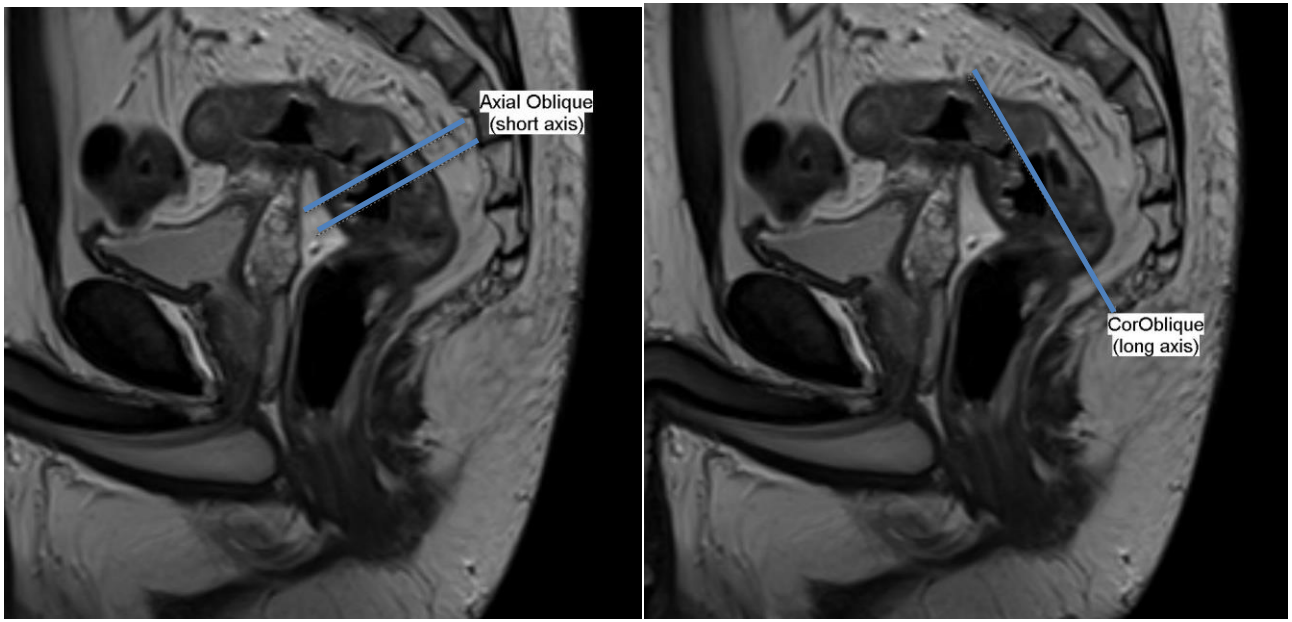

Axial T2 (large FOV)

Sagittal FRFSE T2

Axial Oblique FRFSE T2 (short axis) – *These are axial to the long axis of the tumor/rectum*

Axial Oblique DWI (B=100, 500, 800)

Coronal Oblique T2 (long axis) – *Parallel to the long axis of the rectum/tumor/anal canal as prescribed by the radiologist who QC's the case*

Axial Oblique VIBE FS Pre (small FOV: 3mm slice)

Axial Oblique VIBE FS **Post** (small FOV: 3mm slice) ******Subtractions******

Coronal Oblique VIBE FS **Post** (small FOV: 3mm slice)

Sagittal Oblique VIBE FS **Post** (small FOV: 3mm slice)

Tips for MRI technologist:

Call MD to help select the best imaging planes.

Axial Oblique imaging plane must be **perpendicular** to the long axis of the rectum at the level of the tumor.

High resolution axial oblique images may be repeated if anatomy is curved or the original acquisition does not cover correct anatomy.

If motion artifacts: try fat saturation band or swap phase and frequency.

Rectal Cancer Continued

Sequence	TR	TE	FOV:		Slice Thickness (mm)	Gap (mm)	Phase Direction	Scan Direction	OTHER
			Frequency	Phase %					
Axial T2	2500	80	300	100	5	1	A/P	S->I	Through the bifurcation
SAG T2	2800	101	250	100	4	1	S/I	L->R	
Axial Obl T2 (SAX)	6100	88	1.5T: 160 3T: 200	100	3	0 GE 1.5T: 0.3	A/P	S->I	GE: Zip512 Siemens: Interpolation
*****RAD PLAN ANGLES, UNLESS PATIENT HAS HAD PRIORS, THEN COPY PREVIOUS EXAM*****									
Ax DWI Skyras: Resolve DWI	5000	Min	280	100	6	1	A/P	S->I	b values 100, 500, and 800
COR OBL T2	3000	78	1.5T: 160 3T: 200	100	3	0 GE 1.5T: 0.3	R/L	P->A	GE: Zip512 Siemens: Interpolation
AX OBL VIBE FS PRE	6.47	2.65	240	100	3	1	A/P	S->I	
AX OBL VIBE FS POST	6.47	2.65	240	100	3	1	A/P	S->I	
COR OBL VIBE FS POST	6.2	2.64	240	100	3	1	R/L	P->A	
SAG OBL VIBE FS POST	6.2	2.64	240	100	3	1	A/P	L->R	

Routine Female Pelvis

Adenomyosis, fibroids, adnexa

Planes in relation to the uterus for uterine pathology, otherwise in relation to pelvis

Coronal T2 Whole Pelvis

Axial T1 Whole Pelvis

Small FOV:

- Axial T2
- Axial T2 FS
- Sagittal T2 (uterine evaluation)
- Sagittal T2 FS
- Axial VIBE FS Pre
- ***OPTIONAL WITH CONTRAST***
- Axial VIBE FS **Post ***Subtractions*****
- Coronal VIBE FS **Post**
- Sagittal VIBE FS **Post**

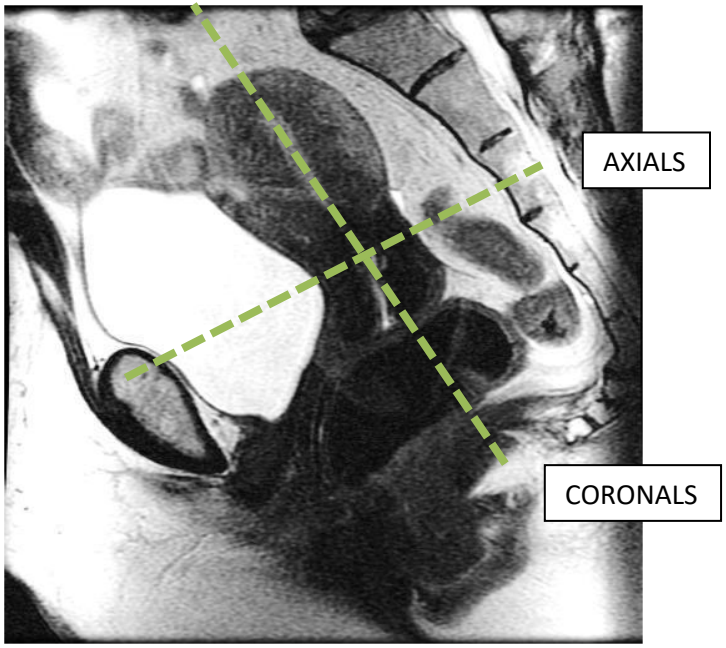

Sequence	TR	TE	FOV		Slice Thickness (mm)	Gap (mm)	Phase Direction	Scan Direction	OTHER
			Frequency	Phase %					
COR T2	1400	91	440	100	5	1	R/L	P->A	Whole Pelvis
AX T1	455	20	300	100	5	1	R/L	S->I	Whole Pelvis
AX T2	5370	91	200	100	5	1	R/L	S->I	
AX T2 FS	3000	91	200	100	5	1	R/L	S->I	
SAG T2	5160	91	220	100	5	1	S/I	L->R	
SAG T2 FS	3000	91	220	100	5	1	S/I	L->R	
AX VIBE FS Pre	6.47	2.65	240	100	3	1	A/P	S->I	
AX VIBE FS Post	6.47	2.65	240	100	3	1	A/P	S->I	
COR VIBE FS Post	4.42	1.46	240	109.4	2	1	R/L	P->A	
Sag VIBE FS Post	4.42	1.46	240	100	2	1	A/P	L->R	

RT Prostate G-

Performed for radiation planning purposes

Set angles straight to the pelvis and cover prostate and seminal vesicles

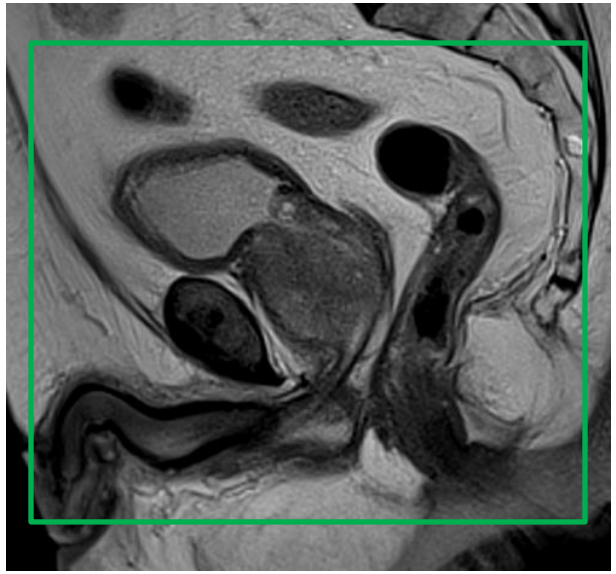

Axial T1 whole pelvis

Small FOV:

- Axial T1
- Axial T2 (3mm slice)
- Sagittal T2 (3mm slice)
- Coronal T2 (3mm slice)

Axial 3D T2

Sequence	TR	TE	FOV:		Slice Thickness (mm)	Gap (mm)	Phase Direction	Scan Direction	OTHER
			Frequency	Phase %					
AX T1	455	20	300	100	5	1	R/L	S->I	Pelvis
AX T1	626	13	200	100	5	1	R/L	S->I	
AX T2	3000	91	200	100	3	0	R/L	S->I	
SAG T2	3000	91	200	100	3	0	S/I	L->R	
COR T2	3000	91	220	100	3	0	R/L	P->A	
AX 3D T2	1700	98	320	100	2	0	R/L	S->I	

THORACIC / ABDOMINAL (AORTA) MRA

****COVER THRU BIFURCATION****

ECG GATED

Axial T2 Haste
Axial Cine
Sagittal OBL Cine
Axial VIBE FS Pre
Sagittal Oblique (Candy Cane) TRICKS
- Axial Reformat
- 3D MIP of Best Arterial Phase

Axial VIBE FS **Post ***Subtractions*****

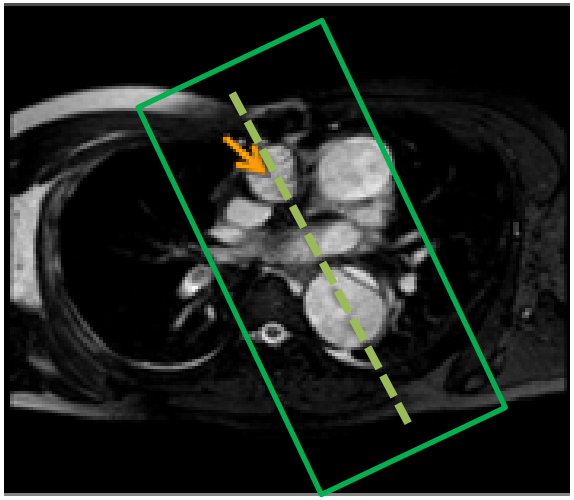

Sagittal Oblique (Candy Cane)

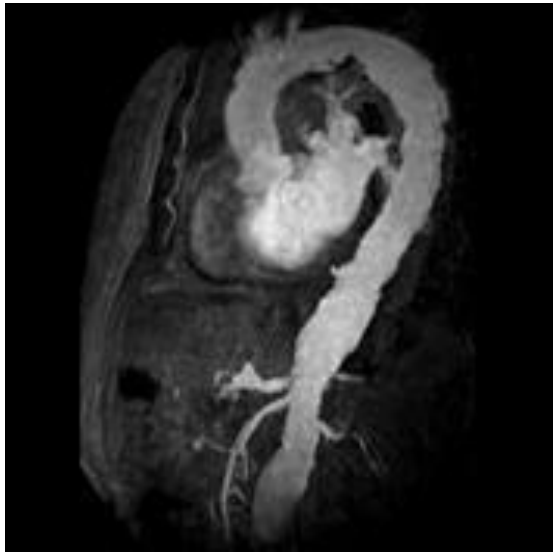

*****ADUST FOV TO APPROPRIATE SIZE TO COVER THE AORTA THROUGH THE BIFURCATION*****
*****WILL NEED TWO STACKS FOR AXIALS (CHEST & ABDOMEN COVERAGE)**

Sequence	TR	TE	FOV:		Slice Thickness (mm)	Gap (mm)	Phase Direction	Scan Direction	OTHER
			Frequency	Phase %					
AX T2 Haste	750	27	380	75	8	2	A/P	S->I	
AX CINE	32	3.04	380	75	8	2	A/P	S->I	
SAG OBL CINE	33.2	3.26	380	75	6	1.2	A/P	L->R	
AX VIBE FS PRE/POST	4.3	1.89	380	75	3	0	A/P	S->I	
SAG OBL TRICKS	2.98	1.06	380	100	1	0	A/P	L->R	

Mesenteric MRA

Coronal T2
Axial T2 FS BH
Axial VIBE FS Pre
Sagittal TRICKS
- Reformat into thin axial and coronal
- 3D MIP of arterial phase

Axial VIBE FS **Post ***Subtractions*****
Coronal VIBE FS 5 MIN **Post**

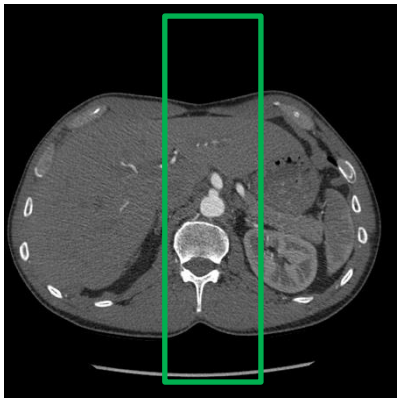

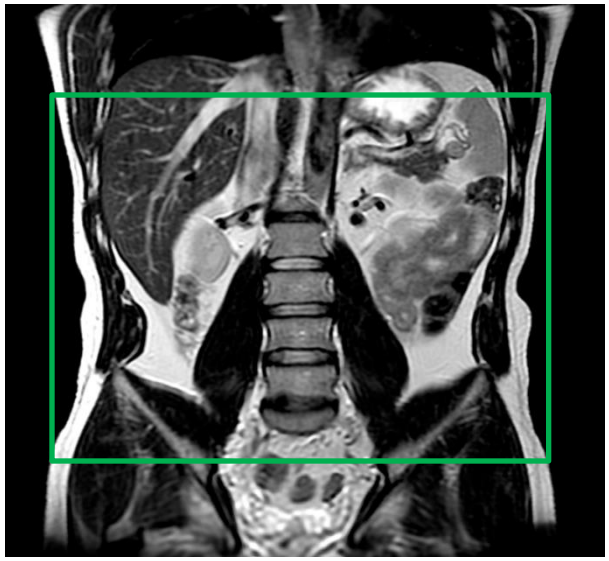

Sequence	TR	TE	FOV:		Slice Thickness (mm)	Gap (mm)	Phase Direction	Scan Direction	OTHER
			Frequency	Phase %					
COR T2	1600	91	440	100	5	1	R/L	P->A	
AX T2 FS	1600	95	380	75	5	1	A/P	S->I	
AX VIBE FS PRE/POST	4.3	1.89	380	81.3	3	1	A/P	S->I	
SAG TRICKS	2.98	1.06	380	100	1.10	0	A/P	L->R	
COR VIBE FS 5 MIN Post	4	1.74	400	100	3	1	R/L	P->A	

MRA Popliteal Entrapment (Siemens ONLY)

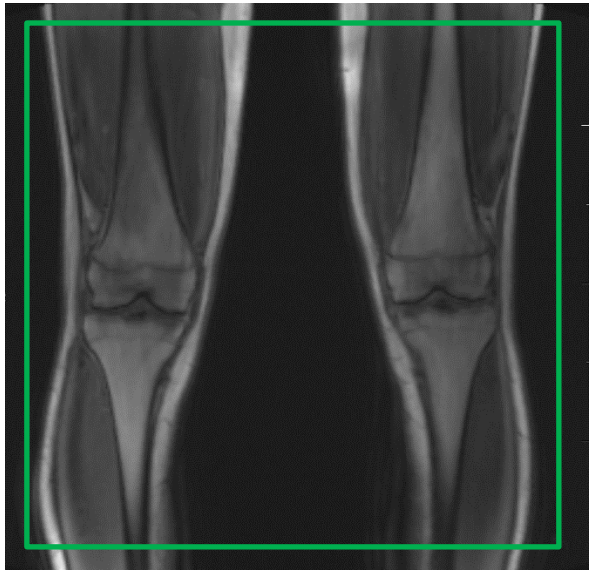

Coronal T1
Axial T1
Sagittal T2 FS (Scan Seperately)
Coronal Plantar-Flexed DCE
- Plantar Flexion (1/2 total dose)

Coronal Dorsi-Flexed DCE
- Dorsi-Flexion (1/2 total dose)

Axial Vibe FS **Post**
Coronal Vibe FS **Post**
FOV Mid-Thigh – Mid-Calf, Smallest FOV Possible

Sequence	TR	TE	FOV:		Slice Thickness (mm)	Gap (mm)	Phase Direction	Scan Direction	OTHER
			Frequency	Phase %					
COR T1	400-700	10-30	280	100	3	1	R/L	P->A	
AX T1	400-700	10-30	280	100	3	1	A/P	S->I	
SAG T2 FS	2000-6000	80-120	280	100	5	1	A/P	L->R	Scan Separately
DCE (Plantar) Measurement	2.68	1.07	280	100	3	0.5	R/L	P->A	Tumor
DCE (Drorsi) Measurements	2.68	1.07	280	100	3	0.5	R/L	P->A	Tumor
AX Vibe FS	12.3	7.8	280	100	1/80 slab	0	R/L	S->I	
COR Vibe FS	12.3	7.8	280	100	1/80 slab	0	R/L	P->A	

Renal MRA

Coronal T2

To determine anatomy and location of kidneys

Axial T2 FS BH

Axial VIBE FS Pre

Coronal TRICKS Post

- Reformat into thin axial and sagittal
- 3D MIP of arterial phase

Axial VIBE FS **Post ***Subtractions*****

Coronal VIBE FS 5 MIN **Post**

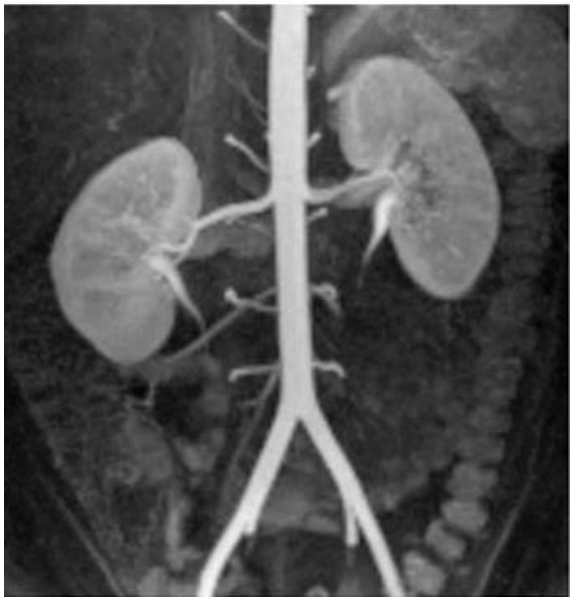

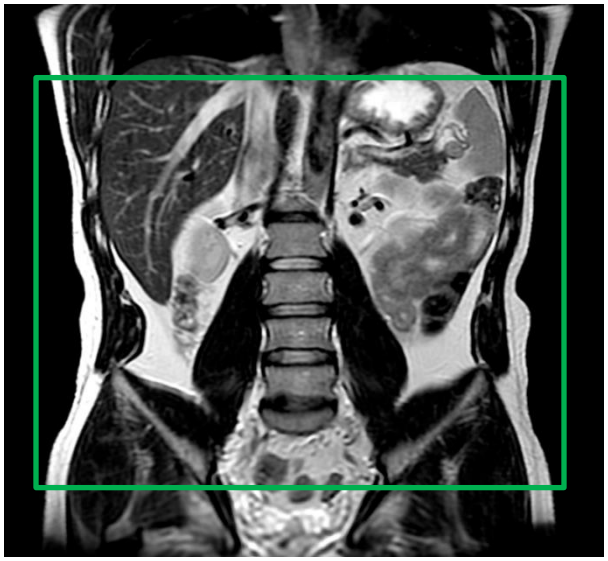

Sequence	TR	TE	FOV:		Slice Thickness (mm)	Gap (mm)	Phase Direction	Scan Direction	OTHER
			Frequency	Phase %					
COR T2	1600	91	440	100	5	1	R/L	P->A	
AX T2 FS	1600	95	380	75	5	1	A/P	S->I	
AX VIBE FS PRE/POST	4.3	1.89	380	75	3	1	A/P	S->I	
COR TRICKS POST	2.98	1.06	380	100	1.10	0	R/L	P->A	
COR VIBE FS 5 MIN Post	4	1.74	400	100	3	1	R/L	P->A	

Body AVM (Siemens ONLY)

Instructions: Place skin markers on 4 sides of the area of interest when possible. If not an arm or a leg, ask the radiologist to confirm if the planes listed are acceptable for coverage.

Axial T2
Axial Stir
Axial T1
Axial GRE
Axial Vibe FS
Coronal 3D Tricks MRA
Axial Vibe FS **Post ***Subtractions*****
-(Subtraction)

*****ADJUST FOV, SLICE THICKNESS/GAP ACCORDING TO BODY PART LOOKING AT*****

Sequence	TR	TE	FOV:		Slice Thickness (mm)	Gap (mm)	Phase Direction	Scan Direction	OTHER
			Frequency	Phase %					
Ax T2	3100	91	200	100	3	1	A/P	S->I	
AX Stir	4000	50	280	100	3	1	A/P	S->I	
AX T1	400-700	10-30	280	100	3	1	A/P	S->I	
AX GRE	500	14	280	100	3	1	A/P	S->I	
AX VIBE FS PRE	12.3	7.8	400	100	1/80 slab	0	R/L	S->I	
COR TRICKS	2.98	1.06	380	100	2	1	R/L	P->A	
AX VIBE FS POST	12.3	7.8	400	100	1/80 slab	0	R/L	S->I	

MRV Abdomen and/or Pelvis DVT

2D TOF – reformat into 3D image

Sat band should be placed superior to the FOV to null arterial flow

Axial VIBE FS Pre

3D MRV Pre (dry run)

3D MRV Post: Scan in 3 phases

(2min/3min/4min)

Reformat each phase into axial and sagittal

3D Coronal MIP of each phase

Axial VIBE FS **Post ***Subtractions*****

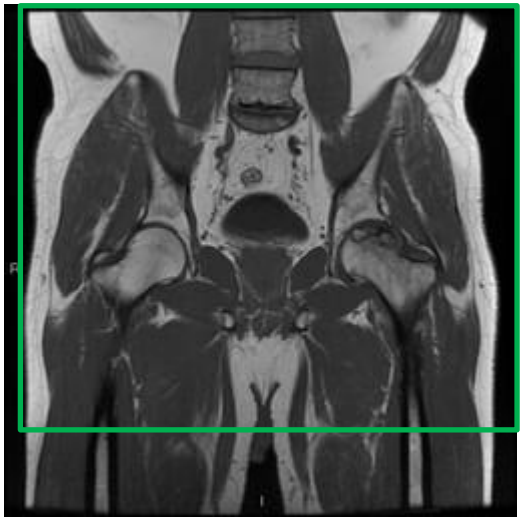

Coverage should include from L3-L4 down through Iliac Crest

Sequence	TR	TE	FOV:		Slice Thickness (mm)	Gap (mm)	Phase Direction	Scan Direction	OTHER
			Frequency	Phase %					
2D TOF	458	3.7	350	50	3.5	-27	A->P	S->I	
AX VIBE FS Pre	6.19	2.39	340	100	3	1	R->L	S->I	
3D MRV Post	3.08	1.11	320	320	1	1	R->L	P->A	
AX VIBE FS Post	6.19	2.39	340	100	3	1	R->L	S->I	