

^{99m}Techneium-Pyrophosphate Imaging for Transthyretin Cardiac Amyloidosis

OVERVIEW

The purpose of this document is to identify the critical components involved in performing ^{99m}Techneium-pyrophosphate (^{99m}Tc-PYP) imaging for the evaluation of cardiac transthyretin amyloidosis (ATTR).

BACKGROUND

- The majority of individuals with cardiac amyloidosis have myocardial amyloid deposits formed from misfolded light chain (AL) or transthyretin (TTR) proteins. Diagnosis of amyloidosis and differentiation between the types is important for prognosis, therapy, and genetic counseling.
- Cardiac TTR amyloidosis, the focus of this practice points document, is an under diagnosed cause of heart failure.
- Amyloid derived from wild-type TTR results in a restrictive cardiomyopathy, most commonly presenting in men in their early 70's onwards, but occasionally seen as young as age 60. Although almost 1 in 4 males > 80 years have some TTR-derived amyloid deposits at autopsy, the clinical significance of a mild degree of deposition is unknown--generally clinical manifestations of heart failure occur once enough amyloid has been deposited to cause LV wall thickening (1).
- Approximately 3 – 4% among US African Americans have a common inherited mutation of the TTR gene (Val122Ile), which produces a restrictive cardiomyopathy in a minority, but may contribute to heart failure in a higher proportion (1).
- Cardiac amyloidosis should be suspected in individuals with heart failure and thickened ventricles with grade 2 or greater diastolic dysfunction on echocardiography or typical findings on cardiac magnetic resonance imaging (CMR; diffuse late gadolinium enhancement, ECV expansion or characteristic T-1 relaxation times);

diagnosis is confirmed by endomyocardial biopsy and typing of amyloid fibrils as needed.

- Several studies confirm the high sensitivity and specificity of ^{99m}Tc-bone compound scintigraphy (^{99m}Tc-3,3-diphosphono-1,2-propanodicarboxylic acid (DPD) or PYP(2, 3)) for cardiac ATTR amyloidosis; recent studies highlight the value of DPD and/or PYP in differentiating cardiac ATTR from AL amyloidosis (4).
- A distinct advantage of ^{99m}Tc-PYP imaging, even when echocardiography and CMR are diagnostic for cardiac amyloidosis, is its ability to specifically identify ATTR cardiac amyloidosis non-invasively and thereby guide patient management (5).

PATIENT SELECTION

- Individuals with heart failure and unexplained increase in left ventricular wall thickness.
- African-Americans over the age of 60 years with heart failure, unexplained or with increased left ventricular wall thickness (>12 mm).
- Individuals over the age of 60 years with unexplained heart failure with preserved ejection fraction.
- Individuals, especially elderly males, with unexplained neuropathy, bilateral carpal tunnel syndrome or atrial arrhythmias in the absence of usual risk factors, and signs/symptoms of heart failure.
- Evaluation of cardiac involvement in individuals with known or suspected familial amyloidosis.
- Diagnosis of cardiac ATTR in individuals with CMR or echocardiography consistent with cardiac amyloidosis.
- Patients with suspected cardiac ATTR amyloidosis and contraindications to CMR such as renal insufficiency or an implantable cardiac device (5).

^{99m}Tc-Technetium-Pyrophosphate Imaging for Transthyretin Cardiac Amyloidosis

OBTAINING THE RADIOTRACER

- ^{99m}Tc-PYP is readily available as unit doses from commercial radiopharmaceutical distributors or as kits for preparation (TechneScan PYPTM, Mallinckrodt, St. Louis, MO).
- Kits containing 5 or 30 single-use vials are commercially available. Each 10 ml vial contains 11.9 mg of sodium pyrophosphate and 3.2 mg of stannous chloride and 4.4 mg of total tin, and this kit is approved for bone, cardiac (for the detection of myocardial infarction), and blood pool (radionuclide ventriculography and GI bleeding) imaging (see package insert for details of reconstitution of ^{99m}Tc-PYP).
- The total body effective dose from 15 mCi of ^{99m}Tc-PYP is estimated at 3.2 mSv.
- ^{99m}Tc-DPD is not available for clinical use in the United States. Although there are no large studies directly comparing the agents, the principles in this document apply similarly to ^{99m}Tc-DPD and ^{99m}Tc-PYP imaging.

TEST PREPARATION

- No specific test preparation is required.

IMAGING PROCEDURE

- Commonly used imaging procedures for ^{99m}Tc-PYP imaging are shown in **Table 1**. Individual centers can modify imaging procedures based on local camera capabilities and expertise.
- Cardiac or chest SPECT and planar images are obtained one hour after injection of ^{99m}Tc-PYP using the parameters listed in Table 1. If persistent blood pool activity is noted on one hour images (e.g., renal failure), delayed images may be obtained at 3 hours.
- Planar imaging is rapid, simple to perform, and useful for visual interpretation and quantification of the degree of myocardial uptake (see image interpretation) by heart to lung ratio or comparison to rib uptake.
- SPECT imaging may be helpful to
 1. avoid overlap of bone uptake
 2. distinguish blood pool activity from myocardial activity(3)
 3. assess the distribution of myocardial ^{99m}Tc-PYP uptake in individuals with positive planar scans
 4. identify ^{99m}Tc-PYP uptake in the interventricular septum (commonly involved in amyloidosis) and
 5. quantify the degree of myocardial uptake by comparison to rib uptake.
- Whole body planar imaging may be helpful to identify uptake of ^{99m}Tc-PYP in the shoulder and hip girdles (a specific sign of systemic ATTR amyloidosis) (6) and should be considered adjunctive and optional in addition to standard cardiac-centered imaging, based on local expertise.
- The value of ^{99m}Tc-PYP imaging with the newer “cardiac only” SPECT cameras needs further validation (due to inability to accurately display bone and lung ^{99m}Tc-PYP uptake with these systems; see image interpretation section).

^{99m}Tc-Technetium-Pyrophosphate Imaging for Transthyretin Cardiac Amyloidosis

Table 1. Imaging Parameters for Cardiac ^{99m}Tc-PYP Imaging

Imaging procedures	Parameters
Preparation	No specific preparation. No fasting required.
Scan	Rest scan
Dose of ^{99m} Tc-PYP	10-20 mCi intravenously
Time between injection and acquisition	Recommended: 1-hour SPECT and planar; Optional: 3-hour SPECT or planar
Imaging parameters	
Field of view	Recommended: Cardiac or chest; Optional: Wholebody planar
Image type	Recommended: Cardiac or chest SPECT and planar imaging
Position	Supine
Energy window	140 keV, 15-20%
Collimators	Low energy, high resolution
Matrix	64 X 64 minimum
Pixel size	3.5 – 6.5 mm
Planar imaging specific parameters	
Number of views*	Anterior, Lateral, and Left Anterior Oblique
Detector configuration	90 degrees
Image duration (count based)	750,000 counts
Magnification	1.46
SPECT imaging specific parameters	
Angular range	360 degrees
Detector configuration	180 degrees
ECG gating	Off; Nongated imaging
Number of views/detector	40
Time per stop	20 seconds
Magnification	1.0

*Anterior and lateral views can be obtained at the same time using a 90 degree detector configuration; lateral planar views or SPECT imaging may help separate sternal from myocardial uptake.

IMAGE INTERPRETATION

- The anterior and lateral planar images as well as the rotating projection images and reconstructed SPECT images are reviewed in standard cardiac imaging planes using commercial software.
- Myocardial ^{99m}Tc-PYP uptake patterns are categorized as absent, focal, diffuse or focal on diffuse.
- Scans with focal ^{99m}Tc-PYP uptake could represent rib fracture or previous myocardial infarction. Following a myocardial infarction, myocardial ^{99m}Tc-PYP uptake may be positive for upto 7 days and rarely may remain persistently positive.

Quantifying myocardial ^{99m}Tc-PYP Uptake

There are two approaches to quantification:

1. **Quantitative: myocardial to contralateral lung ratio of uptake at 1 hour**
 - Circular target regions of interest (ROI) are drawn over the heart on the planar images and are mirrored over the contralateral chest to account for background and ribs (**see Figure 1**).
 - Total and absolute mean counts are measured in each ROI. A heart to contralateral (H/CL) ratio is calculated as the fraction of heart ROI mean counts to contralateral chest ROI mean counts.
 - H/CL ratios of ≥ 1.5 at one hour are classified as ATTR positive and ratios < 1.5 as ATTR negative (4).
2. **Semi-quantitative: visual comparison to bone (rib) uptake at 3 hours**

Cardiac uptake of ^{99m}Tc-PYP is evaluated using a semi-quantitative visual scoring method in relation to bone uptake (**Table 2 and Figure 2**). Based on previously published results, visual scores of greater than or equal to 2 on planar (2, 3) or SPECT images at 3 hours (6) are classified as ATTR positive, and scores of less than 2 as ATTR negative.

While grade 2-3 or H/CL > 1.5 uptake is strongly suggestive of TTR amyloidosis, any degree of ^{99m}Tc-PYP uptake can also be seen in AL amyloidosis, and as such a complete evaluation is warranted to exclude this diagnosis.

In clinical practice both semi-quantitative visual scoring and H/CL are used.

^{99m}Tc-Technetium-Pyrophosphate Imaging for Transthyretin Cardiac Amyloidosis

Table 2. Semi-quantitative Visual Grading of Myocardial ^{99m}Tc-PYP Uptake by Comparison to Bone(rib) Uptake

Grade	Myocardial ^{99m} Tc-PYP Uptake
Grade 0	no uptake and normal bone uptake
Grade 1	uptake less than rib uptake
Grade 2	uptake equal to rib uptake
Grade 3	uptake greater than rib uptake with mild/absent rib uptake

Figure 1. Quantitation of Cardiac ^{99m}Tc-PYP Uptake Using Heart to Contralateral Lung (H/CL) Ratio

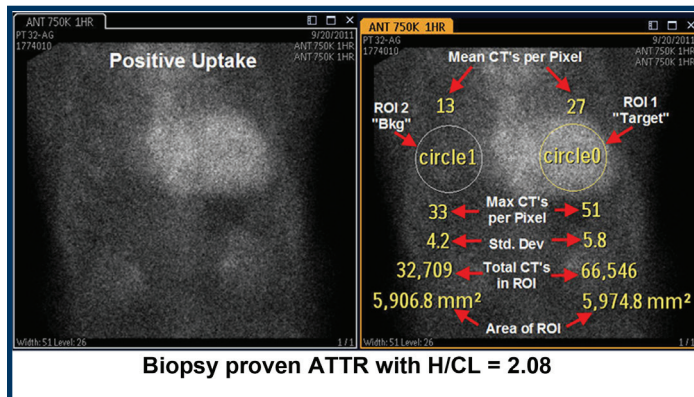
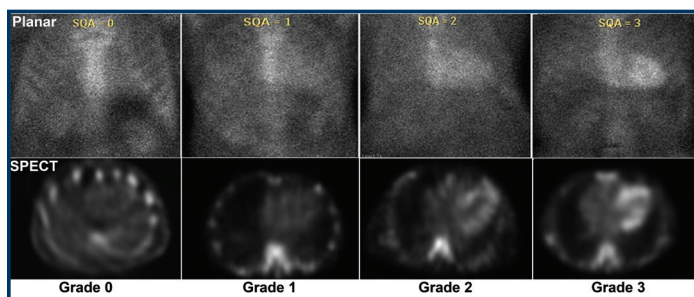


Figure 2. Grading ^{99m}Tc-PYP Uptake on Planar and SPECT Images



REPORTING

The report should include all elements of an ideal report as per standard ASNC guidelines.

Table 3. Myocardial ^{99m}Tc-PYP Imaging Guideline for Reporting

Parameters	Elements
Demographics	Patient name, age, sex, reason for the test, date of study, prior imaging procedures, biopsy results if available (required)
Methods	Imaging technique, radiotracer dose and mode of administration, interval between injection and scan, scan technique (planar and SPECT) (required)
Findings	Image quality Visual scan interpretation (required) Semi-quantitative interpretation in relation to rib uptake (required) Quantitative findings heart to contralateral lung ratio (optional; recommended for positive scans)
Ancillary findings	Whole body imaging if planar whole body images are acquired (optional) Interpret CT for attenuation correction if SPECT/CT scanners are used (recommended)
Conclusions	<ol style="list-style-type: none"> An overall interpretation of the findings into categories of 1) not suggestive of TTR amyloidosis; 2) strongly suggestive of TTR amyloidosis or 3) equivocal for TTR amyloidosis <ol style="list-style-type: none"> Not suggestive: A semi-quantitative visual score of 0 or H/CL ratio < 1. Strongly suggestive: A semi-quantitative visual score of 2 or 3 or H/CL ratio > 1.5 Equivocal: A semi-quantitative visual score of 1 or H/CL ratio 1-1.5 Interpret the results in the context of prior evaluation <ol style="list-style-type: none"> If echo/CMR are strongly positive, and ^{99m}Tc PYP negative, consider further evaluation including endomyocardial biopsy <p>Of note: A negative or mildly positive PYP does not exclude AL amyloid. In addition, equivocal results could represent AL amyloid or early TTR amyloid</p>

^{99m}Tc-pyrophosphate Imaging for Transthyretin Cardiac Amyloidosis

BILLING

ASNC would recommend:

- For planar with SPECT report CPT 78803 Radiopharmaceutical localization of tumor or distribution of radiopharmaceutical agent(s); tomographic (SPECT).
- When reporting CPT 78803, planar imaging of a limited area or multiple areas should be included with the SPECT.
- For the HCPCS level II code report A9538 ^{99m}Tc-pyrophosphate, diagnostic, per study dose, up to 25 millicuries.
- For a single planar imaging session alone (without a SPECT study), report CPT 78800 Radiopharmaceutical localization of tumor or distribution of radiopharmaceutical agent(s); limited area.

REFERENCES:

- (1) Ruberg FL, Berk JL. Transthyretin (TTR) cardiac amyloidosis. *Circulation* 2012;126:1286-300.
- (2) Perugini E, Guidalotti PL, Salvi F, Cooke RM, Pettinato C, Riva L et al. Noninvasive etiologic diagnosis of cardiac amyloidosis using ^{99m}Tc-3,3-diphosphono-1,2-propanodicarboxylic acid scintigraphy. *Journal of the American College of Cardiology* 2005;46:1076-84.
- (3) Gertz MA, Brown ML, Hauser MF, Kyle RA. Utility of technetium Tc ^{99m} pyrophosphate bone scanning in cardiac amyloidosis. *Archives of internal medicine* 1987;147:1039-44.
- (4) Bokhari S, Castano A, Pozniakoff T, Deslisle S, Latif F, Maurer MS. (^{99m}Tc-pyrophosphate scintigraphy for differentiating light-chain cardiac amyloidosis from the transthyretin-related familial and senile cardiac amyloidoses. *Circulation Cardiovascular imaging* 2013;6:195-201.
- (5) Falk RH, Quarta CC, Dorbala S. How to image cardiac amyloidosis. *Circulation Cardiovascular imaging* 2014;7:552-62.
- (6) Hutt DF, Quigley AM, Page J, Hall ML, Burniston M, Gopaul D et al. Utility and limitations of 3,3-diphosphono-1,2-propanodicarboxylic acid scintigraphy in systemic amyloidosis. *European heart journal cardiovascular Imaging* 2014;15:1289-98.

ASNC thanks the following members for their contributions to this document:

Writing Group:

Sharmila Dorbala, MD (Chair)
 Sabahat Bokhari, MD
 Edward Miller, MD
 Renee Bullock-Palmer, MD
 Prem Soman, MD
 Randall Thompson, MD

Reviewers:

Rodney Falk, MD
 Martha Grogan, MD
 Matthew Maurer, MD
 Frederick Ruberg, MD