

# Purpose of pulmonary CTA

- to diagnose PE
- to *help* risk stratify (RV/LV ratio)

**Table 9** Classification of patients with acute PE based on early mortality risk

Early mortality risk		Risk parameters and scores		
		Shock or hypotension	PESI class III-V or sPESI >1 <sup>a</sup>	Signs of RV dysfunction on an imaging test <sup>b</sup>
High		+	(+) <sup>d</sup>	+
Intermediate	Intermediate-high	–	+	Both positive
	Intermediate-low	–	+	Either one (or none) positive <sup>e</sup>
Low		–	–	Assessment optional; if assessed, both negative <sup>e</sup>

PE = pulmonary embolism; PESI = Pulmonary embolism severity index; RV = right ventricular; sPESI = simplified Pulmonary embolism severity index.

<sup>a</sup>PESI Class III to V indicates moderate to very high 30-day mortality risk; sPESI ≥ 1 point(s) indicate high 30-day mortality risk.

<sup>b</sup>Echocardiographic criteria of RV dysfunction include RV dilation and/or an increased end-diastolic RV–LV diameter ratio (in most studies, the reported threshold value was 0.9 or 1.0); hypokinesia of the free RV wall; increased velocity of the tricuspid regurgitation jet; or combinations of the above. On computed tomographic (CT) angiography (four-chamber views of the heart), RV dysfunction is defined as an increased end-diastolic RV/LV (left ventricular) diameter ratio (with a threshold of 0.9 or 1.0).

# Ventricular Diameter Measurement

- Maximum distance between ventricular endocardium and interventricular septum
- Perpendicular to long axis of heart
- Near base of heart, i.e. near plane of mitral and tricuspid valves
- Maximum dimension of RV and LV **may be at different levels**, i.e. not on the same image

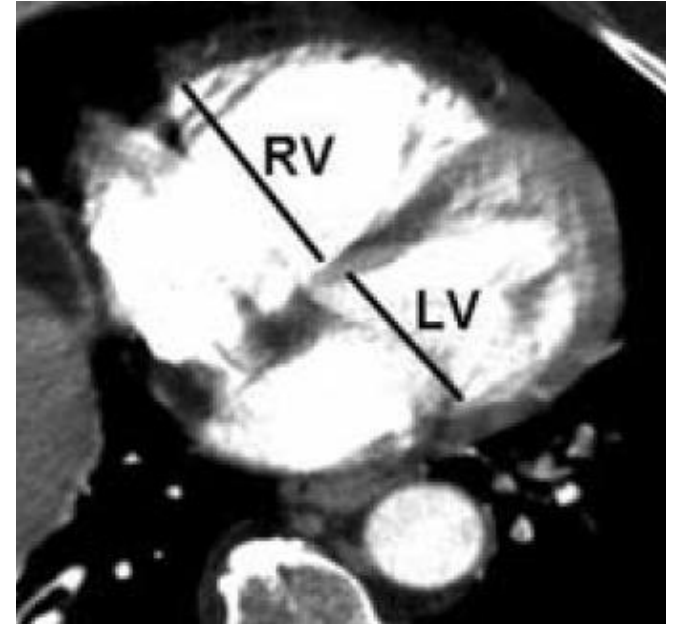
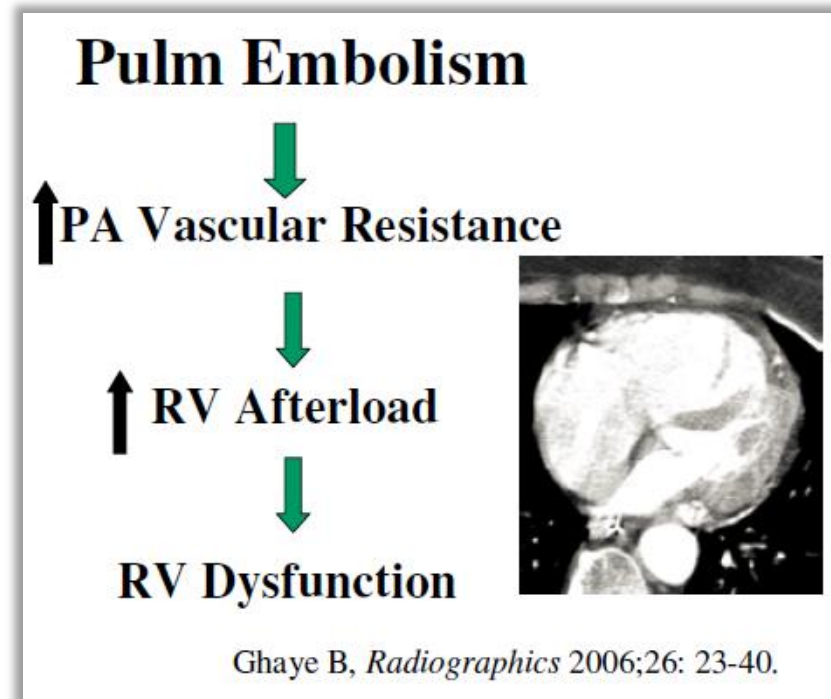


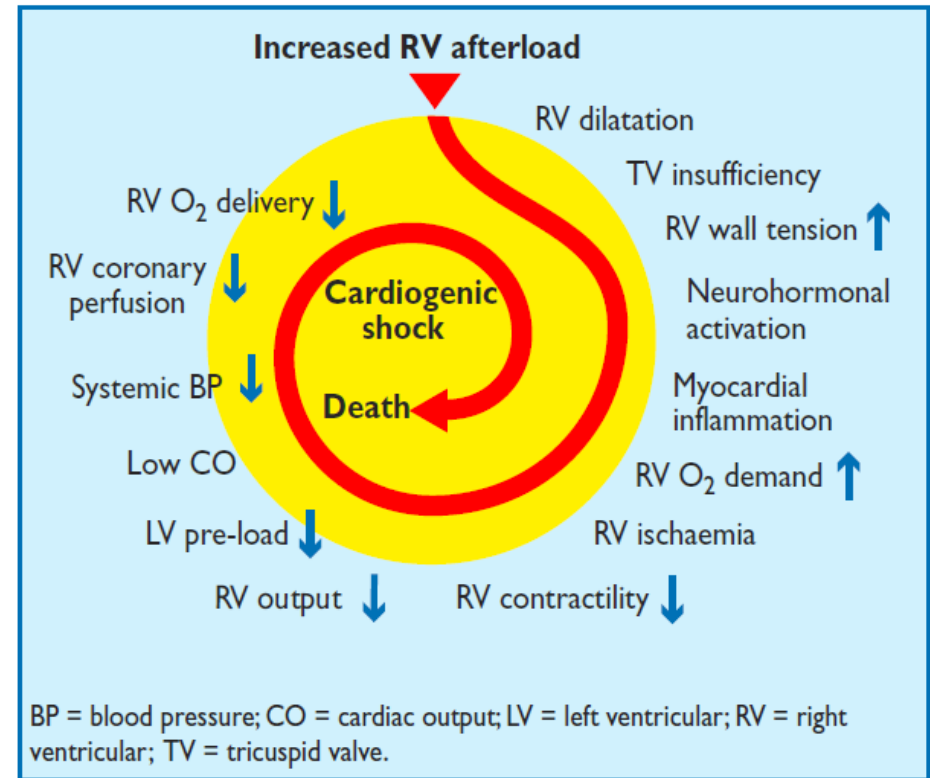
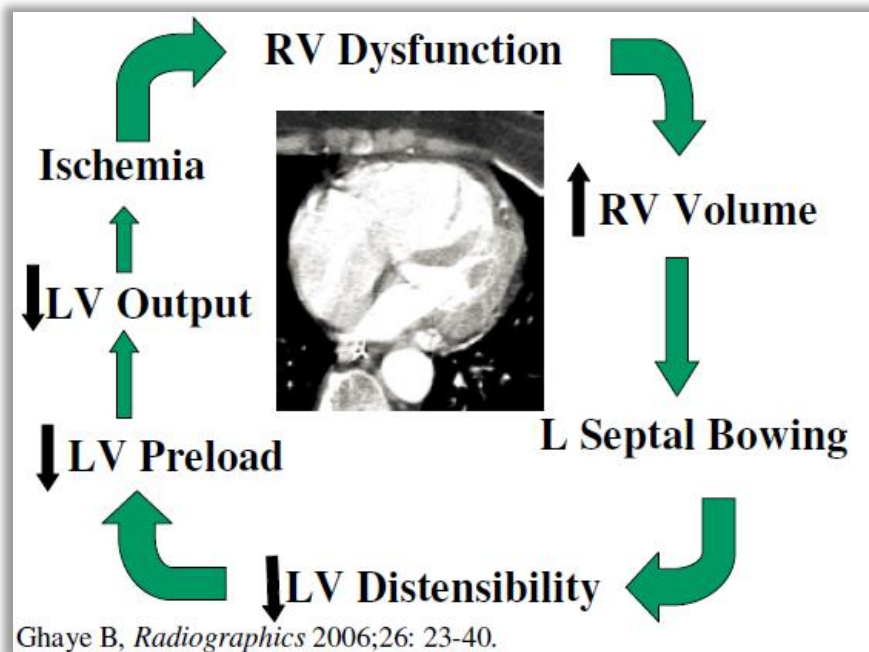
Image from Reference 2

# What is Acute RV Strain?

- = Acute right heart dysfunction
  - Acute obstruction from PE
  - RV's only response from acute pressure overload is to dilate
  - RV cannot suddenly increase contractility (inotropy)
  - Acute systolic dysfunction



# Vicious cycle if severe PA obstruction & RV dysfunction untreated, leading to hemodynamic collapse:



from Reference 5

# RV/LV ratio

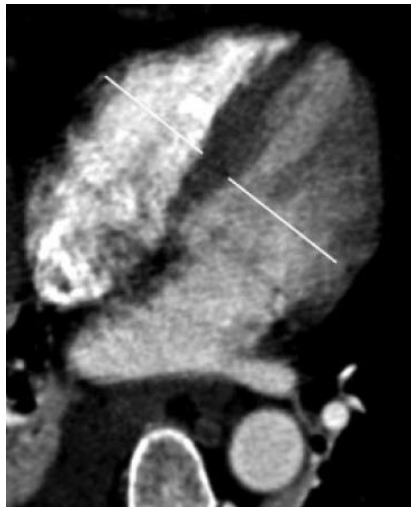- RV/LV ratio cutoff  $\geq 0.9$  for mortality risk: More sensitive & less specific
- RV/LV ratio cutoff  $\geq 1.0$  for mortality risk: Less sensitive & more specific

**Table 8** Imaging and laboratory tests<sup>a</sup> for prediction of early<sup>b</sup> mortality in acute PE

Test or biomarker	Cut-off value	Sensitivity, % (95% CI)	Specificity, % (95% CI)	NPV, % (95% CI)	PPV, % (95% CI)	OR or HR (95% CI)	No. patients	Study design (reference)	Remarks
Echocardiography	Various criteria of RV dysfunction	74 (61–84)	54 (51–56)	98 (96–99)	8 (6–10)	2.4 (1.3–4.3)	1249	Meta-analysis <sup>226</sup>	RV dysfunction on echocardiography or CT was one of the inclusion criteria in two randomized trials investigating thrombolysis in normotensive patients with PE. <sup>252, 253</sup>
CT angiography	RV/LV $\geq 1.0$	46 (27–66)	59 (54–64)	93 (89–96)	8 (5–14)	1.5 (0.7–3.4)	383	Meta-analysis <sup>226</sup>	
	RV/LV $\geq 0.9$	84 (65–94)	35 (30–39)	97 (94–99)	7 (5–10)	2.8 (0.9–8.2)	457	Prospective cohort <sup>228</sup>	

from Reference 5

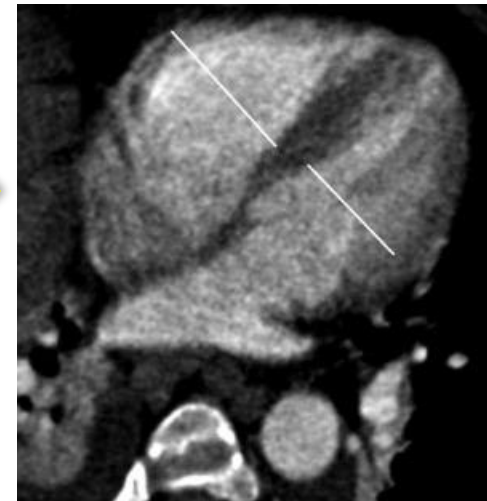# Change in RV/LV ratio improves specificity



No PE  
RV/LV ratio 0.90



Next PE-CTA  
on same  
patient



+ PE  
RV/LV ratio 1.18 = **31%↑**

**Table 2**

**Specificity, NPV, PPV, and Hazard Ratios of the Interval Increase and the RV/LV Diameter Ratio for 30-day PE-related Mortality**

Calculation	Interval Increase	RV/LV Diameter Ratio	<i>P</i> Value
Specificity	0.93	0.59	.001
NPV	0.95	0.92	.36
PPV	0.70	0.29	.002
Hazard ratio	19	4.2	.05

Note.—This comparison was made at a fixed sensitivity of 0.78, corresponding to an interval increase of more than 18% and an RV/LV diameter ratio of more than 1.0.

## Non-specific findings of right heart strain that may accompany $\uparrow$ RV/LV ratio:

- interventricular septum flattening or bowing (towards LV chamber)
- venous contrast reflux & dilatation:
  - IVC, +/- hepatic veins
  - (azygous venous system)
  - (coronary sinus)

# When in doubt...

- Unsure about PE burden (large vs moderate), but  $\uparrow$ RV/LV ratio, or uncertain if there's acute R heart strain?
  - **Suggest an echocardiogram**
- Echocardiogram
  - Most patients have at least trace tricuspid regurgitation
  - Velocity of regurgitant blood flow can be used to estimate right heart pressure
  - TAPSE (tricuspid annular plane systolic excursion) used to estimate ejection fraction
  - No radiation or IV contrast needed



# CTA PE reporting template

You will not see the text in red; this is how the template appears in PowerScribe AutoText Editor

**EXAMINATION:** CTA chest for pulmonary arteries

**CLINICAL HISTORY:** [Reason For Study]

**TECHNIQUE:** [Thickness] mm thick axial contiguous sections were obtained through the chest via helical acquisition after the intravenous administration of [Volume] cc of [Contrast]. Thin-section reconstructions as well as coronal and sagittal MIP reformatted images were generated to aid in evaluation.

**COMPARISON:** [Comparison]

**FINDINGS:**

Pulmonary arteries: [filling defects]

If severe/large/central pulmonary embolism burden present:

RV diameter: [RV diameter] mm

LV diameter: [LV diameter] mm

RV/LV ratio: [RV LV ratio]

Ancillary findings:

Interventricular septum flattening or bowing: [Interventricular septum: Present/Absent/N/A]

Venous contrast reflux: [Venous contrast reflux: IVC/IVC and hepatic veins/N/A]

Other cardiovascular structures: [cardiovascular]

Pulmonary parenchyma: [Parenchyma]

Airways: [Airways]

Pleura: [Pleura]

Lymph nodes: [Lymph]

Other mediastinal structures: [Mediastinum]

Upper abdomen: [Upper Abdomen]

Skeletal structures: [Skeletal]

**IMPRESSION:**

[impression: No pulmonary embolism identified./Critical finding: Severe/large/central pulmonary embolism burden with CT findings for right heart strain. Recommend consultation with on-call Acute PE Team member to assist in management and treatment decisions.]

# CTA PE reporting template

This is how the template will appear when you are dictating.

PowerScribe 360 | Reporting

File Edit View Insert Format Tools Speech Help

Close Draft Prelim Sign Discard PACS AutoText New...

B I U ABC Content Wizard... Montage...

00:00 ~ 00:00

**Fields (20)**

- Reason For Study
- Thickness
- Volume
- Contrast
- Comparison
- filling defects
- RV diameter
- LV diameter
- RV/LV ratio
- Interventricular septum
- Venous contrast reflux
- cardiovascular
- Parenchyma
- Airways
- Pleura
- Lymph
- Mediastinum
- Upper Abdomen
- Skeletal
- impression

**Report - WELCH, MARY L - 7657581**

**EXAMINATION:** CTA chest for pulmonary arteries

**CLINICAL HISTORY:** [ ]

**TECHNIQUE:** [3] mm thick axial contiguous sections were obtained through the chest via helical acquisition after the intravenous administration of [ ] cc of [Omnipaque-350]. Thin-section reconstructions as well as coronal and sagittal MIP reformatted images were generated to aid in evaluation.

**COMPARISON:** [None]

**FINDINGS:**

Pulmonary arteries: [No pulmonary arterial filling defects.]

If severe/large/central pulmonary embolism burden present:

RV diameter: [N/A] mm

LV diameter: [N/A] mm

RV/LV ratio: [N/A]

Ancillary findings:

Interventricular septum flattening or bowing: [N/A]

Venous contrast reflux: [N/A]

Other cardiovascular structures: [No significant findings.]

Pulmonary parenchyma: [No significant findings.]

Airways: [No significant findings.]

Pleura: [No significant findings.]

Lymph nodes: [No significant findings.]

Other mediastinal structures: [No significant findings.]

Upper abdomen: [No significant findings.]

Skeletal structures: [No significant findings.]

**IMPRESSION:**

[No pulmonary embolism identified.]

Enter Findings Mode

# CTA PE reporting template

PowerScribe 360 | Reporting

File Edit View Insert Format Tools Speech Help

Close Draft Prelim Sign Discard PACS AutoText New...

B I U A Content Wizard... Montage...

00:00 - 00:00

**Fields (20)**

- Reason For Study
- Thickness
- Volume
- Contrast
- Comparison
- Filling defects
- RV diameter
- LV diameter
- RV/LV ratio
- Interventricular septum**
- Venous contrast reflux
- cardiovascular
- Parenchyma
- Airways
- Pleura
- Lymph
- Mediastinum
- Upper Abdomen
- Skeletal
- Impression

**Report - WELCH, MARY L - 7657581**

**EXAMINATION:** CTA chest for pulmonary arteries

**CLINICAL HISTORY:** [ ]

**TECHNIQUE:** [3] mm thick axial contiguous sections were obtained through the chest via helical acquisition after the intravenous administration of [ ] cc of [Omnipaque-350]. Thin-section reconstructions as well as coronal and sagittal MIP reformatted images were generated to aid in evaluation.

**COMPARISON:** [None]

**FINDINGS:**

Pulmonary arteries: [No pulmonary arterial filling defects]

If severe/large/central pulmonary embolism burden present:

RV diameter: [N/A] mm

LV diameter: [N/A] mm

RV/LV ratio: [N/A]

Ancillary findings:

Interventricular septum flattening or bowing: [N/A]

Venous contrast reflux: [N/A]

Other cardiovascular structures: [No significant findings]

Pulmonary parenchyma: [No significant findings]

Airways: [No significant findings]

Pleura: [No significant findings]

Lymph nodes: [No significant findings]

Other mediastinal structures: [No significant findings]

Upper abdomen: [No significant findings]

Skeletal structures: [No significant findings]

**IMPRESSION:**

[No pulmonary embolism identified]

Enter Findings Mode

Pick list choices  
for IV septum



Pick List Choices

- Present
- Absent
- N/A



# CTA PE reporting template

PowerScribe 360 | Reporting

File Edit View Insert Format Tools Speech Help

Close Draft Prelim Sign Discard PACS AutoText New...

B I U A A Content Wizard... Montage...

00:00 - 00:00

**Fields (20)**

- Reason For Study
- Thickness
- Volume
- Contrast
- Comparison
- filling defects
- RV diameter
- LV diameter
- RV LV ratio
- Interventricular septum
- Venous contrast reflux**
- cardiovascular
- Parenchyma
- Airways
- Pleura
- Lymph
- Mediastinum
- Upper Abdomen
- Skeletal
- impression

**Report - WELCH, MARY L - 7657581**

**EXAMINATION:** CTA chest for pulmonary arteries

**CLINICAL HISTORY:** [ ]

**TECHNIQUE:** [3] mm thick axial contiguous sections were obtained through the chest via helical acquisition after the intravenous administration of [ ] cc of [Omnipaque-350]. Thin-section reconstructions as well as coronal and sagittal MIP reformatted images were generated to aid in evaluation.

**COMPARISON:** [None]

**FINDINGS:**

Pulmonary arteries: [No pulmonary arterial filling defects]

If severe/large/central pulmonary embolism burden present:

RV diameter: [N/A] mm

LV diameter: [N/A] mm

RV/LV ratio: [N/A]

Ancillary findings:

Interventricular septum flattening or bowing: [N/A]

Venous contrast reflux: [N/A]

Other cardiovascular structures: [No significant findings]

Pulmonary parenchyma: [No significant findings]

Airways: [No significant findings]

Pleura: [No significant findings]

Lymph nodes: [No significant findings]

Other mediastinal structures: [No significant findings]

Upper abdomen: [No significant findings]

Skeletal structures: [No significant findings]

**IMPRESSION:**

[No pulmonary embolism identified]

Enter Findings Mode

Pick list choices  
for venous  
contrast reflux

Pick List Choices  
IVC  
IVC and hepatic veins  
N/A

# CTA PE reporting template

Pick list choices for Impression.  
If neither choice applies, override the pick list choices with straight dictation.

If critical finding selected, don't forget to also add communication documentation to ordering provider. You do NOT need to call PE response team.

**PowerScribe 360 | Reporting**

File Edit View Insert Format Tools Speech Help

Close Draft Prelim Sign Discard PACS AutoText New...

Content Wizard... Montage...

00:00 - 00:00

**Fields (20)**

- Reason For Study
- Thickness
- Volume
- Contrast
- Comparison
- Filling defects
- RV diameter
- LV diameter
- RV/LV ratio
- Interventricular septum
- Venous contrast reflux
- cardiovascular
- Parenchyma
- Airways
- Pleura
- Lymph
- Mediastinum
- Upper Abdomen
- Skeletal
- Impression**

**Report - WELCH, MARY L - 7657581**

**EXAMINATION:** CTA chest for pulmonary arteries

**CLINICAL HISTORY:** [ ]

**TECHNIQUE:** [3] mm thick axial contiguous sections were obtained through the chest via helical acquisition after the intravenous administration of [ ] cc of [Omnipaque-350]. Thin-section reconstructions as well as coronal and sagittal MIP reformatted images were generated to aid in evaluation.

**COMPARISON:** [None]

**FINDINGS:**

Pulmonary arteries: [No pulmonary arterial filling defects]

If severe/large/central pulmonary embolism burden present:

RV diameter: [N/A] mm

LV diameter: [N/A] mm

RV/LV ratio: [N/A]

Ancillary findings:

Interventricular septum flattening or bowing: [N/A]

Venous contrast reflux: [N/A]

Other cardiovascular structures: [No significant findings]

Pulmonary parenchyma: [No significant findings]

Airways: [No significant findings]

Pleura: [No significant findings]

Lymph nodes: [No significant findings]

Other mediastinal structures: [No significant findings]

Upper abdomen: [No significant findings]

Skeletal structures: [No significant findings]

**IMPRESSION:**

Critical finding: Severe/large/central pulmonary embolism burden with CT findings for right heart strain. Recommend consultation with on-call Acute PE Team member to assist in management and treatment decisions.

**Pick List Choices**

- No pulmonary embolism identified.
- Critical finding: Severe/large/central pulmonary embolism

**Properties**

- Fields (20)
- Notes
- Attachments

# Summary

- Look for **severe PE** (e.g. large PE burden, central saddle embolus)
- If **severe PE** present, then measure **RV & LV diameters** (may be on different image slices) and calculate **RV/LV ratio**
- **If severe PE +  $\uparrow$ RV/LV ratio ( $\geq 0.90$ ):**
  - **“Critical finding.** Severe PE burden and CT findings suggestive of right heart strain.”
    - [Critical finding = Phone call ordering provider.]
  - “Recommend consultation with on-call Acute PE team member to assist in management and treatment decisions.”
    - [You are not expected to call PE response team on-call staff. Ordering provider should call operator.]
- Uncertain/borderline severe PE +/-  $\uparrow$  RV/LV ratio:
  - Suggest **echocardiogram**

# ACute Evaluation and Treatment of Pulmonary Embolism (ACE-PE) Team

= DHMC's pulmonary embolism response team name

- Members from Interventional Cardiology, Critical Care, Emergency Medicine, Pulmonary Medicine, others
- Dr. Percarpio is Interventional Radiology representative
- One person from team is on-call each day (see Amion)

**“Go Live” for PE response  
team & default PE dictation  
template: Monday 4/17/17**

# References

1. Lu MT, et al. Interval increase in right-left ventricular diameter ratios at CT as a predictor of 30-day mortality after acute pulmonary embolism: initial experience. *Radiology* 2008; 246: 281-287.
2. Becattini C, et al. Multidetector computed tomography for acute pulmonary embolism: diagnosis and risk stratification in a single test. *Eur Heart J* 2011; 32: 1657-1663.
3. Lu MT, et al. Axial and reformatted four-chamber right ventricle-to-left ventricle diameter ratios on pulmonary CT angiography as predictors of death after acute pulmonary embolism. *AJR* 2012; 198: 1353-1360.
4. Kumamaru KK, et al. Normal ventricular diameter ratio on CT provides adequate assessment for critical right ventricular strain among patients with acute pulmonary embolism. *Int J Cardiovasc Imaging* 2016; 32: 1153-1161.
5. Konstantinides SV. 2014 ESC Guidelines on the diagnosis and management of acute pulmonary embolism. *Eur Heart J* 2014; 35: 3145-6