

# Imaging of Total Knee Arthroplasty

Kevin R. Math, M.D.,<sup>1,2</sup> Syed Furqan Zaidi, M.D.,<sup>1,2</sup>  
Catherine Petchprapa, M.D.,<sup>1,2</sup> and Steven F. Harwin, M.D., F.A.C.S.<sup>3,4</sup>

## ABSTRACT

Painful total knee arthroplasty (TKA) represents a diagnostic challenge for the clinician and radiologist, as there is a wide variety of potential etiologies, with a broad range of clinical presentations, and the abnormalities on imaging studies are often subtle, absent, or nonspecific. Imaging findings of normal TKA are reviewed, in addition to a variety of complications such as loosening, infection, instability, osteolysis, heterotopic ossification, extensor mechanism disruption, and fracture. Although imaging evaluation of painful TKA is usually limited to conventional radiographs and nuclear imaging, examples of the utility of computed tomography are also illustrated, and suggested imaging strategies and algorithms are discussed.

**KEYWORDS:** Total knee arthroplasty, complications, total knee replacement, joint replacement

The knee and the hip are the most commonly replaced joints, and the annual number of total knee replacements continues to increase steadily. Over 350,000 total knee arthroplasty procedures are performed in the United States per year, about 10% of which are revision surgeries.<sup>1</sup>

The most common indications for total knee arthroplasty (TKA) are severe degenerative joint disease and advanced inflammatory arthritis; the surgery serves to relieve the often associated debilitating pain and deformity and to improve function and stability of the knee. Contraindications to TKA include neuropathic arthropathy and inadequately treated infection. Advances in prosthetic design and surgical technique have resulted in progressive improvement in function and survivorship of total knee replacements, with a 15-year survivorship of about 95%.

## PROSTHETIC DESIGN

### General Prosthetic Types

In a TKA, the three articular surfaces of the knee (tibial, femoral, and patellar) are resurfaced by placing three corresponding prosthetic components. The tibial component consists of a high-density polyethylene spacer fixed either to a metal tibial tray or to an interchangeable modular insert. The femoral component is a metallic component with rounded surfaces mimicking the normal femoral condylar contours. The patellar component is usually made up of high-density polyethylene but can also be metal backed. These components may be fixed with or without cement (polymethylmethacrylate [PMMA]), although all components of TKA are now most often cemented. Cementless designs rely on ingrowth of bone into

An Update on Imaging of Joint Reconstructions; Editors in Chief, David Karasick, M.D., Mark E. Schweitzer, M.D.; Guest Editor, Theodore T. Miller, M.D. *Seminars in Musculoskeletal Radiology*, Volume 10, Number 1, 2006. Address for correspondence and reprint requests: Kevin R. Math, M.D., Chief of Musculoskeletal Radiology, Division of Musculoskeletal Radiology, Beth Israel Medical Center, 435 2nd Avenue, New York, NY 10010. <sup>1</sup>Division of Musculoskeletal Imaging, Beth Israel Medical Center, New York, NY; <sup>2</sup>Department of Radiology, Albert Einstein College of Medicine, Bronx, New York; <sup>3</sup>Department of Orthopaedic Surgery, Beth Israel Medical Center, New York, NY; <sup>4</sup>Department of Orthopaedic Surgery, Albert Einstein College of Medicine, Bronx, New York. Copyright © 2006 by Thieme Medical Publishers, Inc., 333 Seventh Avenue, New York, NY 10001, USA. Tel: +1(212) 584-4662. 1089-7860,p;2006,10,01,047,063,ftx,en;smr00385x.

the prosthesis that is initially held in place by friction (press fit).

There are over 150 different knee implant designs in current use. Types of knee replacements are broadly characterized by the number of resurfaced compartments (unicompartmental or TKA), their degree of constraint, fixation of the polyethylene spacer, and whether or not the posterior cruciate ligament (PCL) has been retained or removed [cruciate retaining (CR) versus posteriorly stabilized, cruciate substituting (PS)].

### Constrained Versus Unconstrained Prosthesis

Prostheses are categorized by the degree of inherent mechanical stability or constraint. So-called unconstrained prostheses are the most widely used today and rely on the supporting soft tissues to stabilize the independent femoral, tibial, and patellar components. Increasing degrees of constraint have improved stability at the expense of decreased range of motion. Semiconstrained designs with closely conforming femoral and tibial components have decreased range of motion of the joint, and totally constrained designs (e.g., constrained condylar knee replacement [CCK]) have closely linked femoral and tibial components with further decrease in amount of freedom at the joint. Constrained designs are most commonly utilized in revision arthroplasty or in the presence of significant ligament instability. They rely on an enlarged post and cam mechanism to afford medial and lateral as well as posterior stability. However, their rigid design increases the forces borne by nondeformable elements rather than dissipated by soft tissues. Thus, they are more susceptible to loosening, fatigue, and wear than less constrained designs.

### Fixed Bearing Versus Mobile (Meniscal) Bearing

Implant designs in which the polyethylene (PE) spacer is rigidly fixed to the tibial tray are called *fixed bearing*. The metallic femoral component glides across the surface of the fixed PE insert during the range of motion.

Mobile or meniscal bearing prostheses consist of metallic femoral and tibial components and a mobile PE insert that can glide along the smooth surface of the tibial component during range of motion. A mobile PE insert effectively provides both tibial and femoral surfaces with which to distribute load as well as theoretically allowing greater and more natural range of motion. The femoral surface of the PE spacer is contoured to the femoral condyles to provide a more conforming articulation. Although theoretically possible, increased range of motion and less PE wear have not been proved clinically.

### PCL Retaining Versus PCL Substituting/Sacrificing

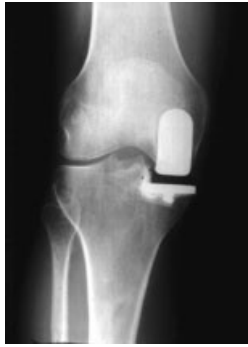The PCL is an important knee stabilizer and may be retained, sacrificed, or substituted for during knee arthroplasty. The decision concerning the fate of the PCL in knee arthroplasty is largely a matter of individual preference and experience of the orthopedic surgeon; both types have advantages and disadvantages, and there is no clear consensus as to which has better results.<sup>2-5</sup> In cases in which the PCL is resected at the time of surgery, the orthopedist utilizes a prosthesis specifically designed to substitute for the PCL ("posterior stabilized" or "PCL substituting"). PCL stabilizing designs feature a tibial post that articulates with a femoral cam, allowing controlled femoral rollback during knee flexion. Retention of the PCL requires balancing the ligament to ensure that it is not overly tight (recession) so that increased rollback does not occur. Should that happen, range of motion is decreased and increased PE wear may ensue.

### Unicondylar Arthroplasty

Patients with single compartment disease may be treated with a proximal (or high) tibial osteotomy (HTO) or unicondylar (unicompartmental) arthroplasty.<sup>6</sup> Active debate continues within the orthopaedic community regarding the use of unicondylar prostheses versus HTO.<sup>6</sup> Historically, because of the inherent limited life span of implants, young, active patients were treated with HTO, which theoretically corrects malalignment and redistributes loads to surfaces with healthier articular cartilage. Although an osteotomy can delay the need for a prosthesis for almost 10 years, patients unfortunately usually do not return to their desired level of activity and the procedure can be cosmetically unappealing. Although unicompartmental disease may be most evident from the radiographs leading the orthopedist to recommend HTO, less apparent degenerative changes often coexist at other compartments as well; cartilage biopsy of the "uninvolved compartments" often shows significant degeneration. Many patients already have patellofemoral changes at the time of surgery and continue to have anterior knee pain following HTO.

A unicompartmental arthroplasty resurfaces a single compartment, most commonly performed for "isolated" medial compartment disease (Fig. 1). As with a TKA, the prosthesis may be fixed or mobile bearing. The anterior cruciate ligament (ACL) and PCL are always preserved in these procedures; therefore, more physiologic kinematics are possible. ACL deficiency is a relative contraindication to unicondylar replacement.

As an alternative to HTO, unicompartmental arthroplasty is associated with a shorter recovery time; there has therefore been renewed interest in this less extensive procedure over the past decade, particularly



**Figure 1** Medial unicompartmental knee arthroplasty. AP view: the prosthesis replaces the medial tibiofemoral compartment joint space.

with the emergence of minimally invasive surgical techniques.

### Minimally Invasive TKA

Classical surgical exposure for knee arthroplasty requires a long (10–12 cm) skin incision that violates the vastus medialis muscle and medial quadriceps tendon. A parapatellar approach, with dissection along the medial margin of the vastus medialis, requires an equally long incision. The development of specialized tools and instruments has allowed arthroplasty to be performed through a smaller incision (8–10 cm) that does not involve the quadriceps tendon. These are called quadriceps sparing procedures, and because there is less trauma to the parapatellar soft tissues, there is a faster recovery time, a more rapid return of function, and a decrease in intraoperative blood loss. The procedure is technically demanding and has not been evaluated in the long term. Early reports show theoretical advantages, but wound complications and component malposition are concerns.

### RADIOGRAPHIC EVALUATION

Before discussing imaging of complications of TKA, it is important to review the optimal appearance of TKA on postoperative and follow-up radiographs, with regard to the proper alignment of the components.

Routine views of the knee are the anteroposterior (AP), lateral, and tangential axial (Merchant) views (Fig. 2). As with preoperative radiographs, it is important to attempt to obtain the AP film with the patient weight bearing, as this more accurately depicts the joint space of the TKA as well as PE wear with resultant joint space narrowing. The components must be included in their entirety on all views, including any stems or stem extensions. The three foot standing view of the lower extremities (“three joint view,” with the hip, knee, and ankle on the same plate) may be helpful for preoperative planning, for assessment of the anatomic and mechanical axes, and postoperatively to confirm proper anatomic postoperative alignment of the lower extremity. A line drawn from the center of the hip to the center of the talar dome should pass through the center of the knee prosthesis.

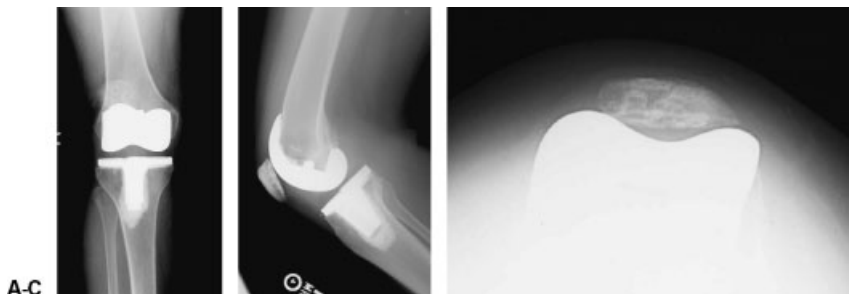
### Alignment

#### AP VIEW

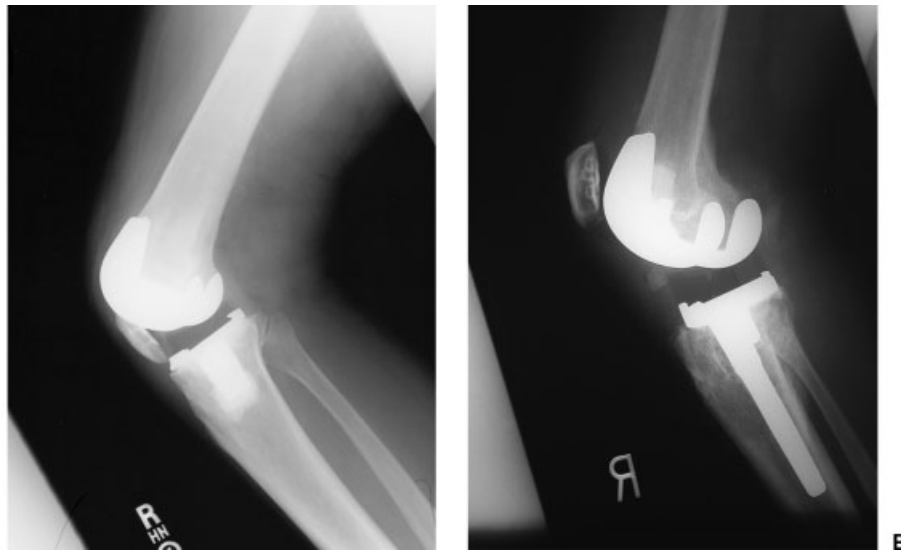
On the AP view the mechanical axis should be corrected to 0 degrees, as already described. This usually results in the femoral component being placed in 5 to 9 degrees of valgus alignment relative to the long axis of the femur.<sup>7</sup> The tibial component is then aligned perpendicular to the long axis of the tibia or at slightly less than 90 degrees, depending on the preoperative measurements.<sup>8</sup> The PE joint space should be equivalent medially and laterally (although this is not always reliable and depends on beam angle and patient’s positioning). A narrowed or absent PE joint space may simply be a consequence of a flexion contracture of the knee, with the patient unable to extend fully.

#### LATERAL VIEW

On the lateral view the femoral component should be perpendicular to the long axis of the femur, but some surgeons choose to flex the component up to 3 degrees.<sup>7,8</sup> The tibial component should be perpendicular to the long axis of the tibia or up to 5 degrees posteriorly inclined.<sup>9</sup> The anterior and articular sides of the patella should be seen parallel to each other and well defined.



**Figure 2** Normal TKA. (A) AP, (B) lateral, (C) Merchant views.



**Figure 3** (A) Patella baja. The patella is low in position because of quadriceps tendon rupture. (B) Patella alta. There is patellar tendon rupture with resultant patella alta.

If the femur and tibia are seen as a true lateral view and the patella is seen obliquely, patellar subluxation may present. There is often patella baja following TKA, but significant patella baja or patella alta can result from quadriceps tendon rupture or patellar tendon rupture, respectively (Fig. 3).

#### TANGENTIAL AXIAL VIEW

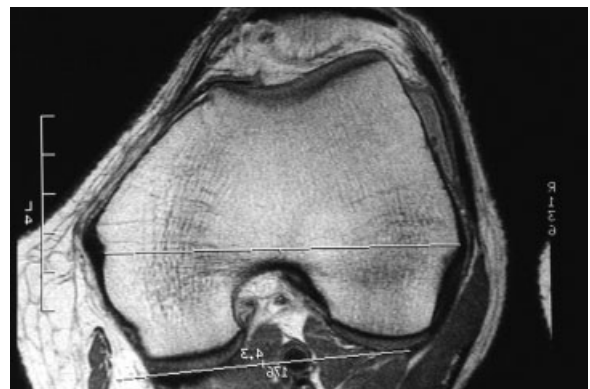The tangential axial view is important for assessing patellofemoral alignment, particularly because patellofemoral complications are among the most common causes of a painful TKA and the most common reason for revision surgery.<sup>10</sup> The prosthetic patellar component should be centered over the middle of the trochlea of the femoral component. Etiologies of lateral patellar subluxation include preexisting subluxation as in a valgus knee or abnormal axial (internal) rotation of the femoral or tibial components. The view should be performed at a standard degree of flexion, usually 30 to 45 degrees.

#### ROTATIONAL ALIGNMENT OF THE COMPONENTS

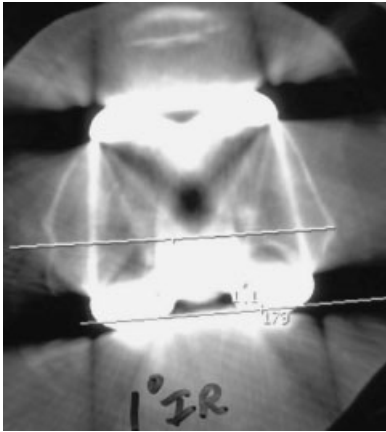
Proper rotational alignment of the femoral and tibial components (in the axial plane) is essential to ensure optimal results of TKA. Whereas varus or valgus component alignment or anterior and posterior component inclination is readily assessed on routine radiographs, rotational alignment of the components is best assessed on cross-sectional images, using computed tomography (CT), where the necessary landmarks are clearly depicted.<sup>6</sup> Rotational malalignment can be suggested if a true AP view of one component is seen and the other is seen as an oblique view.

Many orthopedic surgeons use the medial and lateral epicondyles of the distal femur as surgical ana-

tomic landmarks during knee TKA (Fig. 4). The medial epicondyle serves as the attachment site for the medial collateral ligament and has the CT appearance of an elongated shallow "W"; there are two small peaks and an intervening sulcus.<sup>11</sup> The lateral epicondyle is the attachment site of the fibular collateral ligament and is a focal bony prominence with a well-defined peak. The transepicondylar axis (TEA) is a line that extends from the peak of the lateral epicondyle to the sulcus of the medial epicondyles and is thought to represent the center of rotation of the knee.<sup>12</sup> Utilizing one of the two small medial ridges as a medial epicondyle landmark rather than the sulcus results in an erroneous angle of up to 3 degrees. Internal rotation of the femoral or tibial components has been shown to be associated with complications that include abnormal patellar tracking (and resultant anterior knee pain) and PE wear, but



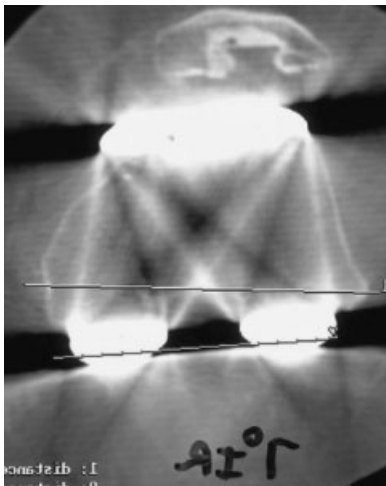
**Figure 4** Anatomy of the transepicondylar axis (TEA). Axial MR image through the femoral condyles shows a peaked configuration of the lateral condyle and the "shallow W" configuration of the medial condyle. The TEA extends from the sulcus of the medial condyle to the peak of the lateral condyle.



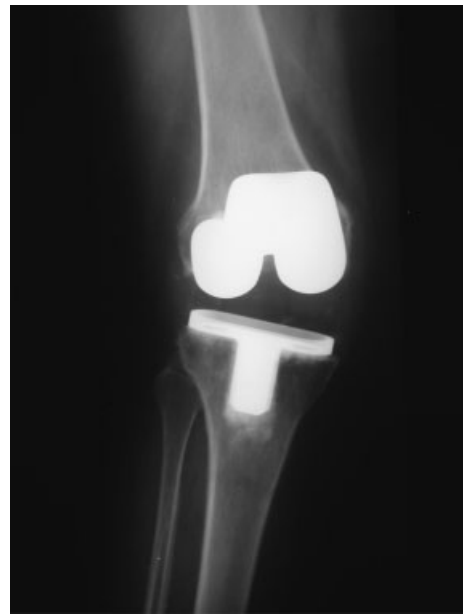**Figure 5** CT assessment of femoral component rotational alignment. A line drawn across the posterior margins of the posterior femoral components should be parallel with the TEA. This patient has 1 degree of internal rotation of the femoral component.

external rotation of the femoral component is usually well tolerated.<sup>13–16</sup>

Because the most challenging task on CT (and at surgery) is identifying the medial epicondyle and sulcus, the axial image that best depicts this anatomy should be chosen for measurement (Fig. 5). A line drawn along the posterior margin of the femoral component, bordering the prosthetic femoral condyles, should be parallel to the TEA.<sup>15</sup> If the lines diverge medially, the component is externally rotated, which can cause an increased medial flexion gap and result in flexion instability. If they diverge laterally, the component is internally rotated and early or delayed patellofemoral problems may ensue, particularly if the internal rotation is greater than 5 degrees<sup>15</sup> (Fig. 6).



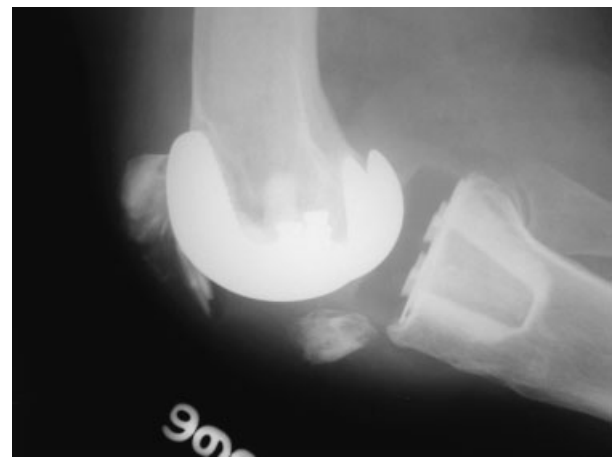
**Figure 6** Internal rotation of femoral component. This CT image demonstrates 7 degrees of internal rotation of the femoral component relative to the TEA. Note the secondary lateral patellar subluxation.



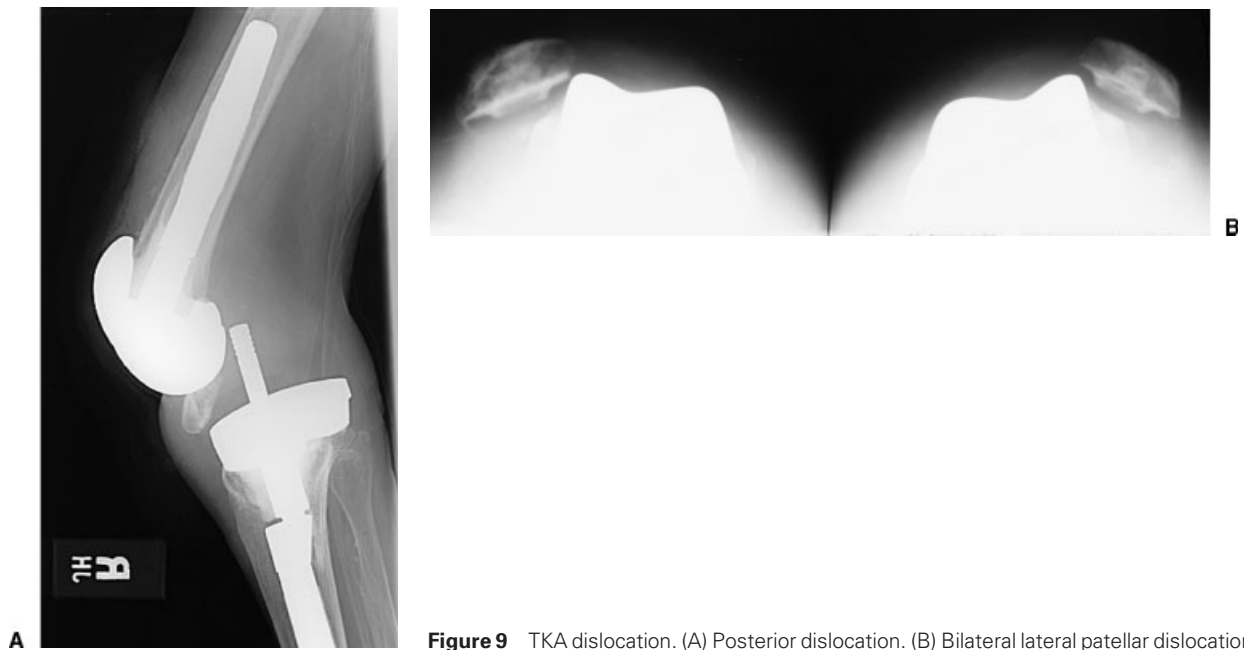**Figure 7** Medial instability. There is accentuated valgus alignment of the knee with widening of the medial joint compartment indicating valgus instability.

## COMPLICATIONS

The most common complications of TKA are patellofemoral malalignment, instability (Fig. 7), loosening, infection, PE wear with or without “particle disease (osteolysis),” and instability. Other less common causes of a painful TKA include periprosthetic fracture (Fig. 8), dislocation (Fig. 9), reflex sympathetic dystrophy, and heterotopic ossification. Dislocation is an uncommon complication of TKA and is readily diagnosed on conventional radiographs. As with any knee dislocation, these injuries may be associated with injury to the popliteal vessels. Heterotopic ossification is common following hip and knee arthroplasty and is



**Figure 8** Patellar fracture. There is periprosthetic patellar fracture with significant distraction of the fragments.

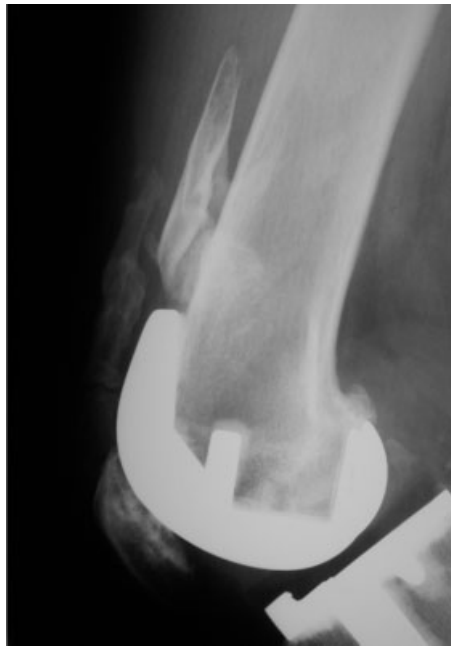

**Figure 9** TKA dislocation. (A) Posterior dislocation. (B) Bilateral lateral patellar dislocation.

rarely symptomatic (Fig. 10). Rarely, extensive heterotopic ossification can bridge the joint and cause ankylosis or limited range of motion.

### Loosening

The two radiographic hallmarks of component loosening are a wide or progressive zone of radiolucency at the interfaces around the components and an interval change in position of the components.<sup>7,9</sup>



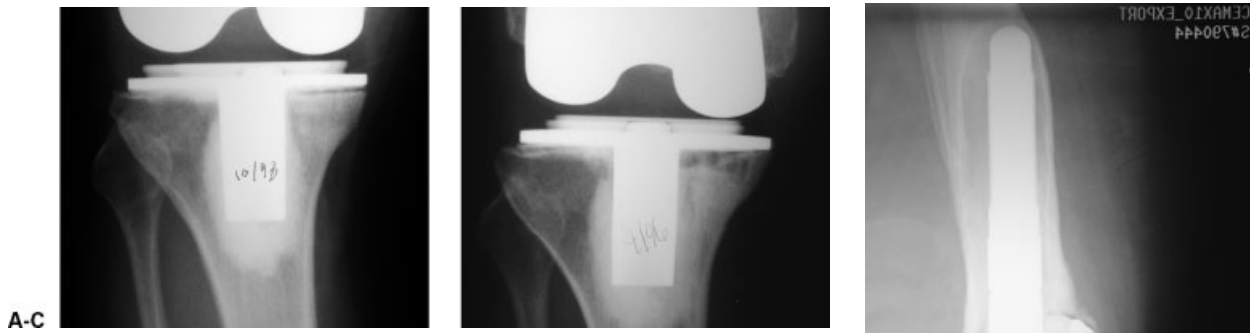
**Figure 10** Heterotopic ossification. Note the mature bone anterior to the distal femoral shaft representing heterotopic ossification.

### Periprosthetic Lucency

It is important to note that “lucency” and “loosening” are not interchangeable or equivalent terms. It is fairly common to see periprosthetic nonprogressive lucent zones at the interfaces on follow-up radiographs in asymptomatic patients that are of no clinical significance. This is particularly so in patients with revision arthroplasty, where fibrous tissue at the interfaces gives rise to a wide lucent zone that is not pathologic. Periprosthetic lucency can also be seen in a phenomenon known as “stress shielding.” This phenomenon occurs where bone is resorbed at areas that are no longer subjected to weight-bearing stress following arthroplasty, secondary to redistribution of load and stress being diverted from the area. Stress shielding typically occurs within the first 1 to 2 years following joint arthroplasty and is most commonly seen underlying the anterior and posterior flanges of the femoral component or beneath the tibial tray, and it typically remains radiographically stable on sequential examinations. Stress shielding is more commonly seen in total hip than total knee arthroplasty.

A standardized grading system has been formulated by the Knee Society ascribing specific zone numbers to the periprosthetic interfaces, thereby standardizing the grading and description of these lucent zones.<sup>17</sup> Although these lucent zones may be due to the previously described noncomplicating factors, the following findings increase their specificity for component loosening (Fig. 11):

1. Progressive widening of lucent zone on sequential studies.<sup>7</sup>
2. Greater than 2 mm lucency at cement-bone interface or any lucency at the metal-cement



**Figure 11** (A, B) Loosening of tibial component—progressive lucency. There is a narrow zone of lucency underlying the tibial component in (A) that progresses to a wider zone, particularly medially in (B), over a 3-year period. (C) Loose femoral component. There is a wide zone of lucency surrounding the femoral stem of the TKA with anterior migration of the tip of the stem.

interface or metal-bone interface (in noncemented prostheses).<sup>18</sup>

3. The wider and more extensive the zone(s) of lucency, the more likely they reflect loosening, particularly if the lucency surrounds the tibial stem or pegs.

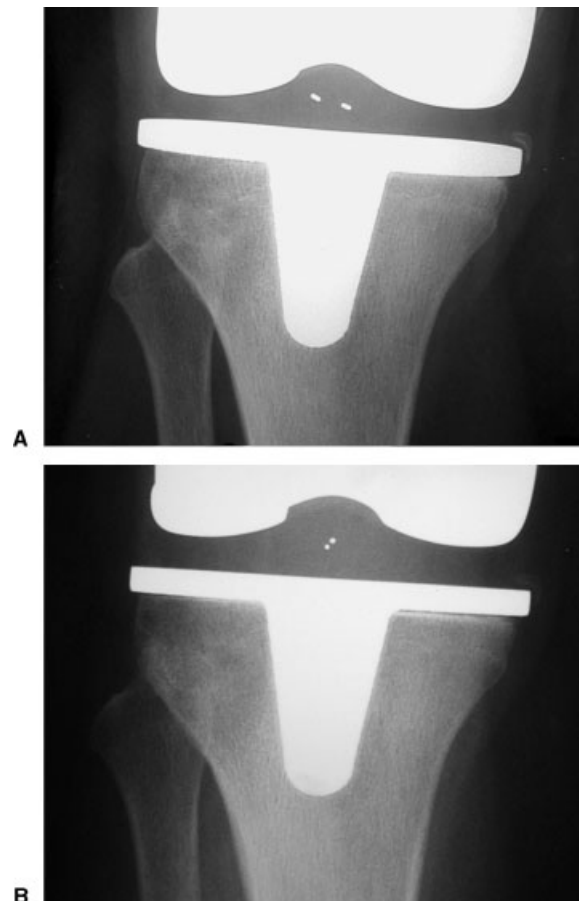
In view of the importance of assessing periprosthetic lucent zones, a fluoroscopically obtained AP view may be helpful in detecting subtle lucencies that can be missed if the x-ray beam is not tangential to the prosthetic interface<sup>9,19</sup> (Fig. 12).

### Change in Component Position

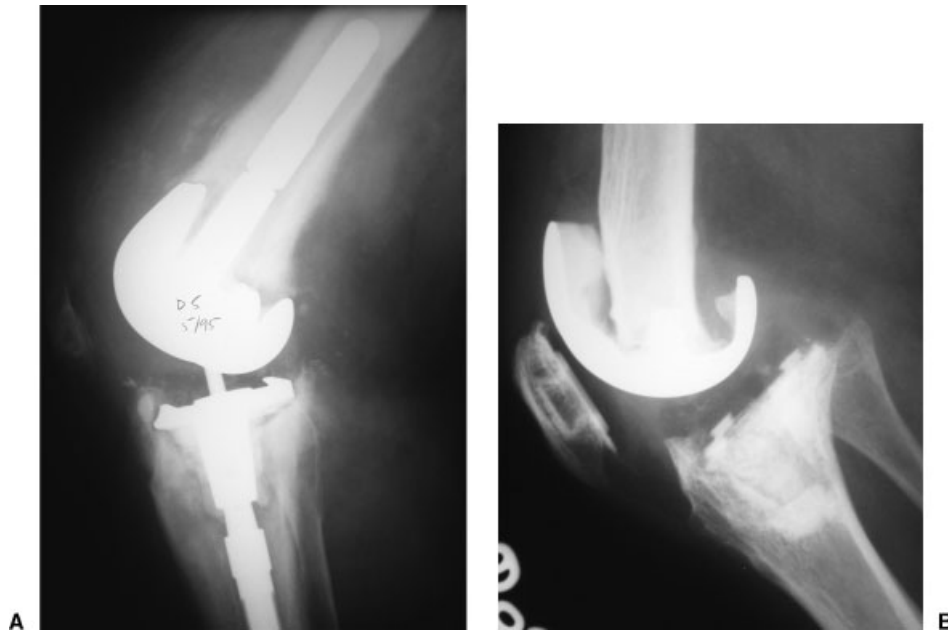
Change in component position is a reliable indicator of component loosening. In tibial component loosening, the tibial tray can sink into the tibial plateau (“subsidence”) with a rim of bone at its margins<sup>7</sup> (Fig. 13). Furthermore, a loose tibial component typically shifts into varus alignment relative to the long axis of the tibia (i.e., the tibial shaft points toward the midline relative to the tibial component) (Fig. 14). The femoral component fails less commonly than the tibial component and often shifts into a flexed position on the lateral view relative to the long axis of the femur (Fig. 15). A loose PE patellar component may dissociate from the patella and change in position or can become a loose body in the joint (Fig. 16).

### Osteolysis

Also known as particle disease and aggressive granulomatosis, osteolysis is due to a foreign body granulomatous reaction to the PE wear debris particles and less commonly a reaction to cement or metal particles<sup>20,21</sup>



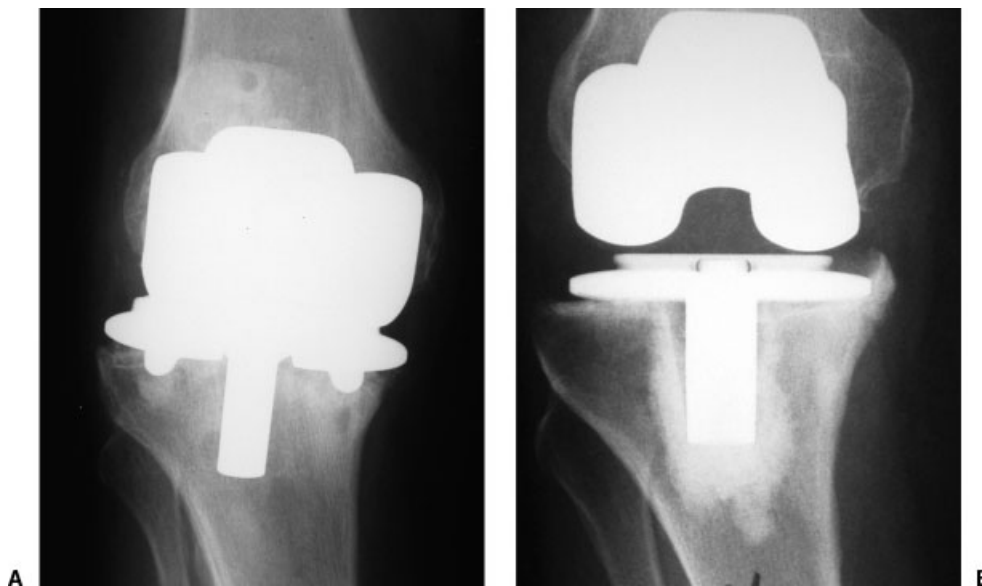
**Figure 12** Utility of fluoroscopically guided AP view. (A) Tibial component appears normal on a standard AP view. (B) A clinically significant lucent zone is detected on the fluoroscopically guided AP view reflecting early loosening.



**Figure 13** (A) Infected TKA. There is diffuse periostitis at the distal femur and subsidence (loosening) of the tibial component. (B) Loose femoral component. There is marked periprosthetic lucency surrounding the loose femoral component, which has shifted into mild flexion relative to the femur. There is also subsidence (loosening) of the polyethylene tibial component, anteriorly.

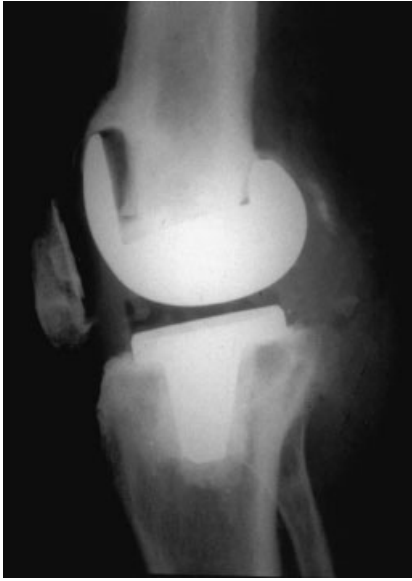(Fig. 17). This process usually becomes symptomatic 4 to 5 years after arthroplasty and is less commonly seen earlier, rarely before 2 years.<sup>22</sup> Initially, patients have synovitis, joint effusion and pain secondary to the inflammatory process. This intra-articular synovial process may progress to bone erosion at the margins of the prosthesis and can result in variable-sized lytic lesions that may progress to loosen the implant and rarely to cause pathologic fracture.<sup>23</sup> The inflammatory process

dissects through the interfaces of the prosthesis, sometimes causing lytic lesions that are remote from the involved joint surfaces. The discrete focal lytic lesions associated with osteolysis usually differ from the broad less well-defined lucent zones associated with loosening that are parallel to the interfaces (Fig. 18). As PE wear progresses, the friction of repetitive direct contact of the metal femoral and tibial components may give rise to metal debris (metallosis), and the metal particles often



**Figure 14** Loose tibial components. (A) and (B) in different patients. Both demonstrate secondary varus alignment of tibia. Note the abnormal lucency at the lateral aspect of the tibial stem in (A).





**Figure 15** Loose femoral component. Note the abnormal lucency lining the anterior flange of the femoral component that has shifted into flexion relative to the distal femur.

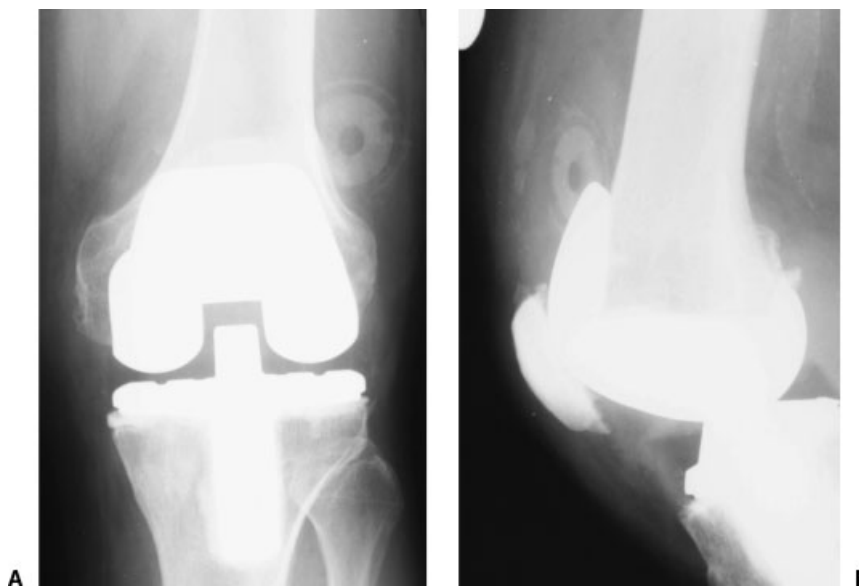
surround the components resulting in an “arthrogram effect” (Fig. 19). Screw holes in the tibia serve as avenues for the spread of the inflammatory process into the bone and subsequent bone destruction (“screw osteolysis”), and repeated weight-bearing stress on the joint accelerates progression of this type of osteolysis.<sup>22</sup> Although osteolysis has been implicated as an important cause of prosthesis component loosening, the majority of components involved by surrounding osteolytic lesions are well fixed.

Conventional radiographs are insensitive for detecting osteolytic lesions, and clinically significant osteolytic lesions can often be radiographically occult on plain films. CT has proved to be highly accurate for demonstrating the presence and extent of these lesions in addition to revealing other abnormalities (Fig. 20). In our series, only one third of osteolytic lesions detected on CT were identified prospectively on routine radiographs. By the time the process is detected on plain films, the lesions are often large and the disease relatively advanced. In fact, CT commonly shows early osteolytic lesions that are asymptomatic and often incidental findings.

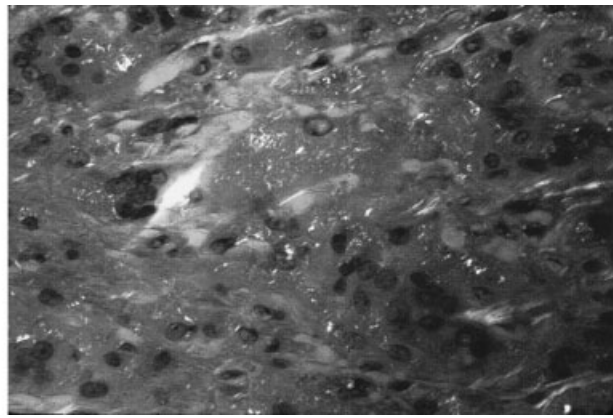
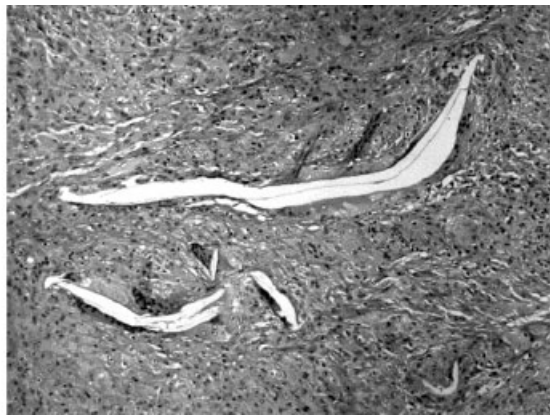
### Infection

Infection is a devastating complication of total joint arthroplasty, and fortunately its incidence is quite low. Prosthetic components are a target for bacterial seeding owing to their bulk of foreign material and biofilm (slime coat). As with prosthetic heart valve patients, antibiotic prophylaxis in this population is crucial. The incidence of infected TKA is 0.5 to 2%,<sup>24–26</sup> but it is higher (up to 10%) in revision arthroplasty as well as in patients with collagen vascular diseases taking steroids and with other chronic medical problems such as diabetes.<sup>24,27</sup>

Patients with infected TKA may present with acute infection and any of the classic signs of acute inflammation but more often have a chronic, indolent process with vague pain or loosening. Some cases of simple loosening may in fact be subclinical infection, in which the organism cannot be isolated, even on aspiration. Therefore, imaging techniques are important adjuncts to the clinician.



**Figure 16** Loose patellar component. (A) AP and (B) lateral views demonstrate a loose and disassociated patellar component that has migrated to the lateral suprapatellar pouch.



**Figure 17** Histopathology of osteolysis. (A) H&E staining demonstrates large linear polyethylene particles with surrounding multinucleated giant cell reaction. (B) Polyethylene particles are bright on polarized light microscopy.

Clinically, the diagnosis of infected TKA is made using a combination of history and physical findings, serologic tests, joint aspiration, and imaging studies. Factors that increase the likelihood of infection include leukocytosis and elevated C-reactive protein and/or elevated erythrocyte sedimentation rate (both acute-phase reactants).<sup>28</sup> The joint aspirate is sent for routine Gram stain, culture and sensitivity, and cell count. Unfortunately, these diagnostic studies are often equivocal or nonspecific, and supplemental advanced imaging studies are necessary for making the diagnosis.<sup>29,30</sup> Plain films of infected TKA are often normal or reveal nonspecific soft tissue swelling. Other plain film findings vary in their specificity for infection.

Radiographic signs of infected TKA—high specificity:

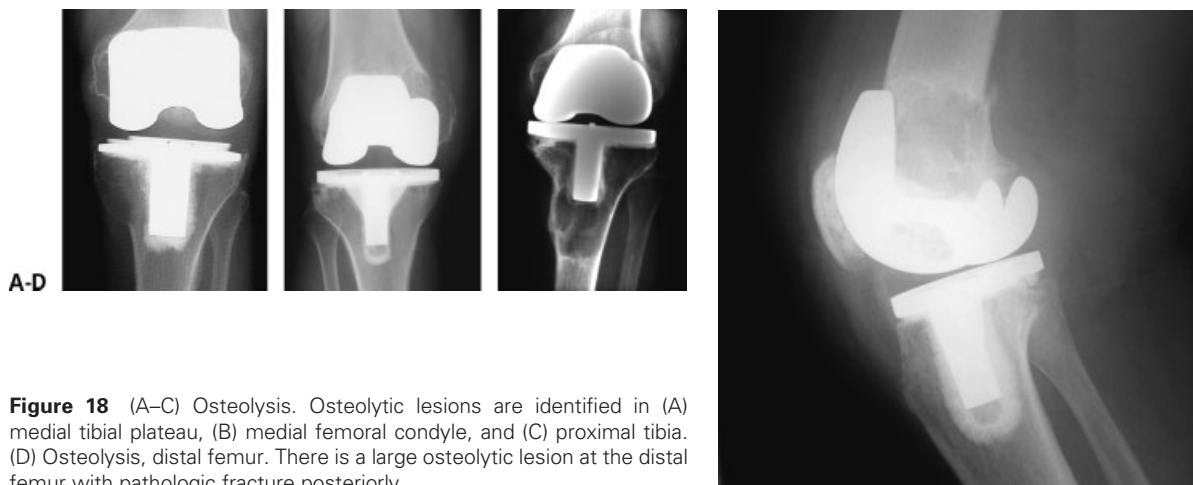
1. Soft tissue gas, secondary to a gas-forming organism. This is a rare finding (Fig. 21).
2. Periosteal reaction; typically the periostitis has an active, immature, irregular appearance, often

with extensive wavy irregular periosteal new bone (Fig. 22).

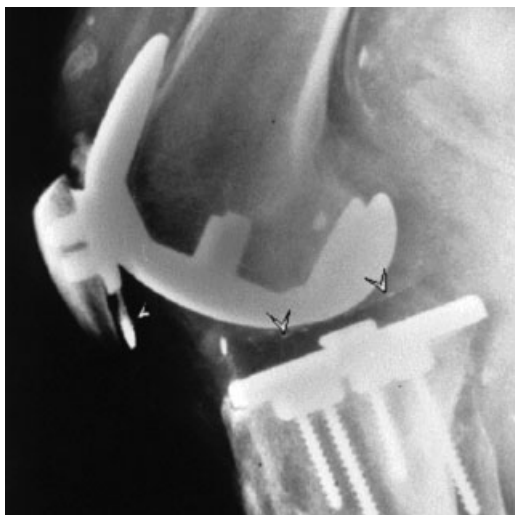
Radiographic signs of infected TKA—low specificity:

1. Soft tissue swelling.
2. Periprosthetic lucency, reflecting erosions, typically at the margins of the prosthesis (Fig. 23).
3. Component loosening—must be differentiated from aseptic (mechanical) loosening (Fig. 24).

Nuclear scans are extremely helpful in diagnosing loosening or infection and for clarifying equivocal imaging studies. The three studies most commonly utilized for evaluating the painful TKA are the triple-phase bone scan (TPBS), the indium-111 leukocyte scan, and the technetium sulfur colloid (Tc-SC) bone marrow scan.<sup>31</sup> Each of these scans performed independently has limited utility, and we perform all three scans as part of every painful TKA workup.



**Figure 18** (A–C) Osteolysis. Osteolytic lesions are identified in (A) medial tibial plateau, (B) medial femoral condyle, and (C) proximal tibia. (D) Osteolysis, distal femur. There is a large osteolytic lesion at the distal femur with pathologic fracture posteriorly.



**Figure 19** TKA with metallosis. Note the metal debris outlining the upper margin of the tibial polyethylene implant and posterior margin of the femoral component at the lower pole (arrowheads) resulting in an arthrogram effect.

#### TRIPLE-PHASE BONE SCAN

TPBS has demonstrated high sensitivity but poor specificity for most pathologic processes of the skeletal system, including complications of TKA. Increased uptake on the first and second phases of the scan signifies hyperemia and increased blood pool uptake, respectively, and these findings are nonspecific.<sup>31</sup> Physiologic increased uptake in association with a TKA can persist in the normal setting for up to 1 year after surgery on the first two phases and indefinitely on the third (skeletal) phase,<sup>31</sup> limiting the specificity of a “hot” bone scan. This differs from findings for hip replacements, where the uptake on the third phase typically normalizes within 1 year following surgery. The scintigraphic sign of component loosening is increased periprosthetic uptake, and more extensive or more intense uptake around the components is associated with a higher likelihood of loosening (Fig. 25).

The characteristic bone scan findings of infected TKA are increased uptake on all three phases of the scan, and therefore the lack of increased uptake on the first two phases is an important negative finding that would militate against the diagnosis of infection.<sup>31</sup> The TPBS is extremely sensitive for infected TKA, with a sensitivity of 95%, but the specificity is poor.<sup>32-34</sup> Furthermore, osteolysis/synovitis from PE wear debris usually gives rise to the same bone scan findings as infection on TPBS and can also mimic infection clinically.<sup>31</sup> Therefore, the primary utility of the bone scan in TKA patients is for evaluation for loosening rather than infection, and evaluation is facilitated if the patient has a contralateral asymptomatic TKA as a control for comparison (Fig. 25). We have found uptake surrounding the tibial stem or femoral stem to

be more specific for loosening than uptake underlying the tibial tray.

In view of the inherent lack of specificity of increased uptake on a TPBS, inflammation-specific imaging with an indium-labeled leukocyte scan combined with a Tc-SC marrow scan is essential in the imaging evaluation of a painful TKA.

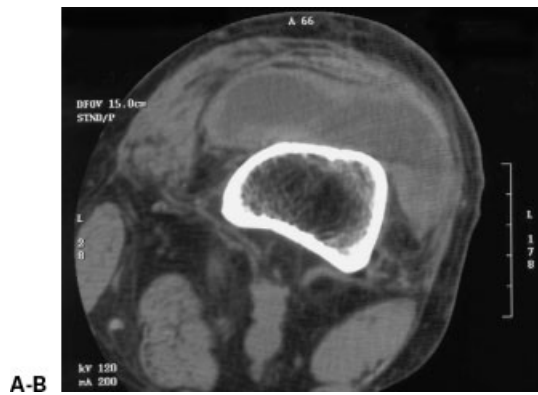
#### INDIUM-111 LEUKOCYTE SCAN

This study has become the most widely used for evaluating for suspected infected joint arthroplasty; gallium scanning is less sensitive for acute infectious processes and has essentially been replaced by indium-labeled white blood cell (WBC) scanning. Indium-labeled leukocytes accumulate in areas of inflammation or infection or postoperative healing wounds. In addition, the marrow surrounding the implanted joint prostheses has been shown to have hyperplastic elements that often result in physiologic increased periprosthetic indium uptake in the normal postoperative state.<sup>35</sup> In fact, increased uptake around normal asymptomatic implants has been shown to be present in about 50% of TKA patients,<sup>35</sup> resulting in a poor positive predictive value for infection. However, the sensitivity and negative predictive value of indium WBC scanning for infection are both very high, approaching 95% and 100%, respectively.<sup>35,36</sup> Thus, a negative indium scan is a strong predictor of the absence of infected TKA, but a positive indium scan, in and of itself, is of limited value. It is therefore important to compare positive indium scans with a Tc-SC marrow scan to improve the accuracy and specificity of the study.

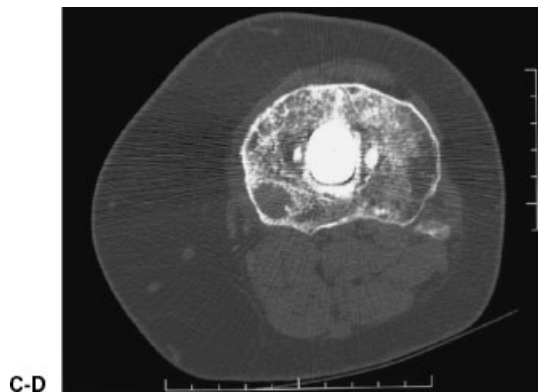
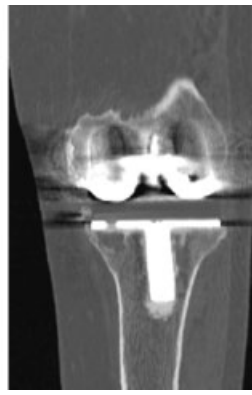#### TECHNETIUM 99 SULFUR COLLOID MARROW SCAN

Sulfur colloid accumulates throughout the reticuloendothelial system, in the bone marrow, and in the liver and the spleen. Therefore, the normally encountered hyperplastic/aberrant marrow surrounding joint replacements giving rise to increased indium uptake should have corresponding matching increased uptake on the marrow scan<sup>37</sup> (Fig. 26). Alternatively, if infection is the cause of increased periprosthetic indium uptake, marrow uptake of sulfur colloid by the infected marrow is inhibited or diminished, resulting in relatively less uptake on the marrow scan in areas of periprosthetic infection<sup>38,39</sup> and a resultant mismatch (Fig. 27). Thus, if the indium and marrow scans match, they are considered “congruent” and congruent scans carry a low likelihood of infection. If there is a mismatch, where the areas of increased uptake on the indium scan are normal or “cold” on the marrow scan, the findings are considered “incongruent,” and these findings correlate with a high likelihood (> 90%) of infection.<sup>36</sup>

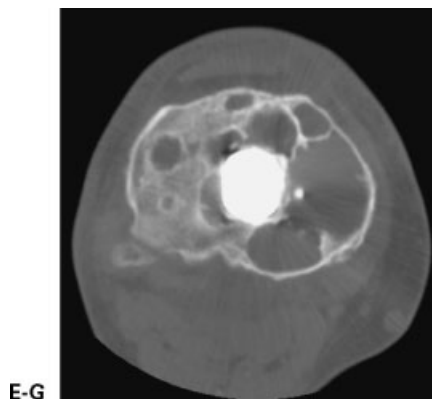
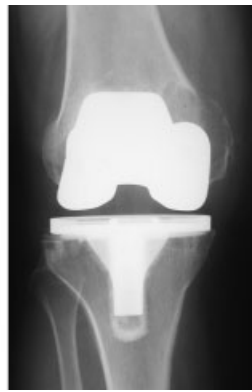Once the diagnosis of infected TKA is made, the prosthesis must be removed (resection arthroplasty), and antibiotic-impregnated cement is placed in the joint



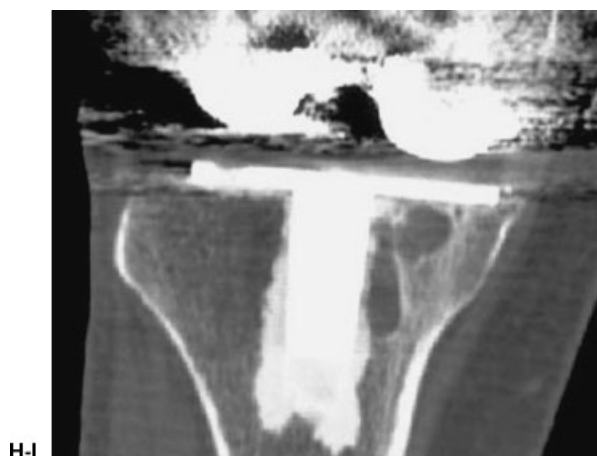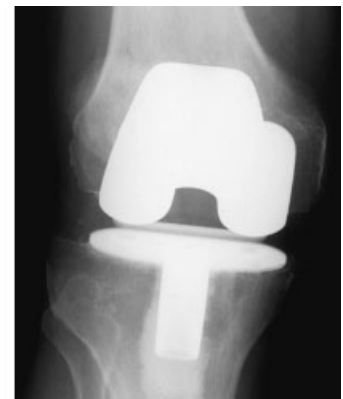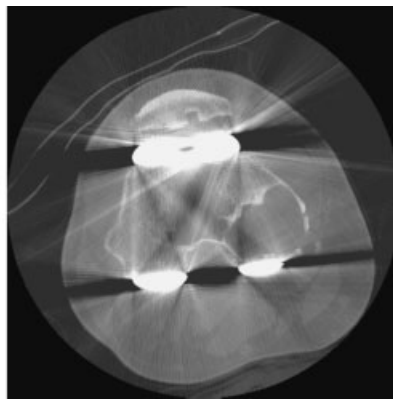
A-B



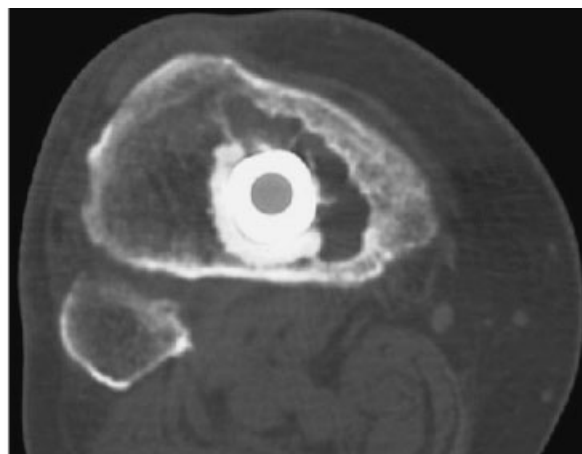
C-D



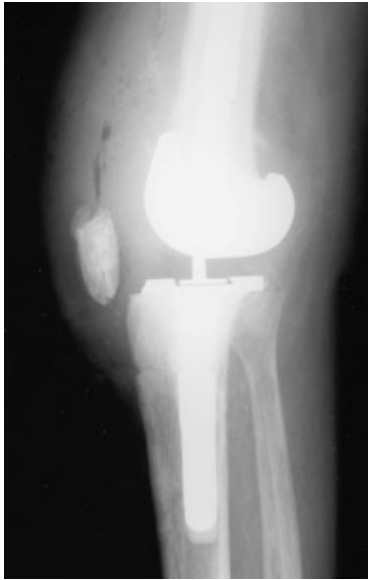E-G



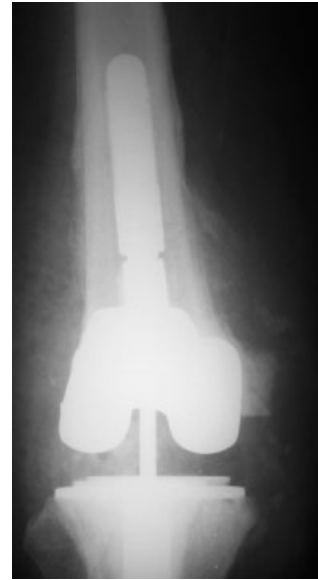H-I



**Figure 20** Osteolysis—CT findings. (A) There is a large suprapatellar joint effusion and synovial thickening secondary to diffuse synovitis. (B) Axial and (C) coronal reformatted images demonstrate a focal osteolytic lesion at the posterior aspect of medial tibial plateau directly underlying the screw hole in the tibial tray. (D) Axial CT image through proximal tibia demonstrates a large osteolytic lesion in the medial tibial plateau. (E) This area was less conspicuous on the AP view of the knee, where a large medial femoral condyle osteolytic lesion was seen. (F) There is a large osteolytic lesion in the medial femoral condyle with penetration of the posteromedial cortex. (G) Axial and (H) coronal reformatted CT images reveal a crescentic area of osteolysis in the medial tibial plateau that was not evident on (I) the AP view of the knee.



**Figure 21** Infected TKA with soft tissue gas. Note the extensive soft tissue swelling and gas bubbles at the anterior knee due to infection with a gas-forming organism.



**Figure 22** Infected TKA. There is diffuse immature periostitis surrounding the distal femur representing osteomyelitis.

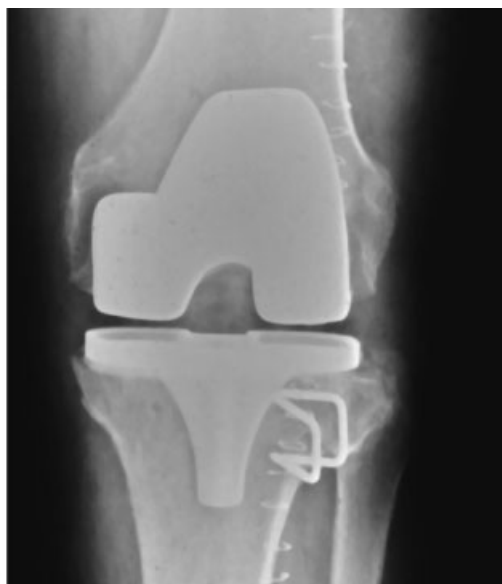spaces and bone defects (Fig. 28). After several weeks, when there is clinical evidence that the infection has cleared, the prosthesis is reimplanted (two-stage procedure).

#### COMPUTED TOMOGRAPHY

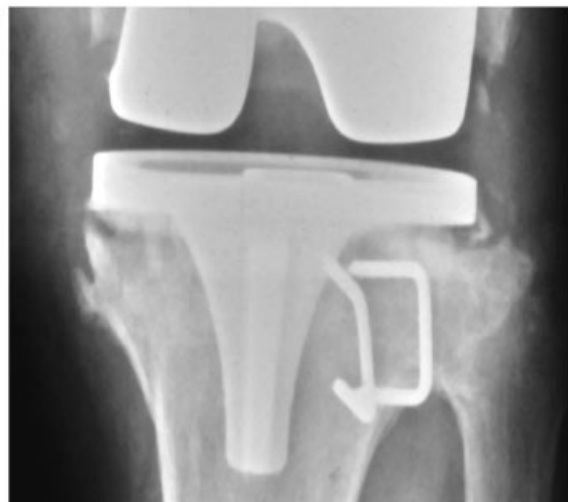We have found CT to be extremely helpful for evaluating patients with painful TKA, and advances in multi-detector CT have improved the image quality by further minimizing metal artifact. Review of a large number of CT scans of painful TKA with equivocal plain films<sup>11</sup>

has shown this modality to be particularly effective for the following indications:

1. Loosening: CT can show the extent and width of periprosthetic lucency that may be underestimated or not apparent on plain films, facilitating the diagnosis (Fig. 29).
2. Osteolysis: CT is superior to plain films for the diagnosis of osteolysis. Because osteolysis is often radiographically occult, we advise that all patients with painful TKA with normal or equivocal plain

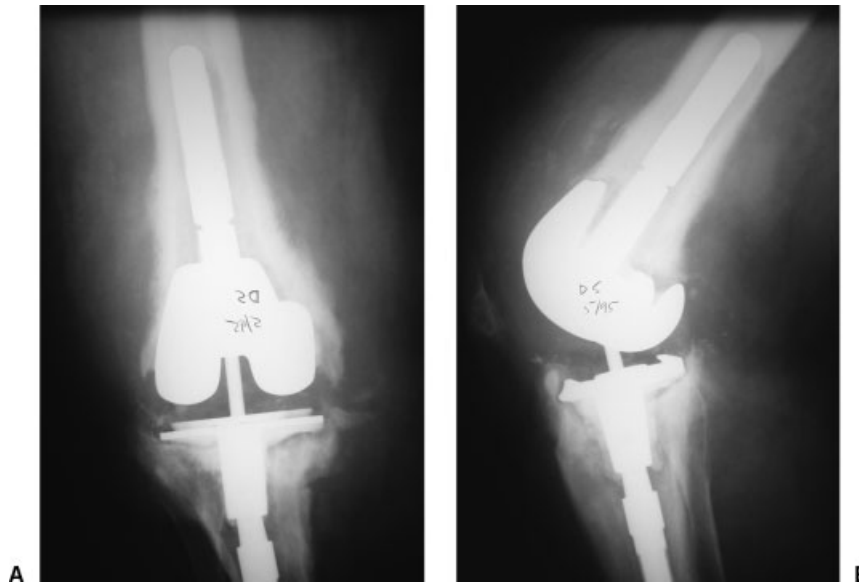


**A**



**B**

**Figure 23** Infected TKA with bone resorption. (A) Demonstration of focal areas of bone resorption not present on (B) the postoperative study.



**Figure 24** Infected TKA. (A) AP and (B) lateral views show diffuse periosteal reaction surrounding distal femur. Note the tibial subsidence due to septic loosening.

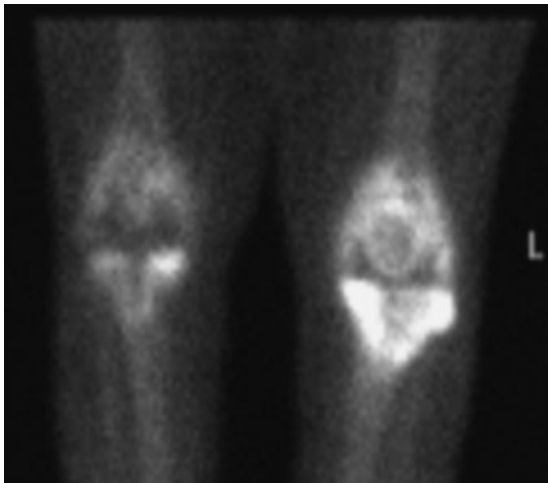
films and increased uptake on all three phases of a TPBS have a CT scan to assess for osteolysis (Fig. 20).

3. Assessment of rotational alignment of the femoral component relative to the transepicondylar axis (Fig. 6).
4. Detection of subtle or occult periprosthetic fracture (Fig. 30).

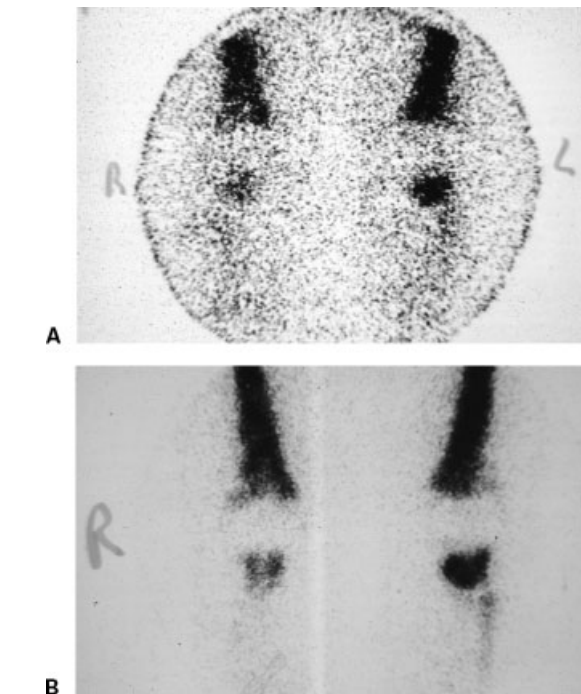
#### ULTRASOUND

Musculoskeletal ultrasound has widespread applications in the diagnosis and guided treatment of orthopedic injuries and diseases and can be particularly useful in the


setting of total joint arthroplasty, where the metal components may be associated with significant artifact on CT or MRI that may preclude their evaluation with these modalities. The applications of ultrasound in total



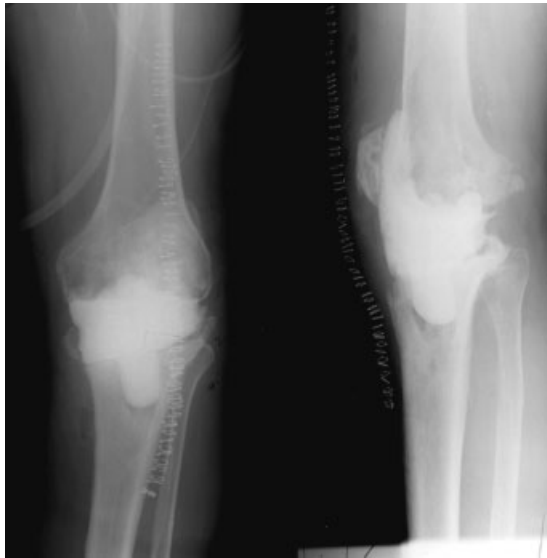**Figure 25** Loose left TKA—tibial and femoral components. There is increased uptake surrounding tibial and femoral components of the left TKA reflecting loosening. Note the normal physiologic increased periprosthetic uptake at the right TKA.



**Figure 26** False-positive indium scan: value of marrow scan. (A) Indium-WBC scan shows significant focal increased uptake in the left proximal tibia. (B) Sulfur colloid marrow scan shows increased uptake in the left proximal tibia that matches the uptake on the indium scan in distribution and degree. This represents areas of aberrant hyperplastic marrow rather than infection.



**Figure 27** Infected TKA on nuclear scintigraphy. (A) Indium-WBC scan shows diffuse increased uptake at the distal femur and left knee that is greater in degree and more diffuse in distribution than on the (B) marrow scan.

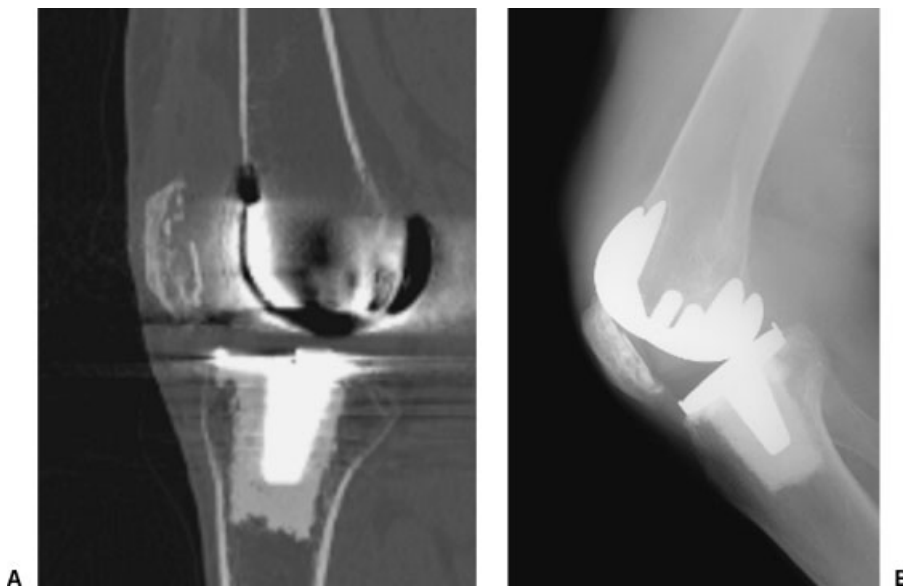


**Figure 28** Infected TKA following resection arthroplasty. Antibiotic-impregnated opaque cement spacer was placed in the tibiofemoral and patellofemoral compartments for treatment of infection (two-stage procedure).

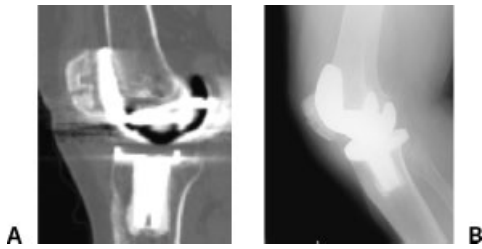
joint arthroplasty evaluation are discussed elsewhere in this issue.

### MAGNETIC RESONANCE IMAGING

The role of MRI in evaluating total joint replacements is not yet clearly defined. Although MRI is recognized as the imaging “gold standard” for evaluating musculoskeletal diseases, the magnetic susceptibility artifact associated with metal prostheses has limited the role of this modality in this population of patients. In the past several years, major advancements have been made in the protocols employed for scanning patients with metal implants and minimizing metal artifact. Specifically, techniques such as increasing the imaging bandwidth,<sup>40</sup> reducing TE, using fast spin echo with a longer echo train, and avoiding chemical fat saturation and gradient echo imaging have been shown to improve the image quality in joint replacement patients,<sup>41</sup> and as some of the more recent technological advances are made more widely available, the role of MRI will certainly increase.



**Figure 29** Loose patellar component on CT. (A) Sagittal reformatted CT image shows loose patellar component with extensive surrounding lucency. Note that these findings are much less conspicuous on the (B) lateral view of the knee that was interpreted as normal.



**Figure 30** Patellar fracture. (A) Sagittal reformatted CT image demonstrates a symptomatic transverse patellar fracture that is not well seen on the (B) lateral view.

The increasing role of MRI is addressed in a separate article in this issue.

## CONCLUSION

Patients presenting with a painful TKA represent a challenging population for the general orthopedic surgeon and joint reconstruction specialist alike. Diagnostic imaging, using a range of imaging modalities including plain films, nuclear scanning, CT, and (ultrasound or) MRI can be extremely helpful in establishing a diagnosis in patients who have an unclear clinical presentation. Consultation between the orthopedist and radiologist with appropriate clinical correlation is essential in this challenging population of patients to choose the optimal imaging approach and to interpret the results based upon the individual clinical setting.

## ACKNOWLEDGMENTS

We would like to thank Douglas S. Katz, M.D. for his extremely valuable suggestions and comments during the preparation of the manuscript.

## REFERENCES

- Agency for Healthcare Research and Quality. Healthcare cost and utilization project (HCUP) statistics for 2002. Available at: <http://www.ahrq.gov>. Accessed May 5, 2005
- Smith PN, Rorabeck CH. PCL sparing total knee arthroplasty. In: Scuderi GR, Tria AJ, eds. *Surgical Techniques in the Total Knee Arthroplasty*. New York: Springer-Verlag; 2002:49–60
- Barnes CL, Sledge CB. Total knee arthroplasty with posterior cruciate retention designs. In: Insall JN, Windsor RE, Scott WN, et al, eds. *Surgery of the Knee*. 2nd ed. New York: Churchill Livingstone; 1993:815–827
- Stiehl JB, Komistek RD, Dennis DA, Paxson RD, Hoff WA. Fluoroscopic analysis of kinematics after posterior cruciate retaining knee arthroplasty. *J Bone Joint Surg Br* 1995;77:884–889
- Scuderi GR, Pagnano MW. The rationale for posterior cruciate substituting total knee arthroplasty. *J Orthop Surg (Hong Kong)* 2001;9:81–88

- Broughton NS, Newman JH, Baily RA. Unicompartmental replacement and high tibial osteotomy for osteoarthritis of the knee. A comparative study after 5–10 years' follow-up. *J Bone Joint Surg Br* 1986;68:447–452
- Allen AM, Ward WG, Pope TL. Imaging of the total knee arthroplasty. *Radiol Clin North Am* 1995;33:289–303
- Benjamin JB, Lund PJ. Orthopedic devices. In: Hunter TB, Bragg DG, eds. *Radiological Guide to Medical Devices and Foreign Bodies*. St. Louis, MO: Mosby; 1994:348–385
- Weissman BN. Radiographic evaluation of total joint replacement. In: Sledge CB, Ruddy S, Harris ED Jr, et al, eds. *Arthritis Surgery*. Philadelphia, PA: WB Saunders; 1994:846–907
- Merchant AC, Mercer RL, Jacobs RH, et al. Roentgenographic analysis of patellofemoral congruence. *J Bone Joint Surg Am* 1974;56:1391–1396
- Math KR, Griffin F, Scuderi GR, Insall JN. Imaging of the epicondylar axis of the distal femur: utility in the evaluation of the painful total knee arthroplasty. Paper presented at the Radiological Society of North America Scientific Assembly; December 2, 1997; Chicago, IL
- Scuderi GR, Insall JN. Rotational positioning of the femoral component in total knee arthroplasty. *Am J Knee Surg* 2000;13:159–161
- Anouchi YS, Whiteside LA, Kaiser AD, et al. The effects of axial rotational alignment of the femoral component on knee stability and patellar tracking in total knee arthroplasty demonstrated on autopsy specimens. *Clin Orthop Relat Res* 1993;287:170–177
- Rhoads DD, Noble PC, Reuben JD, et al. The effect of femoral component positioning on patellar tracking after total knee arthroplasty. *Clin Orthop Relat Res* 1990;260:43–51
- Berger RA, Rubash HE, Seel MJ, Thompson WH, Crossett LS. Determining the rotational alignment of the femoral component in total knee arthroplasty using the epicondylar axis. *Clin Orthop Relat Res* 1992;186:40–47
- Crossett LS, Rubash HE, Berger R. Computerized tomography in total knee arthroplasty. In: Insall JN, Scott WN, Scuderi GR, eds. *Current Concepts in Primary and Revision Total Knee Arthroplasty*. Philadelphia, PA: Lippincott-Raven; 1996:235–248
- Ewald FC. The Knee Society total knee arthroplasty roentgenographic evaluation and scoring system. *Clin Orthop Relat Res* 1989;248:9–12
- Math KR, Schieder R. Imaging of the painful TKR. In: Scuderi GR, Tria AJ, eds. *Surgical Techniques in the Total Knee Arthroplasty*. New York: Springer-Verlag; 2002:351–367
- Mintz AD, Pilkington CA, Howie DW. A comparison of plain and fluoroscopically guided radiographs in the assessment of arthroplasty of the knee. *J Bone Joint Surg Am* 1989;71:1343–1347
- Peters PC, Engh GA, Dwyer KA, et al. Osteolysis after total knee arthroplasty without cement. *J Bone Joint Surg Am* 1992;74:864–876
- Tucker WF Jr, Rosenberg AF. Osteolysis following total knee arthroplasty. In: Insall JN, Scott WN, Scuderi GR, eds. *Current Concepts in Primary and Revision Total Knee Arthroplasty*. Philadelphia, PA: Lippincott-Raven; 1996:131–146
- Engh GA, Ammeen DJ. Periprosthetic osteolysis with total knee arthroplasty. *Instr Course Lect* 2001;50:391–398



23. Weissman BN, Scott RD, Brick GW, et al. Radiographic detection of metal-induced synovitis as a complication of arthroplasty of the knee. *J Bone Joint Surg Am* 1991;73:1002-1007
24. Masini MA, Maguire JH, Thornhill TS. Infected total knee arthroplasty. In: Scott WN, ed. *The Knee*. St. Louis, MO: Mosby-Year Book; 1994:1261-1278
25. Rand JA, Bryan RS. Reimplantation for the salvage of an infected total knee arthroplasty. *J Bone Joint Surg Am* 1983; 65:1081-1086
26. Rand JA, Bryan RS, Morrey BF, et al. Management of infected total knee arthroplasty. *Clin Orthop Relat Res* 1986; 205:75-85
27. Cameron HU, Hunter GA. Failure in total knee arthroplasty: mechanisms, revisions and results. *Clin Orthop Relat Res* 1982;170:141-146
28. Dennis DA. Evaluation of painful total knee arthroplasty. *J Arthroplasty* 2004;19:35-40
29. Schneider R, Hood RW, Ranawat CS. Radiographic evaluation of total knee arthroplasty. *Orthop Clin North Am* 1982; 13:225-244
30. Schneider R, Soudry M. Radiographic and scintigraphic evaluation of total knee arthroplasty. *Clin Orthop Relat Res* 1986;205:108-120
31. Love C, Tomas MB, Marwin SE, Pugliese PV, Palestro CJ. Role of nuclear medicine in diagnosis of the infected joint replacement. *Radiographics* 2001;21:1229-1238
32. Howie DW, Savage JP, Wilson TG, et al. The technetium phosphate bone scan in the diagnosis of osteomyelitis in childhood. *J Bone Joint Surg Am* 1983;65:431-435
33. Lisbona R, Rosenthal L. Observations on the sequential use of <sup>99m</sup>Tc-phosphate complex and <sup>67</sup>Ga imaging in osteomyelitis, cellulitis and septic arthritis. *Radiology* 1977; 123:123-127
34. Shauwecker DS. The role of nuclear medicine in osteomyelitis. In: Collier BD, Folgelman I, Rosenthal L, eds. *Skeletal Nuclear Medicine*. St. Louis, MO: Mosby-Year Book; 1996: 182-203
35. Palestro CJ, Swyer AJ, Kim CK, et al. Infected knee prosthesis: diagnosis with In-111 leukocyte, Tc-99m sulfur colloid, and with Tc-99m MDP imaging. *Radiology* 1991; 179:645-648
36. Palestro CJ, Kim CK, Swyer AJ, Capozzi JD, Solomon RW, Goldsmith SJ. Total-hip arthroplasty: periprosthetic indium-111-labeled leukocyte activity and complementary technetium-99m sulfur colloid imaging in suspected infection. *J Nucl Med* 1990;31:1950-1955
37. Datz FL, Taylor A Jr. The clinical use of radionuclide bone marrow imaging. *Semin Nucl Med* 1985;15:239-259
38. Love C, Marwin SE, Tomas MB, et al. Diagnosing infection in the failed joint replacement: a comparison of coincidence detection <sup>18</sup>F-FDG and <sup>111</sup>In-labeled leukocyte/<sup>99m</sup>Tc-sulfur colloid marrow imaging. *J Nucl Med* 2004;45: 1864-1871
39. Rao S, Solomon N, Miller S, et al. Scintigraphic differentiation of bone infarction from osteomyelitis in children with sickle cell disease. *J Pediatr* 1985;107:685-688
40. Olsen RV, Munk PL, Lee MJ, et al. Metal artifact reduction sequence: early clinical applications. *Radiographics* 2000;20: 699-712
41. Sofka CM, Potter HG, Figgie M, Laskin R. Magnetic resonance imaging of total knee arthroplasty. *Clin Orthop Relat Res* 2003;406:129-135