

Cervical Spine Trauma: Pearls and Pitfalls

Mark P. Bernstein¹, Alexander B. Baxter

Accurate diagnosis of acute cervical spine injury requires cooperation between clinician and radiologist, a reliable and repeatable approach to interpreting cervical spine CT, and the awareness that a patient may have a significant and unstable ligamentous injury despite normal findings. Emergency physicians triage patients with suspected cervical spine injury into high- and low-risk groups—that is, those who require imaging for confirmation and accurate evaluation and those who can be confidently discharged. Both the Canadian C-Spine rule and National Emergency X-Radiography Utilization Study criteria provide guidelines for deciding which patients must undergo imaging. Anyone with midline tenderness, focal neurologic deficit, altered sensorium, or a distracting injury requires CT as well as protection of the spine in a hard cervical collar. Other high-risk factors include age older than 65 years, extremity paresthesias, and significant energy-transfer mechanism.

Background

MDCT with thin-section reconstruction and multiplanar reformations identifies the exact location and displacement of fractures and bone fragments and defines the extent of any potential spinal canal, neuroforaminal, or vascular compromise. An accurate clinical history that specifies injury mechanism and location of pain is essential for accurately interpreting subtle findings, particularly in the presence of degenerative disk disease. To avoid search pattern errors, it is helpful to have a checklist in mind that will ensure that all important structures are examined, as outlined in the following subsections.

Transaxial Images

Examine the integrity and rotational alignment of each vertebra, the cervical soft tissues, spinal canal diameter, and neuroforaminal patency.

Midline Sagittal Images

Evaluate the prevertebral soft tissues for thickness greater than 5 mm at C2 or 15 mm at C5. The anterior spinal line, posterior spinal line, and spinolaminar line should be continuous, and the interspinous distance should be uniform. The dens-basion distance should be 9.5 mm or less, and a line drawn vertically along the dorsal body of C2 (posterior axial line) should be less than 5.5 mm posterior to the basion. The atlantodental interval should be less than 3 mm in adults. The C1–2 interspinous distance measured at the spinolaminar line should be less than 7.8 mm.

Parasagittal Images

The occipital condyles should be intact. The atlantooccipital and atlantoaxial articulations should be congruent and the facets should align normally, with the inferior articulating facet of the upper vertebral body posterior to the superior articulating facet of the adjacent lower vertebral body.

Keywords: cervical spine, CT, fracture, trauma

¹Both authors: Department of Radiology, New York University Langone Medical Center/ Bellevue Hospital, 560 First Ave, HG-80, New York, NY 10016. Address correspondence to M. P. Bernstein (markusgunn@gmail.com).

Coronal Images

The occipital condyles, C1, and C2 should be intact and aligned. The dens should be centered between the lateral masses of C1.

Interpretation

Osseous displacement at the moment of impact may be reduced by recoil and muscle spasm, and immobilization with placement of a hard collar can mask instability by maintaining vertebral alignment. If CT findings are normal and the patient has persistent pain or neurologic symptoms, a significant ligamentous injury should be sought. Although MRI can identify ligamentous edema, it may be present in clinically stable injuries. Dynamic evaluation with delayed flexion and extension radiographs under neurosurgical supervision is the sine qua non for identification of ligamentous injury. Patients with pain but without neurologic symptoms are generally discharged in a hard cervical collar, and flexion and extension studies are performed 1–2 weeks after injury, when any muscle spasm has resolved.

In the setting of acute neurologic deficit, MRI can provide useful information by identifying epidural hematoma, traumatic disk herniation, or spinal cord contusion. But the immediate clinical question in acute spine trauma is always, “Does the patient re-

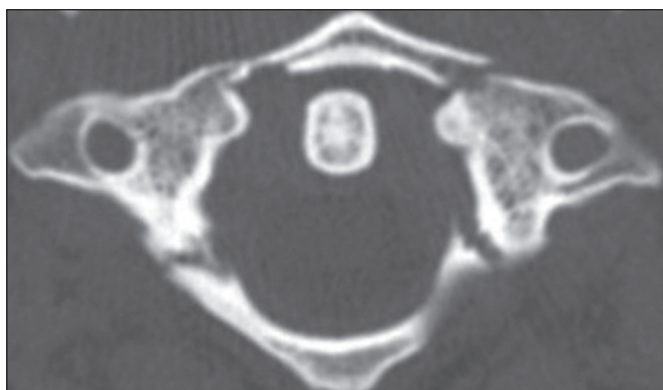
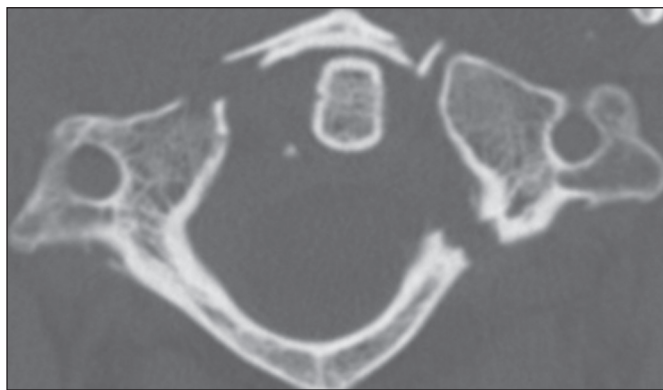
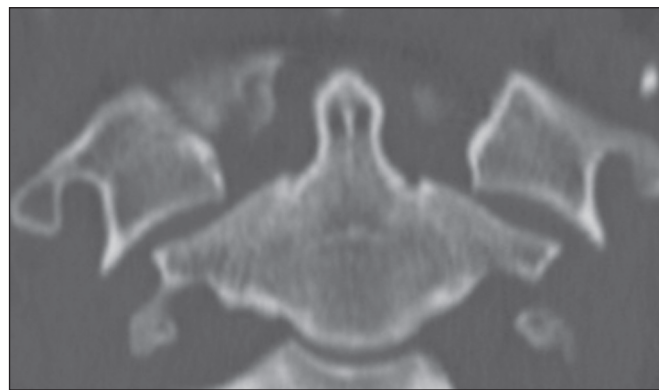


Fig. 1—38-year-old man with classic Jefferson burst fracture with two anterior and two posterior ring fractures.



A



B

Fig. 2—32-year-old woman with variant Jefferson burst fracture. **A** and **B**, Transaxial (**A**) and coronal (**B**) CT reformations show lateral spread of fracture fragments, which indicates transverse ligament rupture and instability. (Reprinted with permission from [1])

quire surgical decompression?” Evaluation of canal and neuroforaminal patency is adequately accomplished by CT alone.

In addition to developing a repeatable approach, maintaining suspicion that a radiographically normal spine may still be injured, and appreciating the surgical decisions that must be made in the acute setting, a visual familiarity with the range of cervical spine fractures and injuries is invaluable. This chapter will describe several characteristic cervical spine injuries, their mechanisms, unstable variants, imaging hallmarks, and differential diagnoses.

Atlas Injuries: Jefferson Fracture and Unstable Variants

Relevant Mechanism, Anatomy, and Cause

The first cervical vertebra (atlas, C1) articulates with the occipital condyles and supports the cranium. It is a simple bony ring with two lateral masses supported anteriorly and posteriorly by the neural arches. This unique shape allows great range of motion. The odontoid articulates with the anterior arch of C1 and is held in place by the transverse ligament, the integrity of which is the key determinant of atlantoaxial stability. The classic Jefferson fracture results from an axial load with forces transmitted through the occipital condyles to the lateral masses, causing a burst fracture of C1.

Appearance on Relevant Modalities

The classic Jefferson fracture (Fig. 1) is a four-part fracture, with fractures occurring at the weakest points of the ring, the anterior and posterior junctions of the arches and lateral masses. It is a decompressive injury with radial displacement of the fragments away from the spinal canal. As an isolated injury, the classic Jefferson burst is both mechanically and neurologically stable.

Atypical Jefferson fractures (Fig. 2) are produced by asymmetric axial loading, resulting in fewer than four fractures of the C1 ring. Transverse ligament injury allows the ring to open and renders the Jefferson variants unstable, permitting C1–2 subluxation. Consequently, the integrity of the transverse ligament must be assessed to determine stability.

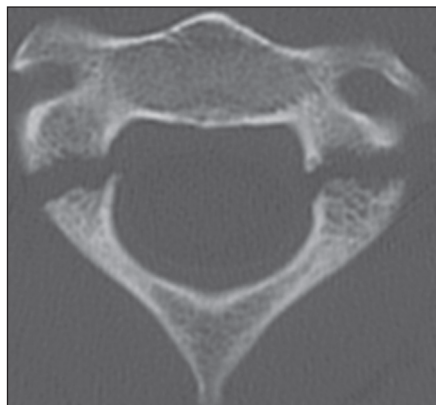


Fig. 3—24-year-old man with hangman's fracture. Bilateral C2 pars interarticularis fractures are seen. (Reprinted with permission from [1])

Transverse separation of fracture fragments by 7 mm or more indicates transverse ligament injury and instability. This measurement, known as the rule of Spence, can be made on transverse CT but is applicable only in the presence of a fracture. Other signs of instability include avulsion of the C1 tubercle (transverse ligament insertion), two anterior ring fractures, and atlantodental interval greater than 3 mm in adults or 5 mm in children. MRI is highly sensitive for the diagnosis of transverse ligament rupture.

Differential Diagnosis

Pitfalls include congenital fusion anomalies and aplasias that may simulate fractures. These are identified by their smooth well-corticated margins.

Axis Injuries: Hangman's Fractures

Relevant Anatomy and Cause

The "hangman's fracture," or traumatic spondylolisthesis of C2 (Fig. 3), refers to bilateral pars interarticularis fractures, which bear similarities to findings seen in persons who have undergone judicial hanging. Most of these fractures result from falls and motor vehicle crashes, and the fractures reflect a variety of injury mechanisms.

Appearance and Mechanism

Pars interarticularis fractures are best seen on transverse and parasagittal CT images. They are often asymmetric and are considered atypical when the fracture extends into the posterior vertebral body. Atypical fracture patterns are actually quite common and may involve the transverse foramen, placing the vertebral artery at risk for injury.

The most widely used classification for traumatic spondylolisthesis is the system devised by Effendi and modified by Levine and Edwards, as outlined in the following subsections.

Type 1 fractures—Type 1 fractures are bilateral pars fractures without angulation or significant translation. These result from hyperextension and axial loading and are considered mechanically and neurologically stable.

Type 2 fractures—Type 2 fractures include disruption of the C2–3 disk with anterior translation of the C2 body. These are the most common hangman's fracture type and result from hyperextension with axial loading followed by hyperflexion. They are

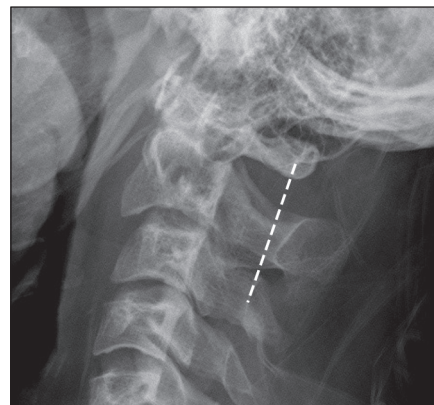


Fig. 4—28-year-old man with atypical hangman's fracture. C2 body fracture with anteroposterior displacement of fracture fragments (fat C2 body sign) is seen. Fracture disrupts Harris ring posteriorly and causes posterior offset of spinolaminar line from C1 to C3 (dotted line).

unstable and may produce a small posterior fracture fragment that can narrow the canal and cause spinal cord injury.

Type 2A fractures—Type 2A fractures are unstable flexion-distraction injuries with C2 angulation but without translation.

Type 3 fractures—Type 3 fractures are combined anterior translation and angulation with facet subluxation or frank dislocation. These are highly unstable injuries that result from hyperflexion and compression.

Diagnostic and Differential Points

Type 1 fractures are radiographically subtle and may be easily overlooked but should be identified on CT with multiplanar reconstructions. Prevertebral soft-tissue swelling is often present, and the spinolaminar line from C1 to C3 may show posterior displacement of the C2 spinolaminar junction. Atypical fractures disrupt the Harris ring posteriorly and show anteroposterior separation of C2 body fracture fragments, known as the fat C2 sign (Fig. 4). Fractures involving the transverse foramen, or those associated with neurologic deficit, should be followed with angiographic imaging, usually CT angiography, to exclude vertebral artery injury (Fig. 5).

Types 2A and 3 require surgical reduction and internal fixation and must therefore be differentiated from types 1 and 2. Concurrent upper cervical fractures are common and should be excluded. These include odontoid fractures, posterior C1 arch fractures, and hyperextension teardrop fractures.

Subaxial Cervical Spine: Hyperflexion Sprain and Anterior Subluxation

Relevant Mechanism, Anatomy, and Cause

Subaxial hyperflexion injuries (Fig. 6) comprise progressively severe disruptions of cervical ligamentous integrity. These range from hyperflexion sprain, to anterior subluxation, to bilateral interfacetal dislocation and flexion teardrop fracture. Corresponding ligamentous disruption progresses from posterior to anterior, beginning with disruption of the supraspinous ligament, interspinous ligaments, capsular ligaments, and ligamentum flavum. This group of ligaments is referred to as the posterior ligament complex.

Disruption of the posterior ligament complex alone is insufficient to generate spinal instability. The hyperflexion sprain is

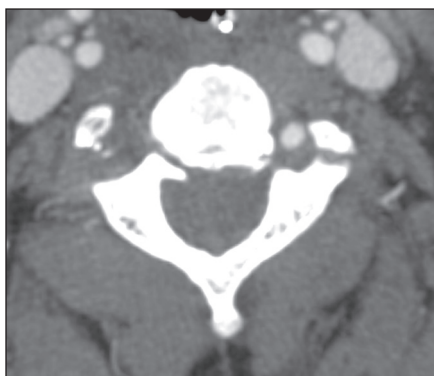

Fig. 5—55-year-old man with atypical hangman's fracture. Transaxial CT angiography image shows fractures through both transverse foramina, with occlusion of right vertebral artery.

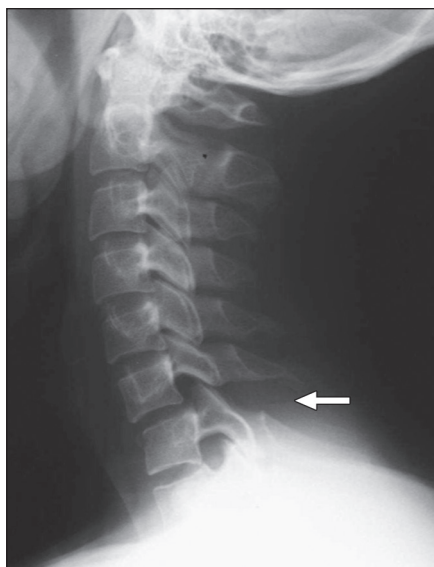


Fig. 6—21-year-old woman with anterior subluxation. Lateral cervical spine radiograph shows subtle signs of hyperflexion, including C6-7 interspinous widening (arrow), uncovering of facets, and slight anterior translation. Courtesy of Rybak L, NYU Langone Medical Center, New York, NY.

limited to posterior ligament complex injury and is stable. Anterior subluxation reflects further hyperflexion with disruption of the posterior longitudinal ligament and posterior disk annulus (middle of column of Denis), which leads to instability.

The radiologic evaluation of hyperflexion sprain and anterior subluxation can be challenging. Radiographic and CT signs are subtle; even when recognized, the significance may not be appreciated. However, it is important to understand because missed injury can lead to significant morbidity, including pain, kyphosis, delayed vertebral dislocation, and neurologic deficit.

Appearance on Relevant Modalities

Imaging features of progressively severe hyperflexion injuries include (from posterior to anterior) fanning of spinous processes or interspinous widening, uncovered facets, widened posterior disk space, focal kyphosis, and anterior subluxation. Vertebral body compression fractures may be seen with sufficient hyperflexion and axial loading.

When CT findings are equivocal, MRI can detect edema of the cervical ligaments and soft tissues. Flexion and extension radiographs should not be performed in the presence of muscle spasm to avoid false-negative results.

Differential Diagnosis

Cervical straightening and reversal of the normal lordosis may occur in cervical muscle spasm and should be distinguished from true anterior subluxation. Close attention to facet alignment on CT and posterior disk spacing are most helpful in this regard.

Degenerative changes may be confused with traumatic subluxation. In contrast to traumatic anterior subluxation, retrolisthesis is the usual consequence of cervical spondylosis because of normal cervical lordosis and posterior inclination of the articular facets. Degenerated facet joints are most commonly narrowed, with thinning of the bony facet from long-term wear. In traumatic subluxations, however, the facet joints are often abnormally widened.

Hyperextension-Dislocation

Relevant Mechanism, Anatomy, and Cause

Hyperextension cervical spine injuries range from the stable hyperextension sprain to the highly unstable hyperextension-dislocation. They are predominantly ligamentous disruptions that progress from anterior to posterior, beginning with the anterior longitudinal ligament and anterior annulus fibrosus and extending through the posterior annulus, posterior longitudinal ligament, and ligamentum flavum. The hyperextension-dislocation injury often results in major neurologic deficits, typically a central cord syndrome.

Approximately 25% of cervical spine injuries are the result of hyperextension forces, either associated with direct impact, or through a whiplash effect. Direct impact injuries are often associated with frontal head or facial injuries. Conditions predisposing to injury include age older than 65 years, with increased propensity for falls and motor vehicle crashes, degenerative changes, spinal canal stenosis, and osteopenia.

Appearance on Relevant Modalities

Although hyperextension-dislocation injuries are severe and unstable, imaging signs are often subtle. Extensive soft-tissue injury and displacement occurs at the moment of trauma, but muscular spasm and immobilization in a cervical collar can result in an apparently normal spine examination.

Hyperextension-dislocation injuries usually involve the lower cervical spine. Signs on lateral radiographs and sagittal CT reformations include mild anterior intervertebral disk space widening, anterior vertebral body avulsion fragments, and facet malalignment (Fig. 7A). In the normal spine, facets should be parallel. With extension injuries, one may see V-shaped facet joints that are wide anteriorly and tapered posteriorly.

MRI reveals the extent of discoligamentous injury. T2-weighted images show ligamentous disruption, soft-tissue edema, disk protrusion, and spinal cord injuries (Fig. 7B).

Differential Diagnosis

Like the hyperflexion sprain and anterior subluxation, the hyperextension-dislocation may be overlooked and misinterpreted as normal on both radiographs and CT. Neurologic

Fig. 7—64-year-old man with hyperextension-dislocation.

A, Midsagittal CT image shows slight anterior disc space widening at C3–4 and osteophyte chip fracture (*arrow*). Spinal column is otherwise well aligned.

B, Midsagittal T2-weighted MRI shows prevertebral soft-tissue edema with disruption of anterior longitudinal ligament (*arrow*). Contused spinal cord is squeezed between traumatic disc herniation (*arrowhead*) and ligamentum flavum. Posterior soft-tissue injury is indicated by high signal changes. (Reprinted with permission from [1])

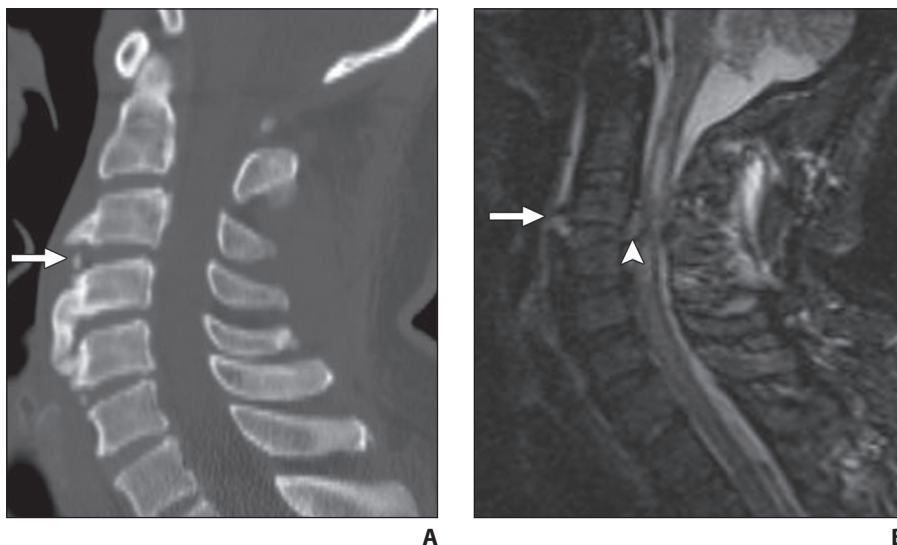
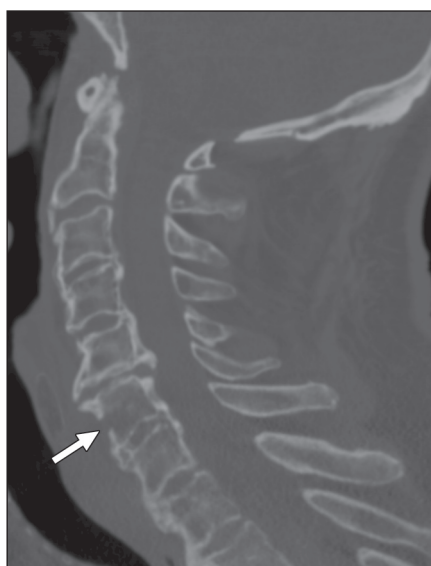

Fig. 8—69-year-old man with fused spine hyperextension fracture with cortical disruption of C6 (*arrow*). Transverse fracture orientation is easily overlooked on transaxial CT.



deficit, concurrent head trauma, or facial fracture should raise suspicion for this potentially unstable injury.

Vertebral body corner fractures, when present in hyperextension-dislocation injuries, tend to have a preferentially horizontal orientation. This is in contrast to the more vertically oriented hyperextension teardrop fracture, which is usually seen in the upper cervical spine, typically at C2.

Cervical Spine Trauma in Preexisting Pathologic Conditions: Fused Spine Hyperextension Injury

Relevant Mechanism, Anatomy, and Cause

Ankylosing spondylitis and diffuse idiopathic skeletal hyperostosis both result in intervertebral bridging with fusion and poor underlying bone quality. Rigidity of the fused segment renders it susceptible to fracture with even mild hyperextension.

Most patients with fused spine hyperextension fractures have profound neurologic deficits. Delayed neurologic injury occurs in 20–100% of cases when initial diagnosis is missed. The high incidence of noncontiguous additional fractures mandates screening of the entire spine. Surgical repair requires long segment fixation.

Appearance on Relevant Modalities

A high index of suspicion should be maintained with trauma patients who have ankylosing spondylitis or diffuse idiopathic skeletal hyperostosis because fused spine hyperextension fractures may be occult on radiographs and CT. This is due to both frequent spontaneous reduction and underlying osteoporosis, particularly in patients with advanced disease.

Sagittal CT reformations optimally identify undisplaced subtle fractures because they are often horizontal, limiting the utility of transaxial images (Fig. 8). Fractures may involve the vertebral body, the fused disk space, or traverse both in an oblique fashion. These fractures typically involve the lower cervical spine and are complete, crossing all ossified ligaments from anterior to posterior and resulting in marked instability.

REFERENCE

1. Legome E, Shockley LW, eds. *Trauma: A Comprehensive Emergency Medicine Approach*. Cambridge, UK: Cambridge University Press; 2011

SUGGESTED READING

1. American College of Radiology. ACR appropriateness criteria: suspected spine trauma. American College of Radiology Website. www.acr.org/SecondaryMainMenuCategories/quality_safety/app_criteria/pdf/ExpertPanelonPediatricImaging/Othertopics/SuspectedSpineTrauma.aspx. Published 1999. Updated 2009. Accessed October 19, 2011
2. Daffner RH, Daffner SD. Vertebral injuries: detection and implications. *Eur J Radiol* 2002; 42:100–116
3. Hoffman JR, Mower WR, Wolfson AB, Todd KH, Zucker MI. Validity of a set of clinical criteria to rule out injury to the cervical spine in patients with blunt trauma: National Emergency X-Radiography Utilization Study Group. *N Engl J Med* 2000; 343:94–99
4. Rao SK, Wasyliv C, Nunez DB Jr. Spectrum of imaging findings in hyperextension injuries of the neck. *RadioGraphics* 2005; 25:1239–1254
5. Stiell IG, Wells GA, Vandemheen KL, et al. The Canadian C-spine rule for radiography in alert and stable trauma patients. *JAMA* 2001; 286:1841–1848

