

Anatomically Based Guidelines for Core Needle Biopsy of Bone Tumors: Implications for Limb-sparing Surgery¹

TEACHING POINTS

See last page

Patrick T. Liu, MD • Scott D. Valadez, MD • F. Spencer Chivers, MD
Catherine C. Roberts, MD • Christopher P. Beauchamp, MD

Diagnostic image-guided needle biopsy plays a vital role in the work-up and treatment of patients with extremity bone tumors. The radiologist and the orthopedic oncologic surgeon should take a team approach to this procedure, especially when the bone lesion might be a primary sarcoma for which limb-sparing surgery (LSS) would be considered. A set of anatomically based guidelines were developed that can be used by the radiologist, in combination with case-by-case consultation with the surgeon, to plan image-guided core needle biopsies of extremity long bone lesions that may be treatable with LSS. By using these guidelines, along with the aforementioned consultation, the radiologist will be able to preserve the patient's chances of receiving optimal surgical treatment.

©RSNA, 2007

Introduction

Over the past 30 years, the prognosis for patients with primary bone malignancies of the extremities has greatly improved due to innovations in imaging, chemotherapy, and surgical techniques. Orthopedic oncologic surgeons can now remove bone sarcomas without amputation in the vast majority of patients, with only a limited loss of

Abbreviations: LSS = limb-sparing surgery, VR = volume-rendered

RadioGraphics 2007; 27:189–206 • Published online 10.1148/rg.271065092 • Content Codes: **MK** **OI** **VI**

¹From the Departments of Radiology (P.T.L., S.D.V., F.S.C., C.C.R.) and Orthopedic Surgery (C.P.B.), Mayo Clinic College of Medicine, 13400 E Shea Blvd, Scottsdale, AZ 85259. Recipient of a Certificate of Merit award for an education exhibit at the 2005 RSNA Annual Meeting. Received May 5, 2006; revision requested August 14 and received September 18; accepted September 21. P.T.L. is a research consultant for the Bracco Group, and C.P.B. is a consultant for Zimmer; all remaining authors have no financial relationships to disclose. **Address correspondence to** P.T.L. (e-mail: liu.patrick@mayo.edu).

See the commentary by Kransdorf following this article.

©RSNA, 2007

limb function, using a class of procedures known as limb-sparing surgery (LSS) (1–4). Radiologists often play an important role in the work-up of these patients by performing image-guided needle biopsy, which has been shown to be nearly as accurate as open biopsy for the diagnosis and staging of musculoskeletal sarcomas, but with fewer complications and lower costs (5–8).

Bone sarcomas have been shown to recur locally from tumor seeding along biopsy tracks after core needle biopsy (9,10), procedures that are generally performed with needles 16 gauge or larger (11). Survival rates for patients who experience local recurrence of these sarcomas are very low, even after repeat surgery (often amputation) and chemotherapy. Therefore, orthopedic oncologic surgical principles require that the biopsy track and immediately surrounding tissue be removed en bloc with the tumor at the time of resection (12–15). The 5-year overall survival rates after local recurrence of osteogenic sarcoma or Ewing sarcoma are only 29% and 14%, respectively (16,17).

Although the recurrence risk has not been quantified for core needle biopsy tracks, it is perceived as a significant issue in the orthopedic oncologic surgery community (14,18). This perception is likely due to reports that the local recurrence rate for sarcomas after open biopsy procedures has been shown to increase over fivefold (from 7% to 38%) when the biopsy scar is not removed at the time of definitive tumor resection (9). Studies have shown that biopsy tracks from fine-needle aspiration (22–25-gauge needles) do not pose a significant risk of tumor seeding (19); however, the accuracy of fine-needle aspiration biopsy is less than that of core needle biopsy in the evaluation of bone lesions (20–22). Because core needle biopsy and fine-needle aspiration are complementary and are frequently performed together, we plan all needle biopsies of potential bone sarcomas as if the needle track will be resected en bloc with the tumor at the time of surgery.

In this article, we describe optimal planning of core needle biopsies of extremity long bone tumors and review the surgical implications of a poorly planned biopsy approach. In addition, we briefly discuss the “knowledge gap” that exists in the general radiology community regarding biopsy planning. We also discuss and illustrate some proposed biopsy guidelines that will help the radiologist ensure patients’ chances of receiving optimal surgical treatment.

Biopsy Planning

When planning a core needle biopsy of a bone lesion, the radiologist should first decide whether the lesion may possibly be a primary sarcoma. To avoid hurting the patient’s chances for successful surgery, nearly all bone lesions that are solitary should be included in this “possible sarcoma” category. **With the exception of a few benign bone lesions that may have characteristic imaging appearances (eg, fibrous dysplasia, osteochondroma, fibrous cortical defects), it is difficult to exclude sarcoma in solitary bone lesions on the basis of imaging findings alone.** Necrotic or myxoid tumors, for instance, can mimic cysts, whereas telangiectatic osteosarcomas have been shown to mimic aneurysmal bone cysts at radiography, computed tomography (CT), and even magnetic resonance (MR) imaging (23).

On the other hand, a patient with a bone lesion that appears coincidentally with multiple widespread similar-appearing bone lesions need not be considered a candidate for LSS. In this situation, metastases would be strongly suspected, and surgical resection would almost certainly not be a treatment option. Core needle biopsy of the lesion would not need to be restricted to a planned incision and could be performed via the easiest, least complex pathway.

If the target bone lesion is considered to be a possible primary malignancy, the radiologist should consult with the orthopedic oncologic surgeon to select a biopsy entry site and pathway that would align with the plane of incision for potential surgery (24). This cooperative planning will ensure that the biopsy track could easily be removed with the tumor at the time of surgical resection, in case the lesion should prove to be a primary bone sarcoma treatable with LSS.

All available cross-sectional images should be reviewed during the planning process to ensure that the patient is eligible for LSS and to find the ideal site within the tumor for biopsy. It is important to visualize the interface between the tumor and nearby major neurovascular bundles, since contamination of major neurovascular structures can necessitate their surgical removal and disqualify the patient from future LSS (25). Invasion of an adjacent muscle will necessitate resection of a large portion of the muscle but not necessarily amputation. Joint involvement introduces increased complexity to the surgery by necessitating a total arthroplasty.

MR imaging is the imaging modality that best delineates tumor boundaries and interfaces with myofascial compartmental boundaries and neurovascular structures. CT better demonstrates permeative cortical bone destruction, bone erosion,

Teaching
Point

Teaching
Point

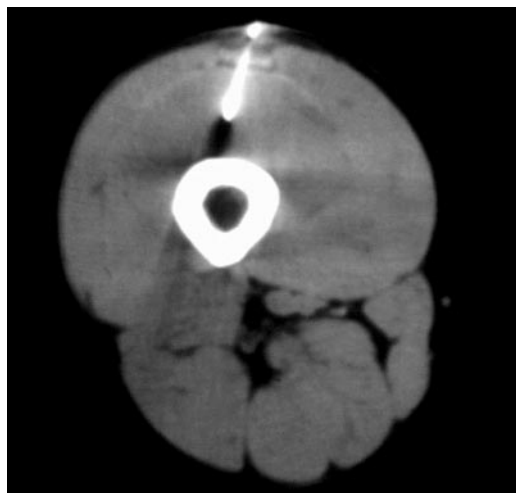


Figure 1. Suboptimal biopsy of Ewing sarcoma in the distal right femur in a 36-year-old man. CT scan obtained during core needle biopsy performed at an outside institution without orthopedic oncologic surgical consultation reveals that the needle was incorrectly inserted using an anterior approach through the rectus femoris muscle. LSS was performed using the standard lateral approach, but the surgeon was forced to perform an additional resection of the anterior portion of the biopsy track. Postoperative knee extension was compromised. Despite the administration of preoperative radiation therapy and chemotherapy and clean surgical margins, the tumor recurred adjacent to the resected biopsy track 9 months later.

and tumor matrix calcification. Osteolytic bone lesions should be examined to find regions of maximal cortical thinning or destruction for the easiest point of access; however, the biopsy track would still need to adhere to the plane of incision for planned LSS. Ultrasonography can be used to identify vascular areas in tumors that would be more likely than other areas to yield positive biopsy results, as well as any avascular areas that may be necrotic or cystic and therefore likely to yield only nondiagnostic tissue. Contrast material-enhanced MR images or CT scans can also be examined to find nonenhancing areas of tumors that could be necrotic or hemorrhagic and that should, therefore, be avoided during biopsy because of the likelihood of a nondiagnostic sample.

Surgical Implications

If a core needle bone biopsy were to pass through tissues outside the planned incision plane, the surgical procedure may have to be altered to include the potentially contaminated tissue in the resection. Less attractive alternatives for the patient would consist of either a wider irradiation field (if the tumor is radiosensitive) or a greater chance of local tumor recurrence at the biopsy site (Fig 1).

LSS procedures were designed to allow removal and replacement of the tumor-containing bone while leaving intact the major neurovascular and myotendinous structures needed to maintain limb function. Patient outcome will suffer unnecessarily if additional, functionally important structures must be resected owing to a poorly planned biopsy approach.

A multicenter study conducted by the Musculoskeletal Tumor Society in 1996 (13) showed that inappropriately performed biopsies of musculoskeletal tumors posed a significant clinical problem. In a review of 597 cases, the authors found that 19% of patients with musculoskeletal tumors had encountered problems with initial image-guided and open biopsy that forced the orthopedic oncologic surgeon to perform more complex resection or order additional chemotherapy or radiation therapy (13).

Perhaps the most striking finding in this study was that poorly planned biopsies led to unnecessary amputations in 5%–8% of patients (13). The authors concluded with a recommendation that biopsies of primary musculoskeletal sarcomas be performed only at institutions with active orthopedic oncologic surgery programs because of deficiencies in knowledge and training among the general radiology and surgery communities.

Knowledge Gap

Probably the major reason these deficiencies exist among the general radiology community is that the need to coordinate biopsy approaches with surgical plans is unique to musculoskeletal tumors and, therefore, not widely known among radiologists in other subspecialty areas. For organs outside the musculoskeletal system, surgeons do not routinely resect needle biopsy tracks when removing tumors. Even though tumor seeding along biopsy tracks has been reported and discussed in cases of tumors arising in the prostate gland, liver, kidney, lung, colon, pancreas, thyroid gland, and breast, the incidence of such tumor seeding is low (26–33). Therefore, radiologists performing percutaneous biopsies of non-musculoskeletal tumors have been able to select biopsy pathways without concern for planned surgical incisions, instead considering only factors such as the shortest skin-to-lesion distance and the avoidance of neurovascular structures and adjacent organs.

Few articles have been published in the radiology or orthopedics literature detailing the correct methods for radiologists to plan biopsies of

Teaching
Point

Teaching
Point

Teaching
Point

Table 1
Guidelines for Biopsy of Bone Tumors in the Thigh

Anatomic Region	Standard Surgical Incision	Vital Structures to Avoid	Recommended Biopsy Approach	Patient Position
Femoral head and neck	Longitudinal line on the lateral thigh, beginning at the cephalad tip of the GT and extending down along the femoral shaft (Fig 2a)	GT bursa, which covers a large portion of the GT from anterolateral to posterolateral and is difficult to remove entirely at surgery; femoral neurovascular bundle anterior to the femoral neck; transverse branch of the lateral femoral circumflex artery, which wraps around the femur just caudal to the GT	Start inferolateral to the hip region in the subtrochanteric region (Fig 2); angle superomedially up through the femoral neck, following an intraosseous course to avoid contamination of the joint capsule	Decubitus position, with the target leg in a nondependent position; place a pad between the patient's thighs to partially abduct the hip of the target leg and align the femoral neck with the scanner gantry plane (the gantry may need to be angled)
Femoral shaft	Longitudinal line on the posterolateral thigh immediately anterior to the LIS (for most femoral masses) (Fig 3a); may also approach immediately posterior to the LIS for masses with posterior extension; medial approach is used for distal femoral lesions only (Fig 3b); proximal thigh: LIS runs between the VL and the GM muscles (Fig 4a); mid thigh: LIS runs between the VL muscle and the long head of the biceps muscle (Fig 4b, 4c); distal thigh: LIS runs between the VL muscle and the short head of the biceps muscle (Fig 4d)	Anterior quadriceps muscles (rectus femoris and vastus intermedius muscles) (OK to resect portions of the VL or biceps femoris muscle adjacent to the LIS; removal of the rectus femoris or vastus intermedius muscle at surgery would cause loss of ability to ambulate after surgery; violation of the LIS will contaminate an additional compartment); sciatic nerve and profunda femoris artery located just posterior to the LIS	Posterolateral skin site, just anterior to the LIS (Fig 4a–4d); can pass through a small portion of the posterolateral aspect of the VL muscle, which can be surgically resected without major loss of quadriceps function	Prone or prone oblique, with the target leg externally rotated so that the lateral surface faces upward (Fig 5)
Distal femoral metaphysis and epiphysis	Lateral or medial approach, depending on whether the lesion is located in the medial or lateral femoral condyle (Fig 3); lateral approach: longitudinal line just anterior to the LIS; medial approach: longitudinal line overlying the vastus medialis muscle and the adductor tubercle of the femur	Superficial femoral neurovascular bundle–adductor canal on the medial side of the mid distal thigh; popliteal neurovascular bundle in the popliteal fossa; knee joint capsule (contamination of the joint capsule will necessitate inclusion of the entire joint at arthroplasty); medial and lateral superior genicular arteries wrap around the distal femur from posterior to anterior, just cephalad to the femoral condyles	Lateral approach: just anterior to the LIS but lateral to the knee joint capsule (Fig 4d, 4e); medial approach: align with the adductor tubercle and pass through the posteromedial portion of the vastus medialis muscle (Fig 4d, 4e); discuss with the surgeon which approach to use	Supine, with the target leg internally or externally rotated so that the biopsy site (whether lateral or medial) faces upward

Note.—GM = gluteus maximus, GT = greater trochanter, LIS = lateral intermuscular septum, VL = vastus lateralis.

Table 2
Guidelines for Biopsy of Bone Tumors in the Lower Leg

Anatomic Region	Standard Surgical Incision	Vital Structures to Avoid	Recommended Biopsy Approach	Patient Position
Tibia	Anteromedial longitudinal line, directly over the anteromedial tibial cortex (Fig 6a), through the subcutaneous fat and into the tibia with no intervening muscle compartment	Tibial tubercle (extensor mechanism may be retained if the knee joint is not involved); anterior and posterior tibial neurovascular bundles in the anterolateral and posteromedial leg, respectively (Fig 7b–7e); peroneal neurovascular bundle in the deep posterior compartment of the calf (Fig 7b–7d); deep peroneal nerve at the deep surface of the peroneus longus muscle; distally, the peroneus brevis and peroneus longus tendons	Anteromedial longitudinal line overlying the anteromedial tibial cortex (Figs 7a–7d, 8)	Supine, with the leg internally or externally rotated so that the target bone and biopsy site face upward
Fibula	Longitudinal line on the lateral leg, just anterior to the posterior intermuscular septum (posterior peroneal septum) (Fig 6b) (the septum lies posterior to the peroneus muscles and anterior to the soleus muscle)	Common peroneal nerve courses around the neck of the fibula just caudal to the knee (Fig 7a)	Proximal and distal ends: directly into the fibula through the skin and subcutaneous fat (Fig 7a, 7e); fibular shaft: entrance just anterior to the posterior intermuscular septum, through the posterior border of the peroneus longus muscle (Fig 7b–7d) (may need to approach posterior to the posterior intermuscular septum depending on tumor location relative to the deep peroneal nerve [Fig 7b, 7c])	Supine, with the leg internally rotated so that the target bone and biopsy site face upward

potential musculoskeletal sarcomas. The need for radiologists to discuss the biopsy approach with the orthopedic oncologic surgeon before performing biopsies of bone lesions has been briefly mentioned in two articles in the radiology literature dealing with bone biopsy techniques (34,35). The standard surgical approaches for LSS have been presented in several musculoskeletal tumor surgical textbooks (14,15,36); to our knowledge, however, only one article in the radiology literature and one in the orthopedics literature have described specific biopsy approaches based on these

surgical guidelines (24,37), and these discussions were limited to biopsies of the proximal humerus, pelvis, distal femur, and proximal tibia.

Proposed Biopsy Guidelines

In Tables 1–4, we propose comprehensive planning guidelines for image-guided needle biopsies of potential sarcomas in the long bones of the

Table 3
Guidelines for Biopsy of Bone Tumors in the Upper Arm

Anatomic Region	Standard Surgical Incision	Vital Structures to Avoid	Recommended Biopsy Approach	Patient Position
Proximal humerus	Longitudinal incision follows the deltopectoral interval near the cephalic vein (Fig 9a); medial incision used for distal humeral lesions only (Fig 9b)	Cephalic vein near the deltopectoral interval (Fig 10a, 10b); tendon of the long head of the biceps muscle (Fig 10a); radial nerve posterior to the proximal humeral metaphysis and diaphysis (Fig 10b)	Just lateral to the cephalic vein, through a small portion of the deltoid muscle (Fig 10a); can displace the tendon of the long head of the biceps muscle lateral to the biopsy track with external rotation of the humerus (note that the surgical approach will also usually be with the humerus in external rotation) (Fig 11)	Supine, with the target arm externally rotated so that the biopsy site faces upward
Humeral shaft	Longitudinal incision on the lateral surface of the midportion of the upper arm, just posterior to the biceps muscle (Fig 10a)	Cephalic vein at the anterolateral aspect of the middle upper arm (Fig 10a, 10b); radial nerve and radial collateral artery in the spiral groove on the posterior surface of the middle third of the humerus (Fig 10b, 10c)	Entrance just posterior to the biceps muscle and the cephalic vein, through the distal portion of the deltoid or brachialis muscle	Supine, with the target arm internally rotated so that the biopsy site faces upward
Distal humeral metaphysis and epiphysis	Longitudinal incision on the lateral arm, through the posterior portion of the brachialis muscle (Fig 10d); the surgeon can split the brachialis muscle and remove a portion along with the humerus; direct incisions over the lateral or medial epicondyles (Fig 10e)	Radial nerve and recurrent radial artery just posterior to the brachialis muscle near the lateral cortex of the distal humerus (Fig 10d, 10e)	Through the brachialis muscle overlying the anterolateral cortex of the distal humerus (Fig 10d), directly into the medial or lateral epicondyle (Fig 10e)	Supine, with the target arm internally or externally rotated so that the biopsy site faces upward

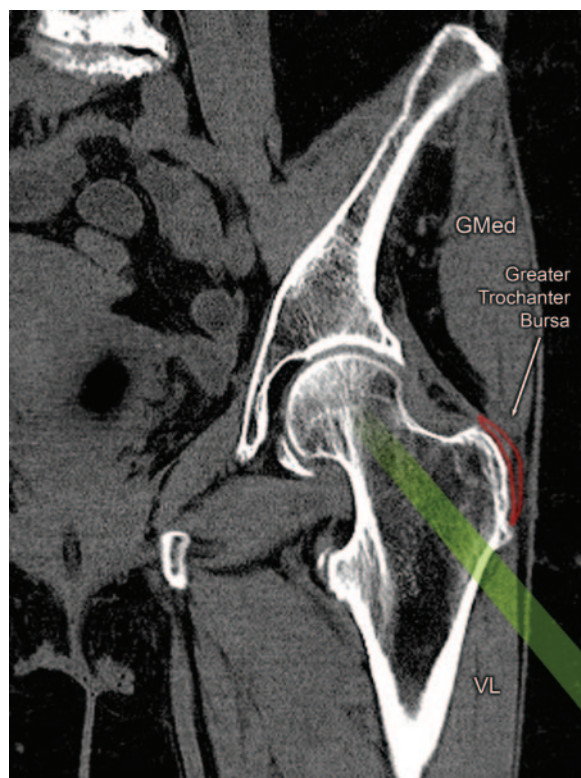
Table 4
Guidelines for Biopsy of Bone Tumors in the Forearm

Anatomic Region	Standard Surgical Incision	Vital Structures to Avoid	Recommended Biopsy Approach	Patient Position
Radius (Fig 12a)	Radial head and neck: posterolateral approach through the skin and subcutaneous fat; radial shaft: approach is generally lateral, although it is highly variable and is determined on a case-by-case basis; distal radius: direct lateral approach through the skin and subcutaneous fat	Radial nerve (superficial branch) and radial artery anterolateral to the radius (Fig 13a–13d); medial nerve anteromedial to the proximal and middle radius (Fig 13b–13d) (moves anterior to the distal portion of the radius (Fig 13e))	Radial head and neck: posterolateral approach through the skin and subcutaneous fat; radial shaft: generally medial, although approach is variable and is determined on a case-by-case basis (Fig 13b–13d); distal radius: direct lateral approach through the skin and subcutaneous fat (Fig 13e)	Varies with tumor location; rotate arm so that needle entry site is facing upward on the CT table
Ulna	Longitudinal posteromedial approach through the skin, subcutaneous fat, and a minimal portion of the flexor digitorum profundus muscle proximally (Fig 12b)	First dorsal compartment tendons (extensor pollicis brevis and abductor pollicis longus) in the distal lateral forearm (Fig 13d, 13e); extensor carpi ulnaris muscle and tendon dorsal to the distal ulna (Fig 13d, 13e)	Olecranon: direct posterior approach through the skin and subcutaneous fat (Fig 13a); posteromedial approach through the skin, subcutaneous fat, and a minimal portion of the flexor digitorum profundus muscle (Fig 13c); distal ulna: direct medial approach (Fig 13d, 13e)	Varies with tumor location; rotate arm so that needle entry site is facing upward on the CT table

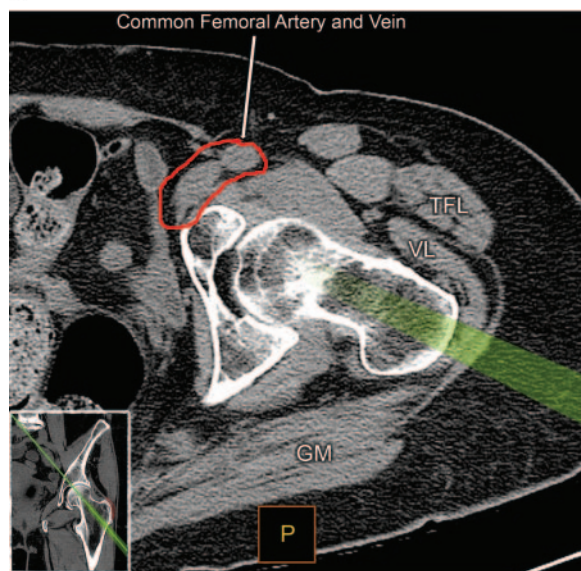
extremities from the hips to the ankles (Tables 1, 2) and from the shoulders to the wrists (Tables 3, 4). Multiple levels in each extremity segment are discussed, since the relationships of the bones, compartmental anatomy, and neurovascular structures shift as one moves from proximal to distal. These biopsy guidelines are based on the standard surgical approaches used for LSS of the extremities (14,15,36). The recommended biopsy approaches are illustrated for various anatomic regions as follows: hip and upper leg, Figures 1–5; lower leg, Figures 6–8; upper arm, Figures 9–11; and elbow and forearm, Figures 12 and 13. Although MR imaging can usually delineate soft-tissue planes and neurovascular bundles better than CT, we have chosen to illustrate these approaches with CT scans, since CT is better suited for biopsy guidance. On the whole, CT is faster and more easily accessible than MR imaging and does not require any specialized biopsy equipment.

Biopsy techniques for primary soft-tissue sarcomas of the extremities have been described in two recent articles (37,38) and will not be discussed in detail here. The recommendations for image-guided biopsy of soft-tissue sarcomas are similar to those for biopsy of bone sarcomas, although the surgical approaches for soft-tissue sarcomas are targeted more specifically to the involved compartment. Biopsy tracks should still be located along the plane of the planned incision for the definitive resection surgery as noted by the orthopedic oncologic surgeon, thereby avoiding needle penetration and contamination of uninvolved myofascial compartments.

The guidelines presented in this article are not intended to be strictly applied to all bone tumor biopsy cases, since individual patients' clinical situations and surgeons' preferences will vary.

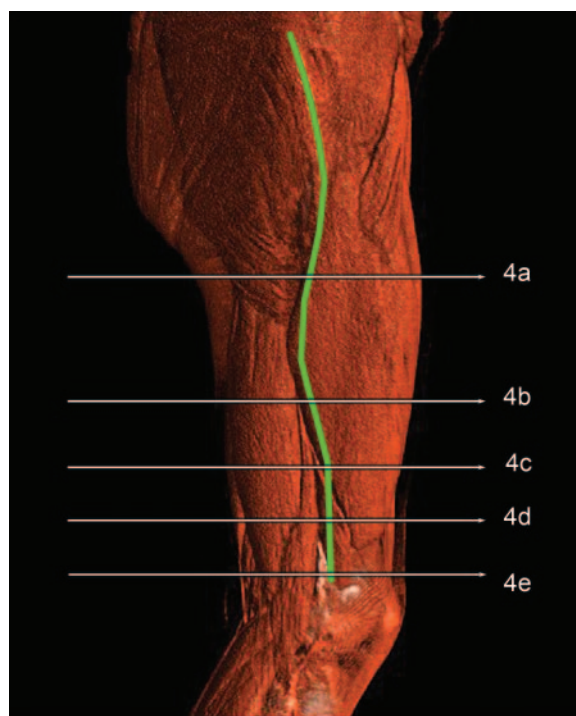


a.

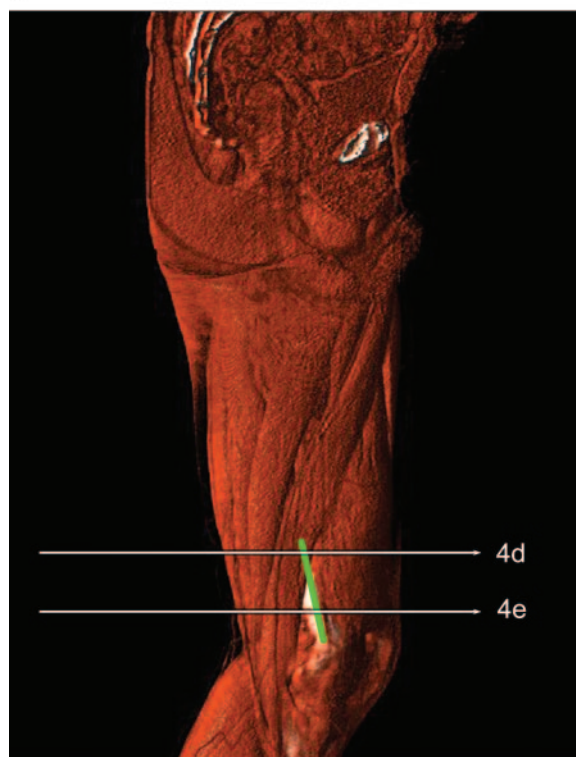


b.

Figure 2. Coronal (a) and axial oblique (b) multiplanar reformatted CT images (inset in b shows the location of the section) show a normal left hip. An angled subtrochanteric approach (green strip) should be used for biopsy of lesions in the femoral neck or head. The greater trochanter bursa (outlined in red in a) and the hip joint capsule should be avoided. GM = gluteus maximus muscle, GMed = gluteus medius muscle, TFL = tensor fascia lata muscle, VL = vastus lateralis muscle.



a.



b.

Figure 3. Three-dimensional volume-rendered (VR) CT images show a normal thigh. The green line on the lateral image (a) shows the standard lateral surgical incision site for LSS of lesions in the femur. The green line on the medial image (b) shows an additional surgical incision site for distal femoral medial lesions. Horizontal white lines indicate the levels at which the CT scans in Figure 4 were obtained.

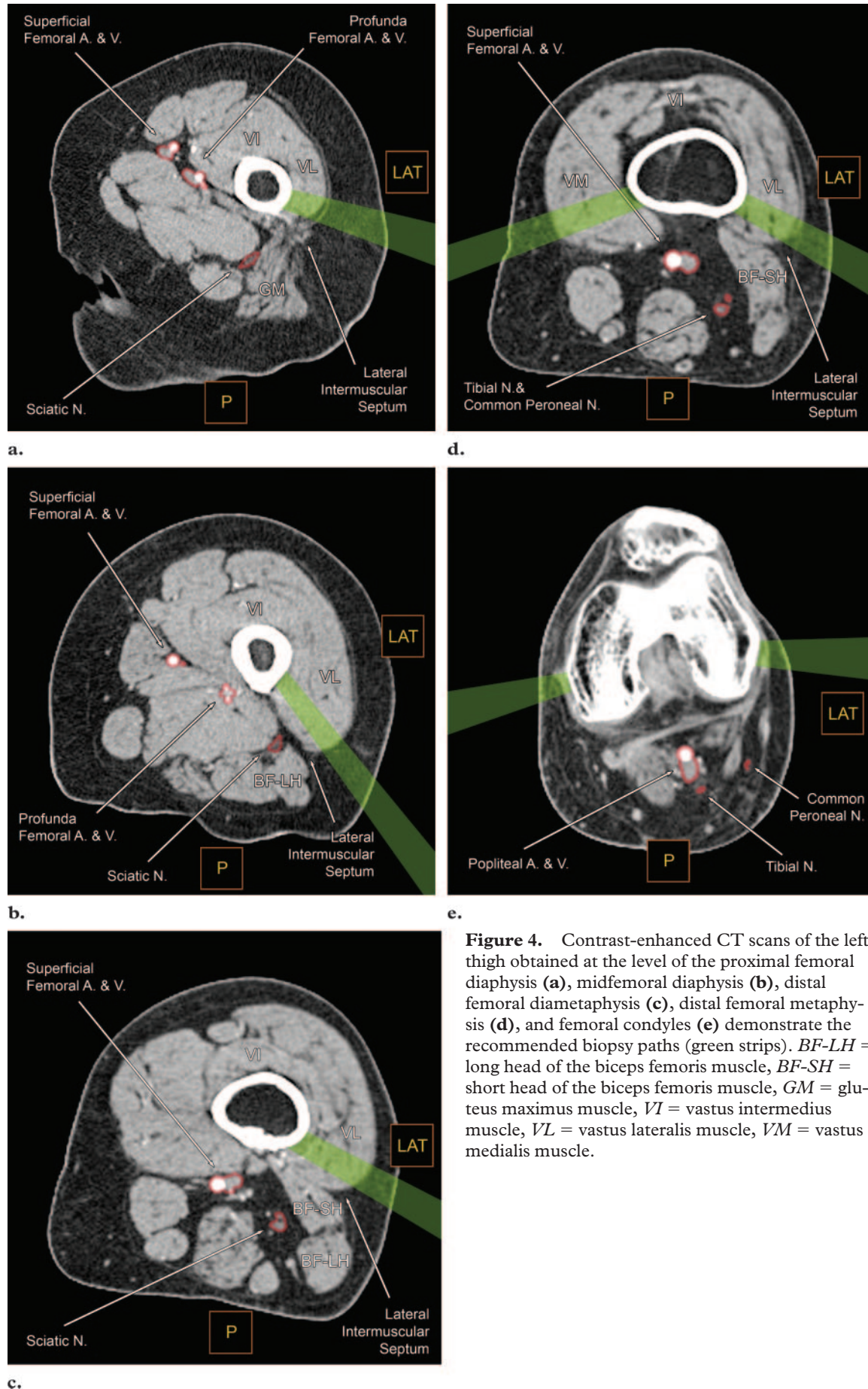
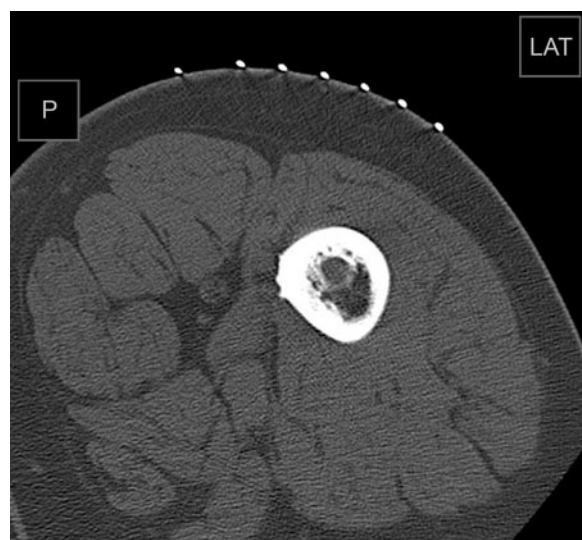
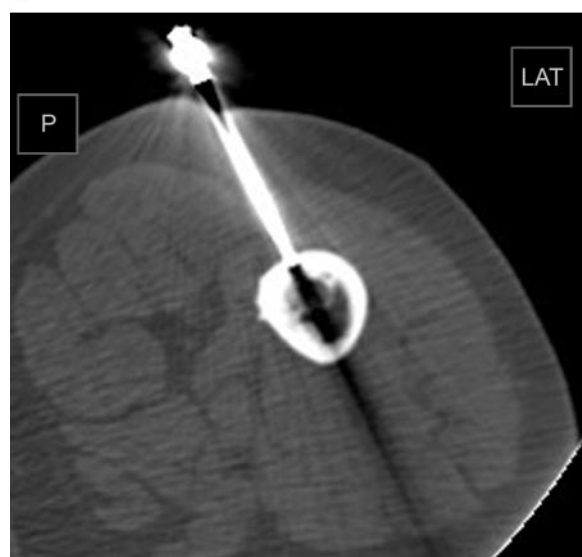


Figure 4. Contrast-enhanced CT scans of the left thigh obtained at the level of the proximal femoral diaphysis (**a**), midfemoral diaphysis (**b**), distal femoral diaphysis (**c**), distal femoral metaphysis (**d**), and femoral condyles (**e**) demonstrate the recommended biopsy paths (green strips). *BF-LH* = long head of the biceps femoris muscle, *BF-SH* = short head of the biceps femoris muscle, *GM* = gluteus maximus muscle, *VI* = vastus intermedius muscle, *VL* = vastus lateralis muscle, *VM* = vastus medialis muscle.

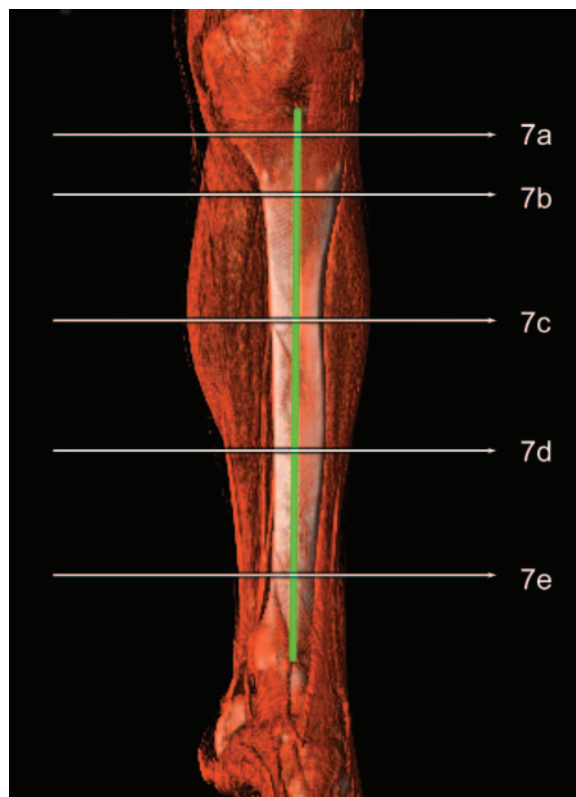


a.

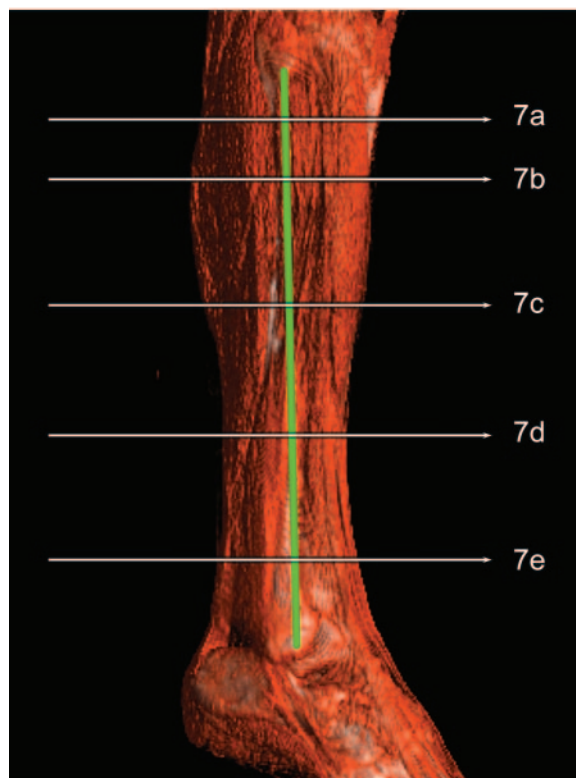


b.

Figure 5. Atypical bone infarct in the left femur at the level of the middiaphysis in a 64-year-old man. **(a)** CT scan obtained for prebiopsy planning with the patient in the left anterior oblique position shows the biopsy site facing upward. **(b)** CT fluoroscopic image obtained during biopsy shows the biopsy needle track immediately anterior to the lateral intermuscular septum.



a.



b.

Figure 6. Three-dimensional VR CT images show a normal lower leg. The green line on the anteromedial image **(a)** shows the standard surgical incision site for LSS of lesions in the tibia, whereas the green line on the lateral image **(b)** shows the standard surgical incision site for LSS of lesions in the fibula. Horizontal white lines indicate the levels at which the CT scans in Figure 7 were obtained.

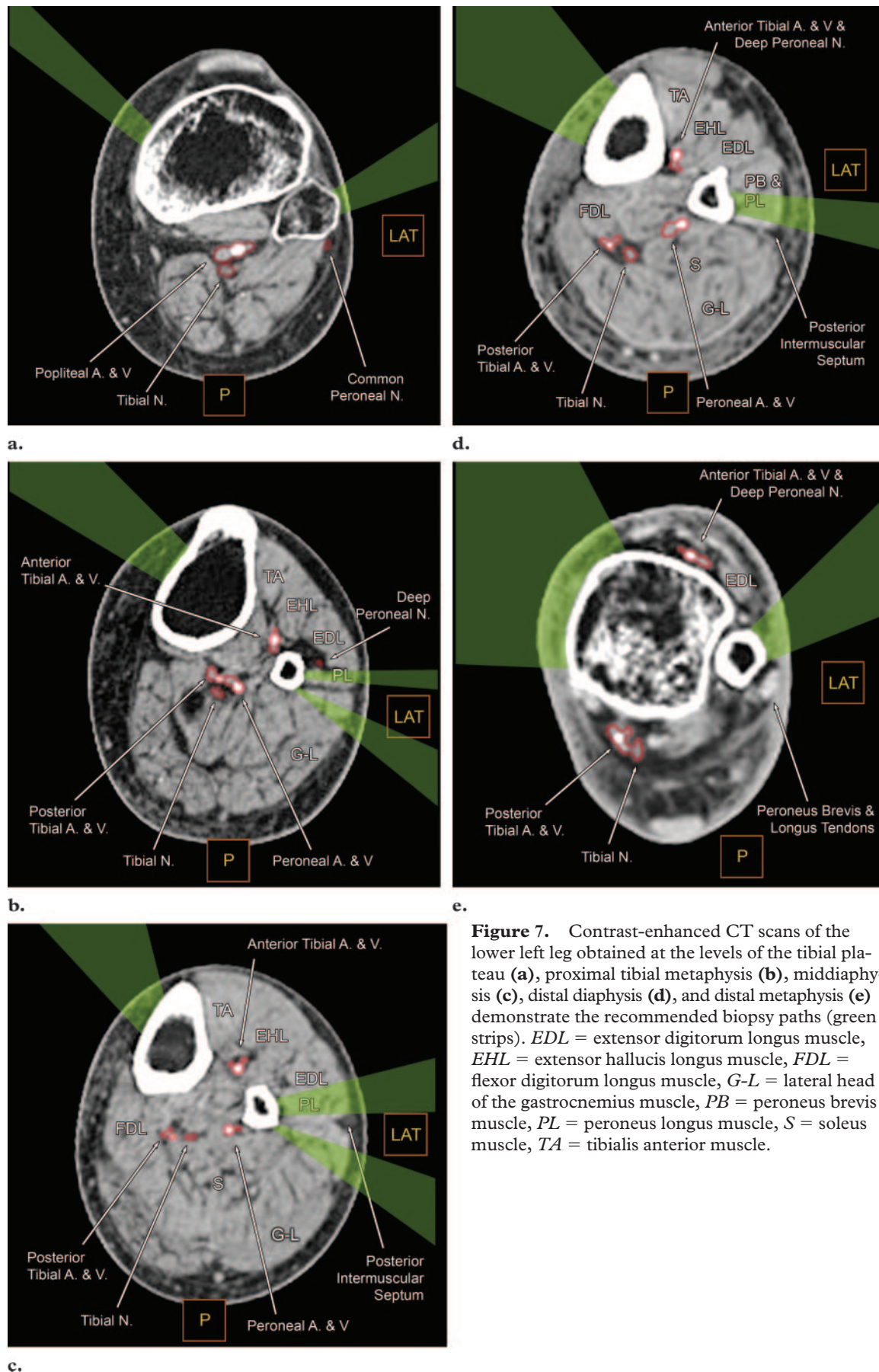
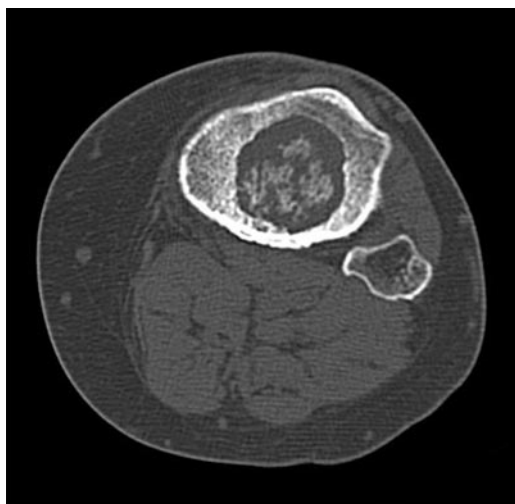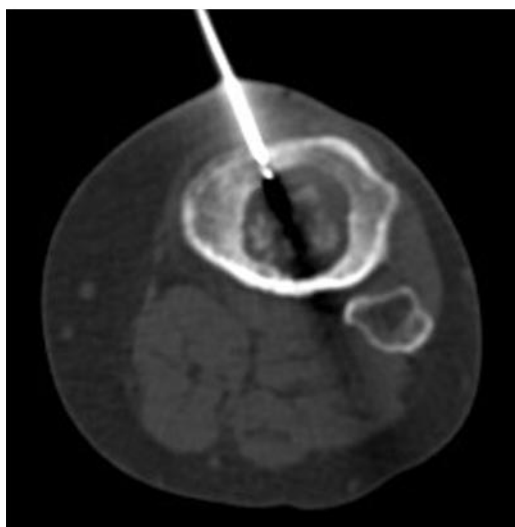


Figure 7. Contrast-enhanced CT scans of the lower left leg obtained at the levels of the tibial plateau (**a**), proximal tibial metaphysis (**b**), middiaphysis (**c**), distal diaphysis (**d**), and distal metaphysis (**e**) demonstrate the recommended biopsy paths (green strips). *EDL* = extensor digitorum longus muscle, *EHL* = extensor hallucis longus muscle, *FDL* = flexor digitorum longus muscle, *G-L* = lateral head of the gastrocnemius muscle, *PB* = peroneus brevis muscle, *PL* = peroneus longus muscle, *S* = soleus muscle, *TA* = tibialis anterior muscle.

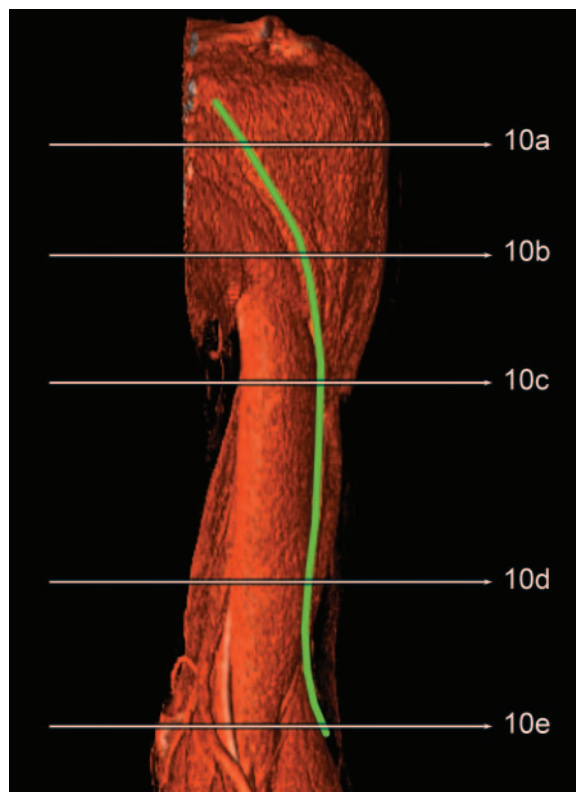


a.

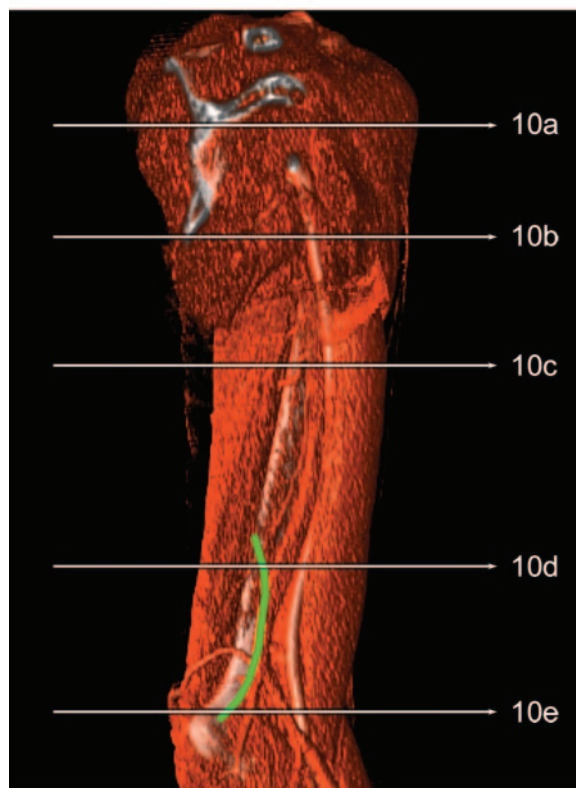


b.

Figure 8. Osteomyelitis of the left tibia at the level of the proximal metaphysis in a 45-year-old woman. **(a)** CT scan obtained for prebiopsy planning shows the biopsy site facing upward. **(b)** CT fluoroscopic image obtained during core needle biopsy illustrates the recommended anteromedial approach.



a.



b.

Figure 9. Three-dimensional VR CT images show a normal upper arm. The green line on the anterior image **(a)** shows the standard surgical incision site for LSS of lesions in the humerus. The green line on the medial image **(b)** shows the standard medial surgical incision site for LSS of lesions in the distal humerus. Horizontal white lines indicate the levels at which the CT scans in Figure 10 were obtained.

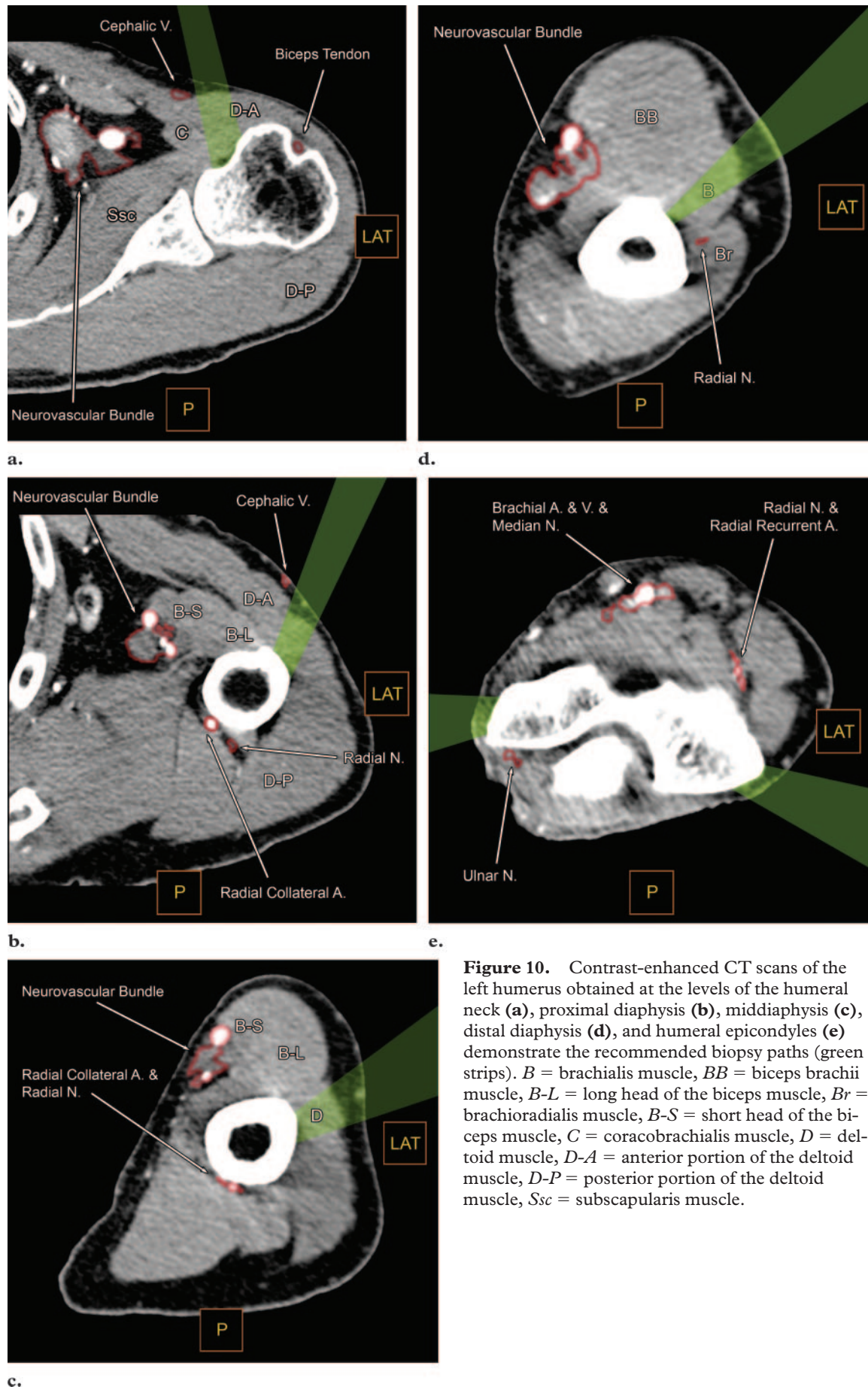
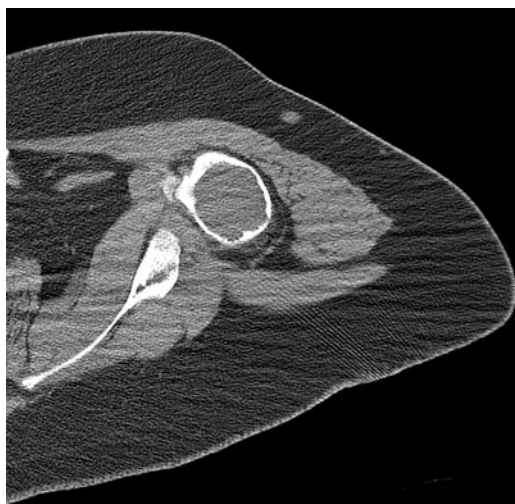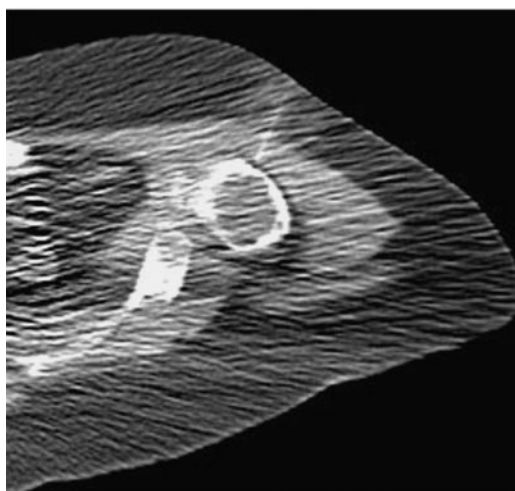


Figure 10. Contrast-enhanced CT scans of the left humerus obtained at the levels of the humeral neck (**a**), proximal diaphysis (**b**), mid-diaphysis (**c**), distal diaphysis (**d**), and humeral epicondyles (**e**) demonstrate the recommended biopsy paths (green strips). *B* = brachialis muscle, *BB* = biceps brachii muscle, *B-L* = long head of the biceps muscle, *Br* = brachioradialis muscle, *B-S* = short head of the biceps muscle, *C* = coracobrachialis muscle, *D* = deltoid muscle, *D-A* = anterior portion of the deltoid muscle, *D-P* = posterior portion of the deltoid muscle, *Ssc* = subscapularis muscle.

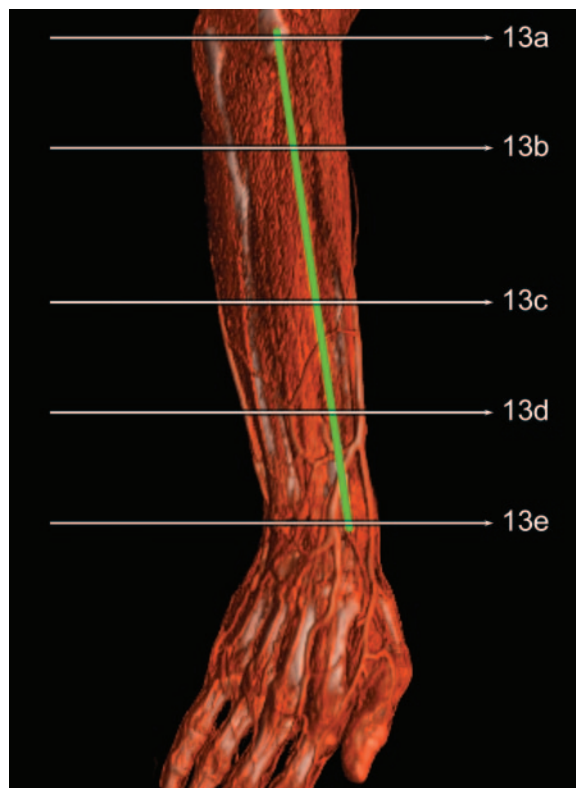

a.

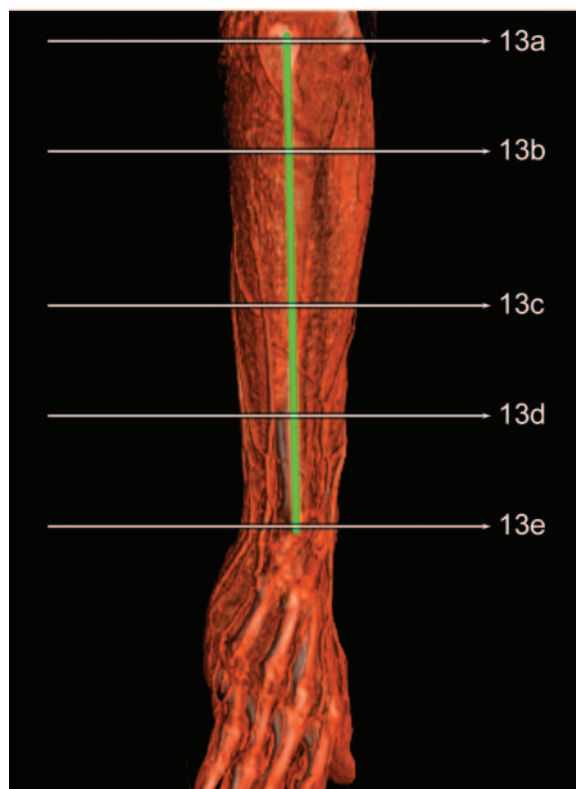

b.

Figure 11. Chondromyxoid fibroma of the proximal left humerus in a 21-year-old man. (a) CT scan obtained for prebiopsy planning shows the biopsy site facing upward. (b) CT fluoroscopic image obtained during core needle biopsy shows the biopsy track just lateral to the cephalic vein and deltopectoral groove.



a.



b.

Figure 12. Three-dimensional VR CT images show a normal forearm. The green line on the dorsolateral image (a) shows the standard incision site for LSS of lesions in the radius. The green line on the dorsomedial image (b) shows the standard surgical incision site for LSS of lesions in the ulna. Horizontal white lines indicate the levels at which the CT scans in Figure 13 were obtained.

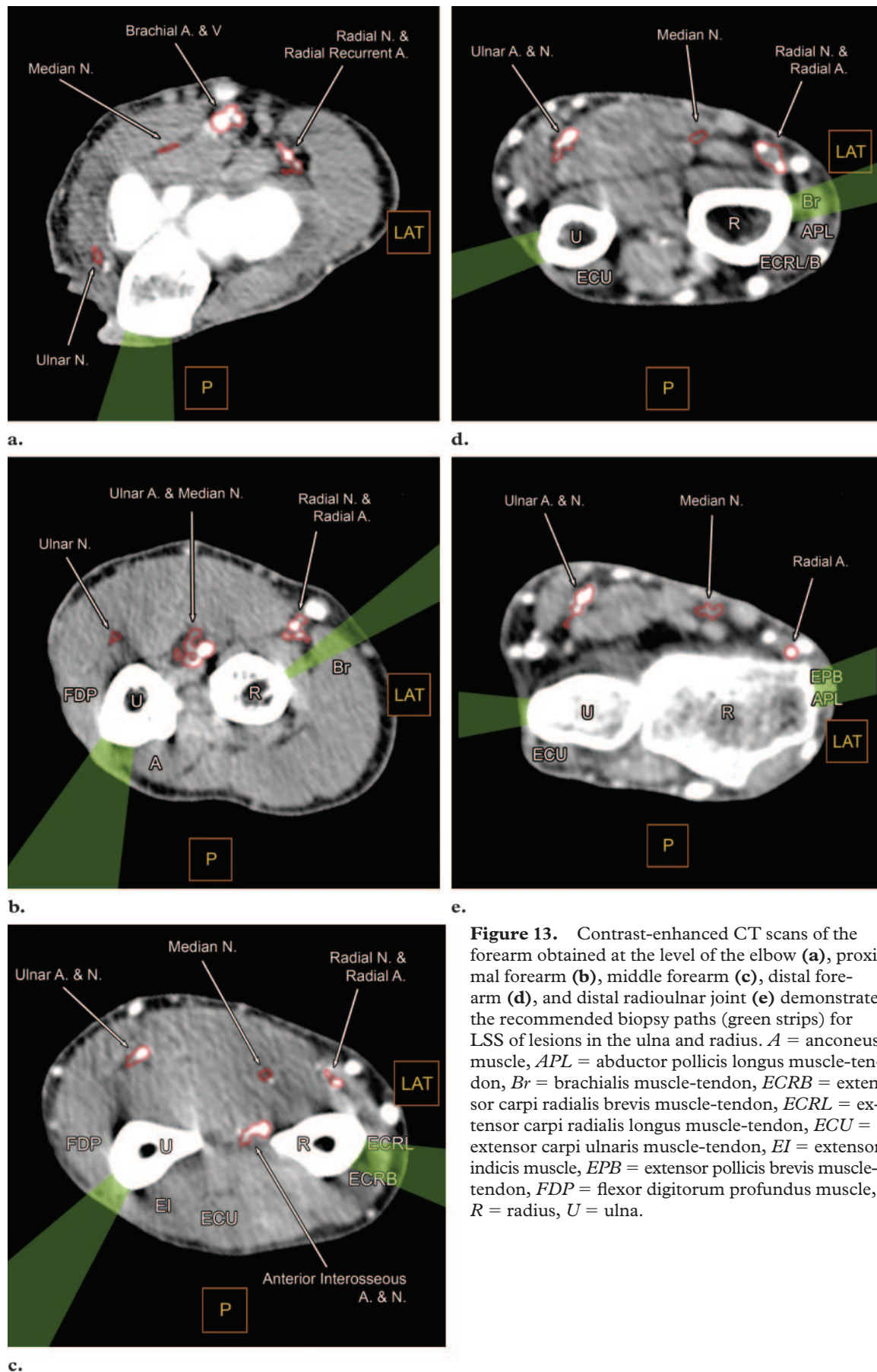


Figure 13. Contrast-enhanced CT scans of the forearm obtained at the level of the elbow (**a**), proximal forearm (**b**), middle forearm (**c**), distal forearm (**d**), and distal radioulnar joint (**e**) demonstrate the recommended biopsy paths (green strips) for LSS of lesions in the ulna and radius. *A* = anconeus muscle, *APL* = abductor pollicis longus muscle-tendon, *Br* = brachialis muscle-tendon, *ECRB* = extensor carpi radialis brevis muscle-tendon, *ECRL* = extensor carpi radialis longus muscle-tendon, *ECU* = extensor carpi ulnaris muscle-tendon, *EI* = extensor indicis muscle, *EPB* = extensor pollicis brevis muscle-tendon, *FDP* = flexor digitorum profundus muscle, *R* = radius, *U* = ulna.

For each case, we recommend that the radiologist review the relevant imaging studies with the surgeon whenever possible to determine the plane of the planned incision. Factors that may alter the usual surgical approach include (a) local tumor extension into the surrounding muscles, skin, or joint capsule; and (b) scarring and grafts from previous operations.

Because malignancies in the hands and feet call for surgical approaches to resection that will vary widely depending on tumor location, biopsy planning for masses in these regions is beyond the scope of this article. These biopsies should be performed only after the orthopedic surgeon has first been consulted regarding his or her planned approach for tumor resection.

Biopsy Technique

The choice of bone biopsy needle depends on the location of the lesion within the bone, the integrity of the overlying bone cortex, and the internal consistency of the target lesion. For lesions located more than a few centimeters beneath the skin, a coaxial system will allow multiple biopsy passes through a stationary sheath. Multiple sites within a lesion should be sampled to avoid nondiagnostic results that could arise from sampling a region of tumor necrosis or cystic degeneration.

If the lesion is intramedullary and covered by intact bone cortex, a biopsy needle system with a drill tip will provide the easiest and quickest access. Of the many bone biopsy needles that are commercially available, we have found the RADI Bonoptoy coaxial drill and biopsy needle system (RADI Medical Systems, Uppsala, Sweden), with a 14-gauge sheath and eccentrically cutting 15-gauge drill tip, to be the most effective in penetrating intact cortical bone (11).

Once the target lesion has been accessed, the internal consistency of the lesion will guide the choice of the core biopsy needle. For "hard" lesions that are sclerotic, calcified, ossified, or composed of intact trabeculae infiltrated with tumor cells, biopsy should be performed with a stiff bone-cutting needle at least 15 gauge in diameter. Fine-needle aspiration of hard lesions should be performed after core biopsy has been performed, with a needle 22 gauge or smaller. Without the access to the interior of a hard lesion afforded by a bone-cutting needle, the aspiration of material from the center of the lesion with a thin, flexible needle would be difficult.

In contrast, "soft" lesions that are composed of soft tissue or fluid usually yield little diagnostic tissue when sampled with bone-cutting needles.

Adding vacuum suction by attaching a syringe to a bone-cutting needle, or substituting a soft-tissue biopsy needle combined with a vacuum syringe, will provide the highest biopsy yield for these soft lesions (39). Numerous soft-tissue biopsy needles are commercially available, and all of them typically yield satisfactory biopsy specimens.

Spring-loaded core biopsy needles are not well suited for bone biopsies. In hard lesions, the spring mechanism and needle are insufficiently strong for biopsy of intact or sclerotic bone. In soft lesions that are adjacent to or surrounded by intact bone, the use of these spring-loaded needles may be problematic owing to the possibility of damage to the fragile trochar.

Conclusions

By using the anatomically based guidelines presented in this article in combination with case-by-case consultation with the orthopedic oncologic surgeon, the radiologist should be able to plan a core needle biopsy of an indeterminate bone lesion in a manner that will ensure the patient's chances of receiving optimal surgical treatment. If the biopsy results confirm the diagnosis of a primary bone sarcoma and LSS is elected, the surgeon will be able to resect the biopsy track using a standard incision, without the need for additional soft-tissue resection, radiation therapy, or amputation.

References

1. DiCaprio MR, Friedlaender GE. Malignant bone tumors: limb sparing versus amputation. *J Am Acad Orthop Surg* 2003;11(1):25-37.
2. Eckardt JJ, Eilber FR, Dorey FJ, Mirra JM. The UCLA experience in limb salvage surgery for malignant tumors. *Orthopedics* 1985;8(5):612-621.
3. Sim FH, Bowman WE Jr, Wilkins RM, Chao EY. Limb salvage in primary malignant bone tumors. *Orthopedics* 1985;8(5):574-581.
4. Hosalkar HS, Dormans JP. Limb sparing surgery for pediatric musculoskeletal tumors. *Pediatr Blood Cancer* 2004;42(4):295-310.
5. deSantos LA, Murray JA, Ayala AG. The value of percutaneous needle biopsy in the management of primary tumors. *Cancer* 1979;43(2):735-744.
6. Yao L, Nelson SD, Seeger LL, Eckardt JJ, Eilber FR. Primary musculoskeletal neoplasms: effectiveness of core-needle biopsy. *Radiology* 1999;212(3):682-686.
7. Welker JA, Henshaw RM, Jelinek J, Shmookler BM, Malawer MM. The percutaneous needle biopsy is safe and recommended in the diagnosis of musculoskeletal masses. *Cancer* 2000;89(12):2677-2686.
8. Skrzynski MC, Biermann JS, Montag A, Simon MA. Diagnostic accuracy and charge-savings of outpatient core needle biopsy compared with open biopsy of musculoskeletal tumors. *J Bone Joint Surg Am* 1996;78(5):644-649.

9. Schwartz HS, Spengler DM. Needle tract recurrences after closed biopsy for sarcoma: three cases and review of the literature. *Ann Surg Oncol* 1997; 4(3):228–236.
10. Davies NM, Livesley PJ, Cannon SR. Recurrence of an osteosarcoma in a needle biopsy track. *J Bone Joint Surg Br* 1993;75(6):977–978.
11. Roberts CC, Morrison WB, Leslie KO, Carrino JA, Lozevski JL, Liu PT. Assessment of bone biopsy needles for sample size, specimen quality and ease of use. *Skeletal Radiol* 2005;34(6):329–335.
12. Mankin HJ, Lange TA, Spanier SS. The hazards of biopsy in patients with malignant primary bone and soft-tissue tumors. *J Bone Joint Surg Am* 1982;64(8):1121–1127.
13. Mankin HJ, Mankin CJ, Simon MA. The hazards of the biopsy, revisited. Members of the Musculoskeletal Tumor Society. *J Bone Joint Surg Am* 1996;78(5):656–663.
14. Simon MA, Springfield D. Surgery for bone and soft-tissue tumors. Philadelphia, Pa: Lippincott-Raven, 1998.
15. Enneking WF. Musculoskeletal tumor surgery. New York, NY: Churchill Livingstone, 1983.
16. Bacci G, Ferrari S, Longhi A, et al. Therapy and survival after recurrence of Ewing's tumors: the Rizzoli experience in 195 patients treated with adjuvant and neoadjuvant chemotherapy from 1979 to 1997. *Ann Oncol* 2003;14(11):1654–1659.
17. Bacci G, Briccoli A, Longhi A, et al. Treatment and outcome of recurrent osteosarcoma: experience at Rizzoli in 235 patients initially treated with neoadjuvant chemotherapy. *Acta Oncol* 2005; 44(7):748–755.
18. Picci P, Sangiorgi L, Bahamonde L, et al. Risk factors for local recurrences after limb-salvage surgery for high-grade osteosarcoma of the extremities. *Ann Oncol* 1997;8(9):899–903.
19. Kilpatrick SE, Cappellari JO, Bos GD, Gold SH, Ward WG. Is fine-needle aspiration biopsy a practical alternative to open biopsy for the primary diagnosis of sarcoma? experience with 140 patients. *Am J Clin Pathol* 2001;115(1):59–68.
20. Kosciak RL, Petersilge CA, Makley JT, Abdulkarim FW. CT-guided fine needle aspiration and needle core biopsy of skeletal lesions: complementary diagnostic techniques. *Acta Cytol* 1998;42(3): 697–702.
21. Leffler SG, Chew FS. CT-guided percutaneous biopsy of sclerotic bone lesions: diagnostic yield and accuracy. *AJR Am J Roentgenol* 1999;172(5): 1389–1392.
22. Schweitzer ME, Gannon FH, Deely DM, O'Hara BJ, Juneja V. Percutaneous skeletal aspiration and core biopsy: complementary techniques. *AJR Am J Roentgenol* 1996;166(2):415–418.
23. Sundaram M, Totty WG, Kyriakos M, McDonald DJ, Merkel K. Imaging findings in pseudocystic osteosarcoma. *AJR Am J Roentgenol* 2001;176(3): 783–788.
24. Bickels J, Jelinek JS, Shmookler BM, Neff RS, Malawer MM. Biopsy of musculoskeletal tumors: current concepts. *Clin Orthop Relat Res* 1999; 368:212–219.
25. van Trommel MF, Kroon HM, Bloem JL, Hogenboom PC, Taminiau AH. MR imaging based strategies in limb salvage surgery for osteosarcoma of the distal femur. *Skeletal Radiol* 1997;26(11): 636–641.
26. Harter LP, Curtis JS, Ponto G, Craig PH. Malignant seeding of the needle track during stereotactic core needle breast biopsy. *Radiology* 1992;185(3): 713–714.
27. Vergara V, Garripoli A, Marucci MM, Bonino F, Capussotti L. Colon cancer seeding after percutaneous fine needle aspiration of liver metastasis. *J Hepatol* 1993;18(3):276–278.
28. Ayar D, Golla B, Lee JY, Nath H. Needle-track metastasis after transthoracic needle biopsy. *J Thorac Imaging* 1998;13(1):2–6.
29. Kim SH, Lim HK, Lee WJ, Cho JM, Jang HJ. Needle-tract implantation in hepatocellular carcinoma: frequency and CT findings after biopsy with a 19.5-gauge automated biopsy gun. *Abdom Imaging* 2000;25(3):246–250.
30. Chao C, Torosian MH, Boraas MC, et al. Local recurrence of breast cancer in the stereotactic core needle biopsy site: case reports and review of the literature. *Breast J* 2001;7(2):124–127.
31. Karwowski JK, Nowels KW, McDougall IR, Weigel RJ. Needle track seeding of papillary thyroid carcinoma from fine needle aspiration biopsy: a case report. *Acta Cytol* 2002;46(3):591–595.
32. Kosugi C, Furuse J, Ishii H, et al. Needle tract implantation of hepatocellular carcinoma and pancreatic carcinoma after ultrasound-guided percutaneous puncture: clinical and pathologic characteristics and the treatment of needle tract implantation. *World J Surg* 2004;28(1):29–32.
33. Vaghefi H, Magi-Galluzzi C, Klein EA. Local recurrence of prostate cancer in rectal submucosa after transrectal needle biopsy and radical prostatectomy. *Urology* 2005;66(4):881.
34. Logan PM, Connell DG, O'Connell JX, Munk PL, Janzen DL. Image-guided percutaneous biopsy of musculoskeletal tumors: an algorithm for selection of specific biopsy techniques. *AJR Am J Roentgenol* 1996;166(1):137–141.
35. Kattapuram SV, Rosenthal DI. Percutaneous biopsy of skeletal lesions. *AJR Am J Roentgenol* 1991;157(5):935–942.
36. Hoppenfeld S. Surgical exposures in orthopedics: the anatomic approach. 3rd ed. Philadelphia, Pa: Lippincott Williams & Wilkins, 2003.
37. Anderson MW, Temple HT, Dussault RG, Kaplan PA. Compartmental anatomy: relevance to staging and biopsy of musculoskeletal tumors. *AJR Am J Roentgenol* 1999;173(6):1663–1671.
38. Toomayan GA, Robertson F, Major NM. Lower extremity compartmental anatomy: clinical relevance to radiologists. *Skeletal Radiol* 2005;34(6): 307–313.
39. White LM, Schweitzer ME, Deely DM. Coaxial percutaneous needle biopsy of osteolytic lesions with intact cortical bone. *AJR Am J Roentgenol* 1996;166(1):143–144.

Anatomically Based Guidelines for Core Needle Biopsy of Bone Tumors with Respect to Limb-sparing Surgery

Patrick T. Liu, MD et al

RadioGraphics 2007; 27:189–206 • Published online 10.1148/rg.271065092 • Content Codes: **MK** **OI** **VI**

Page 190

Bone sarcomas have been shown to recur locally from tumor seeding along biopsy tracks after core needle biopsy (9,10), procedures that are generally performed with needles 16 gauge or larger (11).

Page 190

With the exception of a few benign bone lesions that may have characteristic imaging appearances (eg, fibrous dysplasia, osteochondroma, fibrous cortical defects), it is difficult to exclude sarcoma in solitary bone lesions on the basis of imaging findings alone.

Page 191

If a core needle bone biopsy were to pass through tissues outside the planned incision plane, the surgical procedure may have to be altered to include the potentially contaminated tissue in the resection. Less attractive alternatives for the patient would consist of either a wider irradiation field (if the tumor is radiosensitive) or a greater chance of local tumor recurrence at the biopsy site (Fig 1).

Page 191

A multicenter study conducted by the Musculoskeletal Tumor Society in 1996 (13) showed that inappropriately performed biopsies of musculoskeletal tumors posed a significant clinical problem. In a review of 597 cases, the authors found that 19% of patients with musculoskeletal tumors had encountered problems with initial image-guided and open biopsy that forced the orthopedic oncologic surgeon to perform more complex resection or order additional chemotherapy or radiation therapy (13).

Page 191

Probably the major reason these deficiencies exist among the general radiology community is that the need to coordinate biopsy approaches with surgical plans is unique to musculoskeletal tumors and, therefore, not widely known among radiologists in other subspecialty areas.