



# Current Concepts of Shoulder Arthroplasty for Radiologists: Part I—Epidemiology, History, Preoperative Imaging, and Hemiarthroplasty

Jonelle M. Petscavage<sup>1</sup>  
Alice S. Ha<sup>2</sup>  
Felix S. Chew<sup>2</sup>

**OBJECTIVE.** The purpose of this article is to provide a review of indications for shoulder arthroplasty, describe preoperative imaging assessment, present new and modified designs of shoulder arthroplasty, illustrate normal and abnormal postoperative imaging findings, and review key radiographic measurements.

**CONCLUSION.** Knowledge of the physiologic purpose, orthopedic trends, imaging findings, and complications is important in assessing shoulder prostheses.

**R**everse total shoulder arthroplasty, anatomic total shoulder arthroplasty, humeral head resurfacing, and hemiarthroplasty are increasingly common in orthopedic surgery practice. Successful radiologic evaluation of these different types of shoulder reconstruction requires an understanding of their fundamental hardware design, physiologic objective, normal postoperative imaging appearance, and the appearance of complications. Part 1 of this concepts review will detail the epidemiology and history of shoulder arthroplasty, preoperative imaging assessment, humeral head resurfacing, and hemiarthroplasty. Part 2 will review anatomic total shoulder arthroplasty, reverse total shoulder arthroplasty, and nonprosthetic glenoid resurfacing options for younger patients.

## Epidemiology of Shoulder Arthroses

Arthroses of the shoulder are common in aging adults and can result in significant pain, decreased range of motion, and diminished quality of life [1]. The exact incidence of glenohumeral arthroses is unknown because unlike in the knee and hip joints articular lesions may be asymptomatic in the shoulder [2]. In 200 patients undergoing arthroscopy for full-thickness rotator cuff tears, 13% had coexisting chondral injuries [3]. Primary osteoarthritis of the glenohumeral joint is less common than secondary osteoarthritis due to mechanisms such as trauma, chondrolysis, avascular necrosis, inflammatory arthropathy, repeated microtrauma in throwing athletes, and joint instability.

## Alternative Treatment Options for Shoulder Arthroses

Nonsurgical therapies remain the preferred treatment option for most patients with glenohumeral arthrosis. Nonsteroidal antiinflammatory drugs with and without physical therapy remains the primary treatment, especially for patients with low demand and subacute onset of symptoms. Intraarticular injection of steroids or viscosupplements (such as hyaluronic acid) provides only temporary relief [2].

Surgical options include arthroscopic débridement for chondral injury, microfracture and osteochondral grafts, and capsular release. Subacromial decompression may be indicated in patients with mild to moderate arthroses and concomitant impingement symptoms [2].

## Historical Perspective

Jules E. Pean performed the first shoulder replacement in 1893 in a 37-year-old patient with tuberculous arthritis [4]. The arthroplasty consisted of an iridescent platinum tube, a hardened rubber ball coated with paraffin, and two metal loops that attached the ball to the scapula and the tube (Fig. 1). The prosthesis provided positive functional outcomes but was removed 2 years later because of infection. During the 1950s, Krueger, Judet, and deAnquin attempted total shoulder arthroplasty using acrylic molded components [5]. However, the material was not durable.

In 1974, the Neer type 2 prosthesis was the first modern anatomic total shoulder replacement, consisting of a vitallium humeral component and polyethylene glenoid component

**Keywords:** glenoid resurfacing, humeral head resurfacing, reverse arthroplasty, shoulder arthroplasty

DOI:10.2214/AJR.12.8854

Received March 4, 2012; accepted after revision April 27, 2012.

A. S. Ha has received a grant from GE Healthcare. J. M. Petscavage is a consultant for Medical Metrics, Inc.

<sup>1</sup>Department of Radiology, Penn State Hershey Medical Center, 500 University Dr, Hershey, PA 17033. Address correspondence to J. M. Petscavage (jpetscavage@hmc.psu.edu).

<sup>2</sup>Department of Radiology, University of Washington Medical Center, Seattle, WA.

## CME/SAM

This article is available for CME/SAM credit.

AJR 2012; 199:757–767

0361–803X/12/1994–757

© American Roentgen Ray Society

[6]. These implants were successful except for high failure rates of glenoid loosening and superior impingement in patients with rotator cuff deficiency. In response, in 1985, the reverse total shoulder arthroplasty was designed to shift the center of rotation at the shoulder joint and compensate for those with a deficient rotator cuff [7].

Charles Neer [8] implanted the first hemiarthroplasty for a humeral head fracture in the 1950s. Modifications in this design have occurred in combination with advances in anatomic total shoulder arthroplasty because similar stemmed humeral components are used. Meanwhile, Steffee and Moore [9] placed the first humeral head resurfacing in the late 1970s using a hip resurfacing implant to fit the dimensions of the humeral head. The goal of the design was to retain the humeral neck and > 50% of the humeral head to restore normal biomechanics. A recent biomechanical study showed lower rates of glenoid wear with resurfacing arthroplasty than standard hemiarthroplasty designs [10]. A new concept in the past 5 years is use of partial resurfacing of the humeral head for focal osteochondral defects, trauma, and avascular necrosis.

Ultimately, over the past several decades, more than 70 modifications in prosthetic shoulder design have been made. This article will review the currently used prosthetic designs.

## Epidemiology of Shoulder Arthroplasty

There was a steady increase in the number of both hemiarthroplasty and total shoulder arthroplasty procedures performed in the United States between 1993 and 2008 [11]. With an overall aging population, more than two thirds of the total shoulder arthroplasties are performed annually on patients older than 65 years. Kim et al. [11] noted a relative increase of total shoulder arthroplasty over hemiarthroplasty starting in 2003, likely related to introduction of the reverse total shoulder arthroplasty. In 2008 alone, approximately 27,000 total shoulder arthroplasties and 20,000 hemiarthroplasties were performed [11]. Osteoarthritis accounted for the primary diagnoses in 77% of total shoulder arthroplasty cases and 43% of hemiarthroplasty cases. The second most common diagnosis for hemiarthroplasty was proximal humeral fracture (33%).

## Preoperative Radiologic Evaluation and Measurements

Several important radiologic assessments should be made on preoperative imaging stud-

ies. Rotator cuff integrity impacts the type of arthroplasty placed. Tendon tears and fatty muscle degeneration of the rotator cuff, particularly the infraspinatus, have been shown to correlate with reduced acromiohumeral distance [12]. On an anteroposterior radiograph, an acromiohumeral distance  $\leq 7$  mm with superior subluxation of the humeral head suggests a large rotator cuff tear (Fig. 2). Other findings indicative of multiple tendon tears include greater tuberosity sclerosis or irregularity, cysts at the greater tuberosity, "acetabularization" of the acromion (remodeling of undersurface due to high riding humeral head), and exaggerated groove between the greater tuberosity and the humeral articular surface [13]. In equivocal cases without these radiographic findings, ultrasound or MRI can be used to differentiate tears without tendon retraction from partial tears or an intact cuff.

Contracture or tear of the subscapularis tendon can result in anterior instability if not corrected or recognized preoperatively [14]. Preoperative radiographs should be assessed for anterior subluxation of the humerus on the axillary view. The humeral head is considered centered in the glenoid if the distance between the center of the humeral head and the center of the glenoid are within 25% of the humeral head diameter.

Another important preoperative assessment is the glenoid fossa morphology. In moderate to severe glenohumeral osteoarthritis, erosive changes and wear are usually greater in the posterior half of the glenoid articular surface, thus increasing glenoid retroversion [15]. The Walch classification of glenoid morphology is assessed on axillary radiographs or CT (Fig. 3). Type A morphology is a centered humeral head with (A1) minor or (A2) major erosions. Type B describes a posteriorly subluxed humeral head with (B1) posterior joint space narrowing and osteophytes or (B2) posterior rim erosions and glenoid retroversion ( $> 2^\circ$ ). Type C is the most severe, with glenoid retroversion of more than  $25^\circ$ .

Studies have shown that failure to correct glenoid retroversion predisposes to joint instability, posterior subluxation, and glenoid component loosening due to abnormal forces across the implant and cement-bone interfaces [16]. It is recommended that surgeons either graft the erosions or ream the glenoid in an attempt to align the glenoid prosthesis perpendicular to the scapular axis. Before CT, the glenoid version was measured on axillary radiographs. However, radiographs have been shown ineffective in assessing the glenoid

version because of overlapping bones, variation in radiographic technique, and variability and complexity of scapular anatomy [17].

Friedman et al. [18] defined the glenoid version as the angle between a line drawn from the medial border of the scapula to the center of the glenoid and the line perpendicular to the face of the glenoid on the axial 2D CT slice at or just below the tip of the coracoid (Fig. 4A). However, axial 2D CT version measurements depend on the relation of the plane of the scapula to the axis of the CT scanner. It has been shown that every  $1^\circ$  of abduction of the scapula increases the value of glenoid anteversion by a mean of  $0.42^\circ$  [19]. Hoenecke et al. [20] showed 3D CT to be more accurate in detecting posterior glenoid erosion. Another study showed greater than  $5^\circ$  difference in measurements of version between 2D CT and 3D CT images in nearly 50% of patients [21].

Thus, 3D CT is suggested as the most accurate preoperative means of assessing glenoid version and morphology. On 3D CT, a vertical line can be drawn on the 3D surface of the glenoid face, centered in the anteroposterior direction (Fig. 4B). A transverse 2D plane is then generated perpendicular to the midpoint of the vertical line passing through the scapular axis (center of glenoid and tip of scapular spine) to obtain an image for glenoid version angle measurement [21] (Fig. 4C).

## Humeral Head Resurfacing

### Indications

The concept of humeral head resurfacing was introduced as a means of preserving the humeral head in younger active patients, allowing native humeral head inclination and humeral head-shaft angle [22]. The native humeral head-shaft angle is intact because no osteotomy is performed [23]. This bypasses the risk of periprosthetic fracture of the humeral shaft in a stemmed implant and preserves bone stock for future revision surgery [24]. Additionally, it is an option for patients with extraarticular humeral deformities, such as malunited proximal humeral fractures and congenital defects.

The procedure involves reaming of the proximal portion of the humeral head and fitting a metal-alloy cap over the remainder of the humeral head. This can be paired with a glenoid component if desired. Contraindications of humeral head resurfacing include inadequate bone stock and four-part humeral fractures [23]. Several studies have shown improved postoperative Constant scores and functional outcomes after resurfacing arthroplasty [25, 26].

## Imaging Shoulder Arthroplasty

Partial humeral head resurfacing is indicated for osteonecrosis, focal osteoarthritis of the humeral head, cuff tear arthropathy, focal erosions, Hill-Sachs lesions, and focal chondral defects of the humerus [24]. Benefits include fewer MRI and CT artifacts, intact soft-tissue envelope and bone anatomy of the joint, and shorter surgical time. The largest series of patients undergoing partial humeral head resurfacing showed that 95% of patients reported good-to-excellent results and had improved Constant scores [27].

### Design

Total humeral head resurfacing consists of a cemented or press-fit metal articular-capped component stabilized by a grooved stem of variable shape, diameter, and length (Fig. 5). Partial resurfacing involves an articular cobalt-chromium-alloy surface component with a small central peg that mates with a tapered post, which is a headless titanium-cannulated screw (Fig. 6).

### Imaging

On radiographs, the resurfacing cap should be flush against the bone and centered on the glenoid on the lateral view. There should be no radiolucency surrounding the peg. Reported complications of humeral head resurfacing include loosening, particularly on the glenoid side; proximal migration of the cup and glenoid wear; arthrofibrosis; subscapularis tendon rupture; instability with subluxation (Fig. 7); and two cases of periprosthetic fracture [22, 24]. The main clinical trials have shown no complications of partial humeral head resurfacing [24, 27].

## Hemiarthroplasty

### Indications

Hemiarthroplasty is indicated in patients with severe proximal humerus fractures (3- or 4-part), arthritis in which glenoid bone stock is inadequate to support a prosthesis, and osteonecrosis or osteoarthritis without glenoid involvement [28, 29]. Hemiarthroplasty is not preferred for moderate or severe osteoarthritis because a meta-analysis of 23 trials showed total shoulder arthroplasty to provide significantly greater pain relief, forward elevation, gain in forward elevation and external rotation, patient satisfaction, and lower revision rates when compared with hemiarthroplasty [30].

### Design

Hemiarthroplasty usually consists of the stemmed metal humeral component of ana-

tomic total shoulder arthroplasty without an accompanying glenoid component (Fig. 8A). The humeral component is a minimally constrained anatomic implant consisting of a spherical metal articular surface and cemented or press-fit metal stem. In patients with rotator cuff tears and narrowing of the acromial-humeral distance, an extended-coverage humeral head (cuff tear arthroplasty) design may be used (Fig. 8B). The head extends laterally over the greater tuberosity, decreasing contact and impingement between the acromion and greater tuberosity. The head should not overhang anteriorly because of the risk of impingement on the subscapularis tendon [29].

Unlike the smooth contour of the original Neer components, modern humeral components are surface-textured or cemented. Cementing offers the advantages of lower mechanical failure, ability to add antibiotics to the cement to prevent infection, and stability in patients with poor bone stock. Disadvantages include difficulty of removal at revision surgery and rare cases of radial nerve injury from cement extrusion [31].

Oncologic humeral prostheses may or may not allow reconstruction of the rotator cuff for additional joint stability (Fig. 9). Rotator cuff reconstruction requires suture holes in the humeral prosthesis for direct attachment or a nylon/polyester (Dacron, Invista) mesh capsuloplasty for indirect attachment of the rotator cuff [32].

### Imaging and Issues in Hemiarthroplasty

Routine radiographs should include true anteroposterior views in both internal and external rotation and an axillary view. The humeral stem should be centered in the humeral shaft. The complication of excessive lateral or medial translation can result in altered load distribution, cortical bone resorption, and rotator cuff and deltoid insufficiency [33]. The height of the humeral component should be 2–5 mm measured between a line perpendicular to the greater tuberosity and a second line along the head of the prosthesis. Subsidence reflects a decrease in this vertical distance and is a clinically significant complication if the distance changes by > 5 mm [34] (Fig. 10A). Additionally, an increase in this vertical distance resulting in an acromial humeral distance < 2 mm (Fig. 9B) reflects either overstuffing, new rotator cuff tear, subacromial impingement from acromial spurs, or “overstuffing” from too large a head component [33].

The axillary view is best for assessing anterior or posterior subluxation of the humeral head,

classified as absent, slight (translation < 25%), moderate (25–50%), or severe (> 50%) [35] (Fig. 11). Additional radiographic complications of hemiarthroplasty include glenoid erosions and arthritis, occurring in up to 64% of patients [28] (Fig. 12). Subscapularis tendon tearing is a unique complication of cuff tear arthroplasty design and is seen on radiographs as progressive anterior subluxation of the humeral component.

Radiolucency about the humeral component > 0.5 mm should be noted for size, progression, and location because it may represent aseptic loosening or small-particle disease related to polyethylene or methyl methacrylate cement. Radiolucency with periostitis and soft-tissue swelling should raise suspicion of deep infection, which is reported to occur in 0–3.9% of cases (Fig. 13A). *Staphylococcus aureus*, *Staphylococcus epidermidis*, and *Propionibacterium acnes* are the most commonly isolated organisms from the cultures of postoperative shoulder infections [36]. Infection is primarily treated with explantation of the arthroplasty and placement of an antibiotic-impregnated spacer either prefabricated or mixed with cement and stabilized by a Steinmann pin (Fig. 13B).

Stress shielding is long-term complication of hemiarthroplasty and a risk factor for aseptic loosening and periprosthetic fracture. “Stress shielding” is the term used to describe adaption of periprosthetic bone to changes in stress distribution that are induced by the humeral stem component [37]. Stress shielding has an incidence of approximately 9%. On imaging, stress shielding appears as bone (cortical) thinning and increased internal porosity (Fig. 14).

Incidence of intraoperative fracture is reported as 1.2% during primary arthroplasty and 3.3% during revision shoulder arthroplasty, with a 2.9 relative risk using press-fit compared with cemented humeral stems [38]. Fractures involving the tuberosities (region 1 fractures) may not require fixation but if displaced are typically treated with suture fixation of the fractured tuberosity to the humeral implant and circumferentially around the proximal part of the humerus. Region 2 fractures, those involving the metaphysis, also undergo cerclage fixation with autologous bone grafting. Longer-stemmed humeral implants may be used for intraoperative fractures involving the proximal, mid, or distal humeral diaphysis (region 3 and 4 fractures).

Postoperative fracture incidence is 1.6–2.4%, usually due to trauma [39]. The Wright and Co-field [39] classification scheme for fractures is

based on degree of proximal extension (Fig. 15). For patients undergoing hemiarthroplasty for treatment of proximal humeral fracture, poorer subjective outcomes and lower rates of postoperative arm elevation are seen when the tuberosity fragment displaces more than 0.5 cm or fails to heal [40]. Thus, attention should be made to healing and change of alignment of the preoperative fracture.

In addition to the previously mentioned complications, oncologic humeral prostheses are at risk of failure of allograft incorporation, larger area of heterotopic ossification formation, and tumor recurrence (Fig. 16). Rates of recurrence vary depending on factors such as primary histology and extent of initial tumor.

## Conclusion

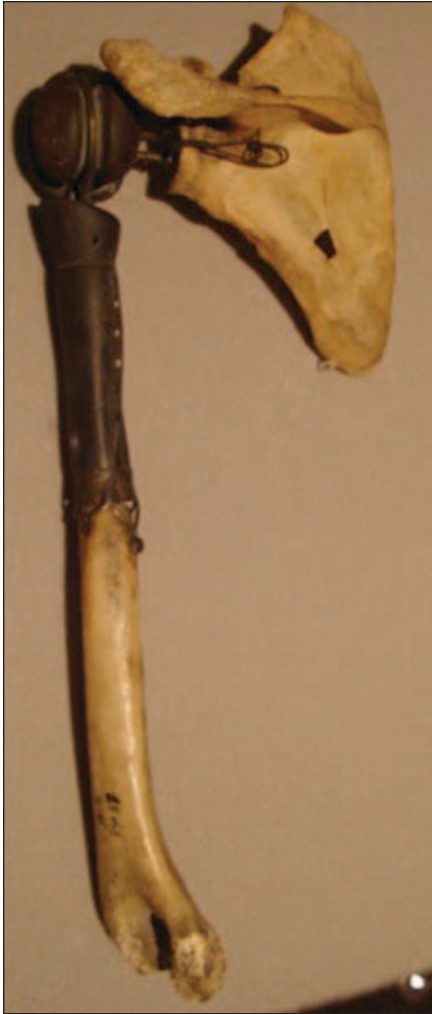Knowledge of indications, component construction, normal postoperative imaging assessment and measurements, and findings of complications is important for providing a meaningful radiologic evaluation of shoulder arthroplasty.

## References

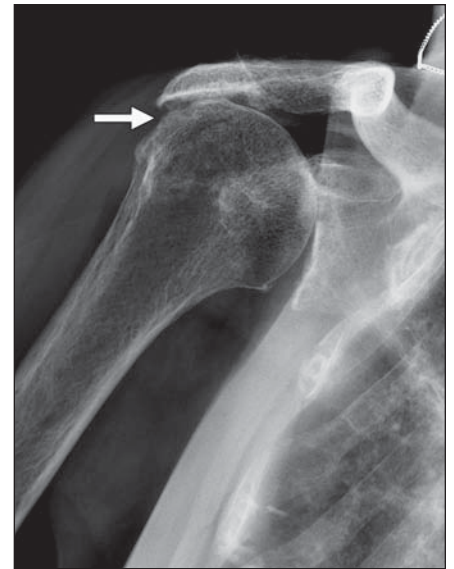- Hill CL, Gill TK, Shanahan EM, Taylor AW. Prevalence and correlates of shoulder pain and stiffness in a population-based study: the North West Adelaide Health Study. *Int J Rheum Dis* 2010; 13:215–222
- Boselli KJ, Ahmad CS, Levine WN. Treatment of glenohumeral arthrosis. *Am J Sports Med* 2010; 38:2558–2572
- Gartsman GM, Taverna E. The incidence of glenohumeral joint abnormalities associated with full-thickness, reparable rotator cuff tears. *Arthroscopy* 1997; 13:450–455
- Lugli T. Artificial shoulder joint by Pean (1893): the facts of an exceptional intervention and the prosthetic method. *Clin Orthop Relat Res* 1978; 133:215–218
- Gross RM. The history of total shoulder arthroplasty. In: Crosby LA, ed. *Total shoulder arthroplasty*. Rosemont, IL: American Academy of Orthopedic Surgeons, 2000:1–15
- Neer CS 2nd, Watson KC, Stanton FJ. Recent experience in total shoulder replacement. *J Bone Joint Surg Am* 1982; 64:319–337
- Grammont P, Trouilloud P, Laffay JP, Deries X. Concept study and realization of a new total shoulder prosthesis [in French]. *Rheumatologie* 1987; 39:407–418
- Neer CS 2nd. Articular replacement for the humeral head. *J Bone Joint Surg Am* 1955; 37:215–228
- Steffee AD, Moore RW. Hemi-resurfacing arthroplasty of the shoulder. *Contemp Orthop* 1984; 9:51–59
- Hammond G, Tibone JE, McGarry MH, Jun BJ, Lee TQ. Biomechanical comparison of anatomic humeral head resurfacing and hemiarthroplasty in functional glenohumeral positions. *J Bone Joint Surg Am* 2012; 94:68–76
- Kim SH, Wise BL, Zhang Y, Szabo RM. Increasing incidence of shoulder arthroplasty in the United States. *J Bone Joint Surg Am* 2011; 93:2249–2254
- Saue N, Pfirrmann CW, Schmid MR, Jost B, Werner CM, Zanetti M. Association between rotator cuff abnormalities and reduced acromiohumeral distance. *AJR* 2006; 187:376–382
- Norwood LA, Barrack R, Jacobson KE. Clinical presentation of complete tears of the rotator cuff. *J Bone Joint Surg Am* 1989; 71:499–505
- Fealy S, Sperling JW, Warren RF, Craig EV. *Shoulder arthroplasty: complex issues in the primary and revision setting*. New York, NY: Thieme, 2008
- Walch G, Badet R, Boulahia A, Khoury A. Morphologic study of the glenoid in primary glenohumeral osteoarthritis. *J Arthroplasty* 1999; 14:756–760
- Farron A, Terrier A, Buchler P. Risks of loosening of a prosthetic glenoid implanted in retroversion. *J Shoulder Elbow Surg* 2006; 15:521–526
- Nyffeler RW, Jost B, Pfirrmann CW, Gerber C. Measurement of glenoid version: conventional radiographs versus computed tomography scans. *J Shoulder Elbow Surg* 2003; 12:493–496
- Friedman RJ, Hawthorne KB, Genev BM. The use of computerized tomography in the measurement of glenoid version. *J Bone Joint Surg Am* 1992; 74:1032–1037
- Bryce CD, Davison AC, Lewis GS, Wang L, Flemming DJ, Armstrong AD. Two-dimensional glenoid version measurements vary with coronal and sagittal scapular rotation. *J Bone Joint Surg Am* 2010; 92:692–699
- Hoenecke HR Jr, Hermida JC, Flores-Hernandez C, D'Lima DD. Accuracy of CT-based measurements of glenoid version for total shoulder arthroplasty. *J Shoulder Elbow Surg* 2010; 19:166–171
- Budge MD, Lewis GS, Schaefer E, Coquia S, Flemming DJ, Armstrong AD. Comparison of standard two-dimensional and three-dimensional corrected glenoid version measurements. *J Shoulder Elbow Surg* 2011; 20:577–583
- Copeland SA. Cementless total shoulder replacement. In: Post M, Morrey BF, Hawkins RJ, eds. *Surgery of the shoulder*. St. Louis, MO: Mosby Year Book, 1990:289–293
- Burgess DL, McGrath MS, Bonutti PM, et al. Shoulder resurfacing. *J Bone Joint Surg Am* 2009; 91:1228–1238
- Uribe JW, Botto-van Bemden A. Partial humeral head resurfacing for osteonecrosis. *J Shoulder Elbow Surg* 2009; 18:711–716
- Thomas SR, Wilson AJ, Chamblar A, Harding I, Thomas M. Outcome of Copeland surface replacement shoulder arthroplasty. *J Shoulder Elbow Surg* 2005; 14:485–491
- Buchner M, Eschbach N, Loew M. Comparison of the short-term functional results after surface replacement and total shoulder arthroplasty for osteoarthritis of the shoulder: a matched-pair analysis. *Arch Orthop Trauma Surg* 2008; 128:347–354
- Scalise JJ, Miniaci A, Iannotti JP. Resurfacing arthroplasty of the humerus: indications, surgical techniques and clinical results. *Tech Shoulder Elbow Surg* 2007; 8:152–160
- Wiater JM, Fabing MH. Shoulder arthroplasty: prosthetic options and indications. *J Am Acad Orthop Surg* 2009; 17:415–425
- Boileau P, Sinnerton RJ, Chuinard C, Walch G. Arthroplasty of the shoulder. *J Bone Joint Surg Br* 2006; 88:562–575
- Radnay CS, Setter KJ, Chambers L, Levine WN, Bigliani LU, Ahmad CS. Total shoulder replacement compared with humeral head replacement for the treatment of primary glenohumeral osteoarthritis: a systematic review. *J Shoulder Elbow Surg* 2007; 16:396–402
- Sanchez-Sotelo J. Total shoulder arthroplasty. *Open Orthop J* 2011; 5:106–114
- Thai DM, Kitagawa Y, Choong PF. Outcome of surgical management of bony metastases to the humerus and shoulder girdle: a retrospective analysis of 93 patients. *Int Semin Surg Oncol* 2006; 3:5
- Merolla G, Di Pietto F, Romano S, Paladini P, Campi F, Porcellini G. Radiographic analysis of shoulder anatomical arthroplasty. *Eur J Radiol* 2008; 68:159–169
- Sanchez-Sotelo J, Wright TW, O'Driscoll SW, Cofield RH, Rowland CM. Radiographic assessment of uncemented humeral components in total shoulder arthroplasty. *J Arthroplasty* 2001; 16:180–187
- Sperling JW, Cofield RH, Rowland CM. Minimum fifteen-year follow-up of Neer hemiarthroplasty and total shoulder arthroplasty in patients aged fifty years or younger. *J Shoulder Elbow Surg* 2004; 13:604–613
- Saltzman MD, Marecek GS, Edwards SL, Kalainov DM. Infection after shoulder surgery. *J Am Acad Orthop Surg* 2011; 19:208–218
- Nagels J, Stokdijk M, Rozing PM. Stress shielding and bone resorption in shoulder arthroplasty. *J Shoulder Elbow Surg* 2003; 12:35–39
- Athwal GS, Sperling JW, Rispoli DM, Cofield RH. Periprosthetic humeral fractures during shoulder arthroplasty. *J Bone Joint Surg Am* 2009; 91:594–603
- Wright TW, Cofield RH. Humeral fractures after shoulder arthroplasty. *J Bone Joint Surg Am* 1995; 77:1340–1346
- Kralinger F, Schwaiger R, Wambacher M, et al. Outcome after primary hemiarthroplasty for fracture of the head of the humerus: a retrospective multicenter study of 167 patients. *J Bone Joint Surg Br* 2004; 86:217–219



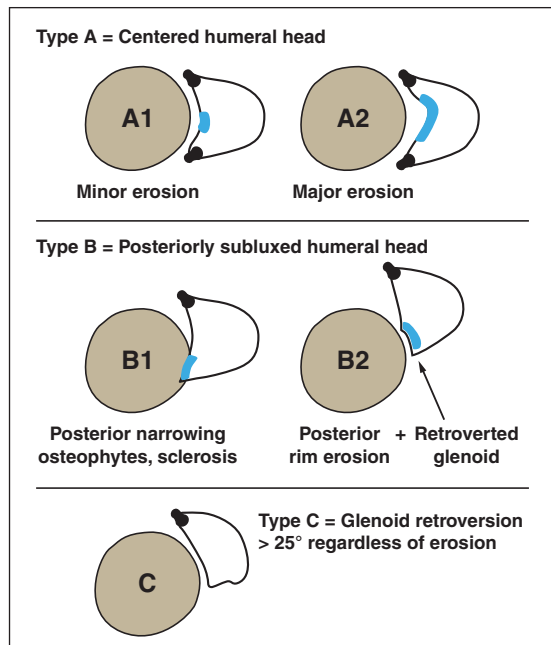
## Imaging Shoulder Arthroplasty



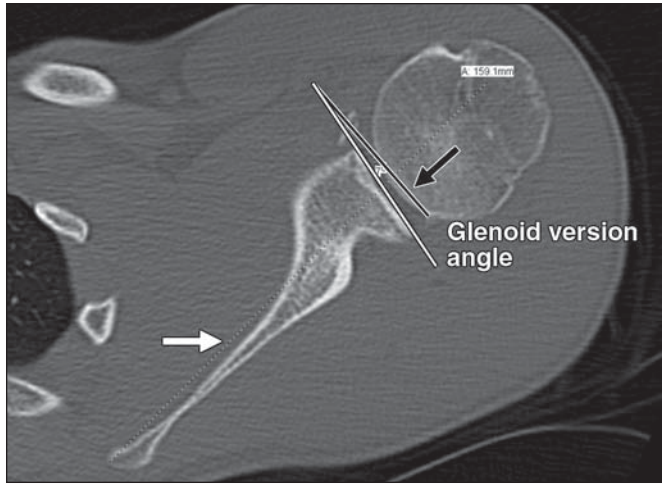
**Fig. 1**—Photograph taken at Smithsonian National Museum of History shows first shoulder replacement placed by Jules E. Pean in patient with tuberculous arthritis. Arthroplasty consists of iridescent platinum tube, hardened rubber ball coated with paraffin, and two metal loops that attach ball to scapula and tube.  
←



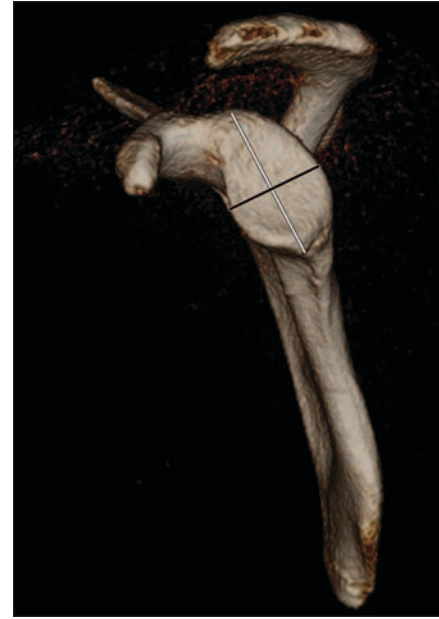**Fig. 2**—Narrowed acromial-humeral distance. Anteroposterior radiograph of right shoulder in 81-year-old man with osteoarthritis shows severe narrowing of acromial-humeral distance to less than 7 mm (arrow), with “acetabularization” of undersurface of acromion. Also seen is severe narrowing of glenohumeral joint with subchondral sclerosis, subchondral cysts, and osteophytes. Findings are consistent with osteoarthritis.  
→



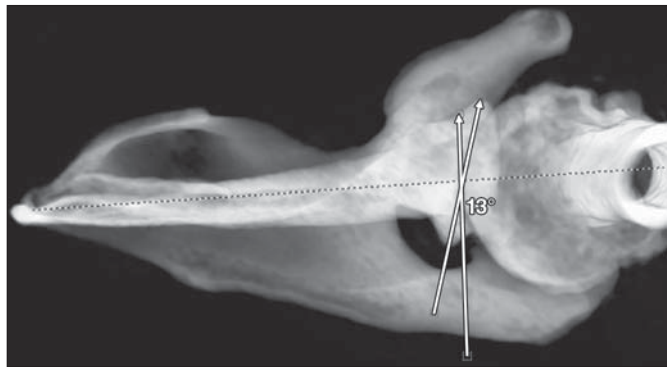
**Fig. 3**—Walch glenoid morphology scale. Illustration shows grading of glenoid morphology, focusing on presence of glenoid erosions, posterior subluxation, and glenoid retroversion. Osteoarthritis more commonly results in posterior version and posterior erosions whereas inflammatory arthritis results in central erosions.



A



B



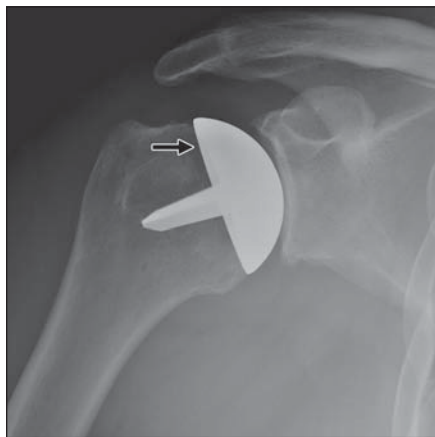
C

**Fig. 4**—Calculation of glenoid version in 53-year-old man with posttraumatic osteoarthritis.

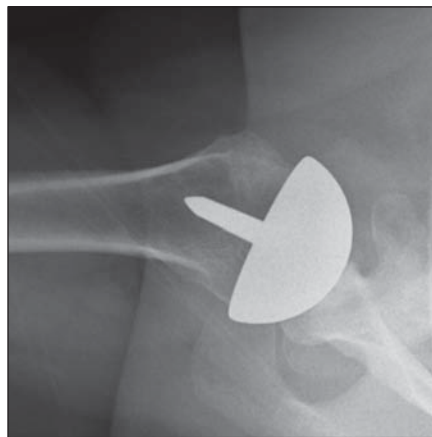
**A**, On axial 2D CT image in bone windows, at or just below tip of coracoid, line is drawn from medial border of scapula to center of glenoid (*white arrow*). Line perpendicular to this is drawn (*black arrow*). Angle between this line and line perpendicular to face of glenoid (*white line*) is version angle. In this patient, glenoid is retroverted by 7°, which is abnormal.

**B**, Three-dimensional volume-rendered image of glenoid face shows method for version calculation. Vertical line (*white line*) is drawn on 3D surface of glenoid face, centered in anteroposterior direction. Transverse 2D plane is generated by drawing line (*black line*) perpendicular to midpoint of white line to pass through scapular axis.

**C**, Glenoid version angle is then measured at level of transverse plane using Friedman technique for 2D CT slice. Here, angle measures 13°, which is abnormal.



A

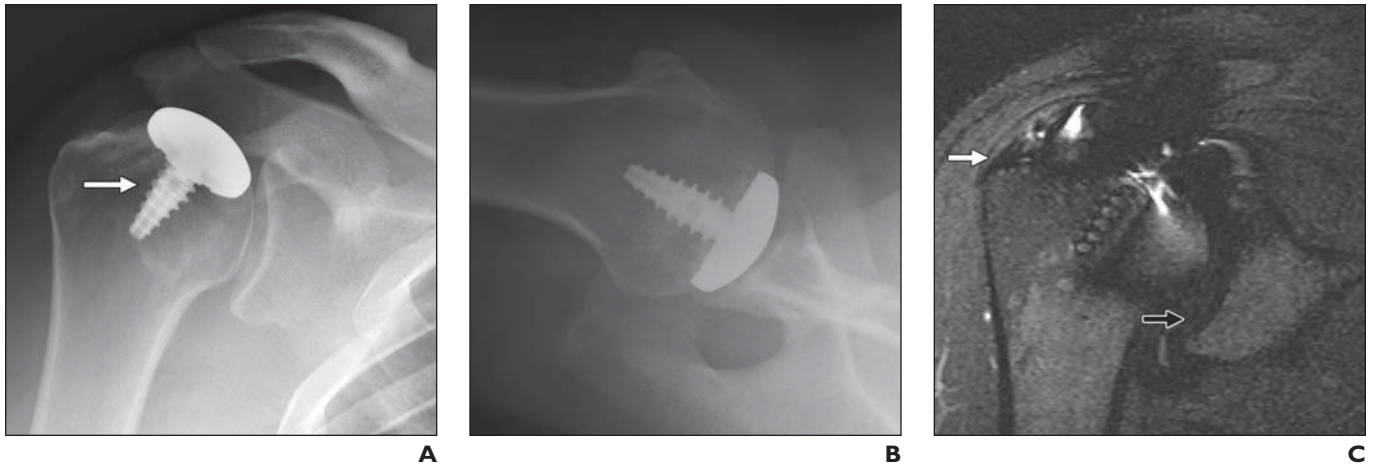


B

**Fig. 5**—Humeral head resurfacing in 37-year-old man with humeral head avascular necrosis.

**A and B**, Grashey (**A**) and axillary (**B**) radiographs show normal imaging appearance after total resurfacing humeral head arthroplasty, with articular metal cap flush against bone (*arrow*, **A**) and stabilizing peg without surrounding radiolucency.

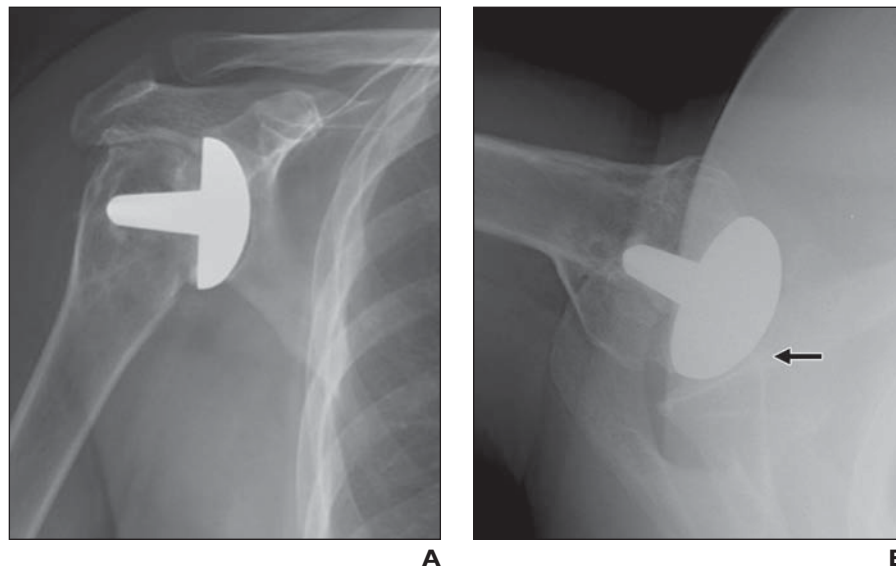
## Imaging Shoulder Arthroplasty



**Fig. 6**—Partial humeral head resurfacing in 52-year-old man with focal osteochondral defect.

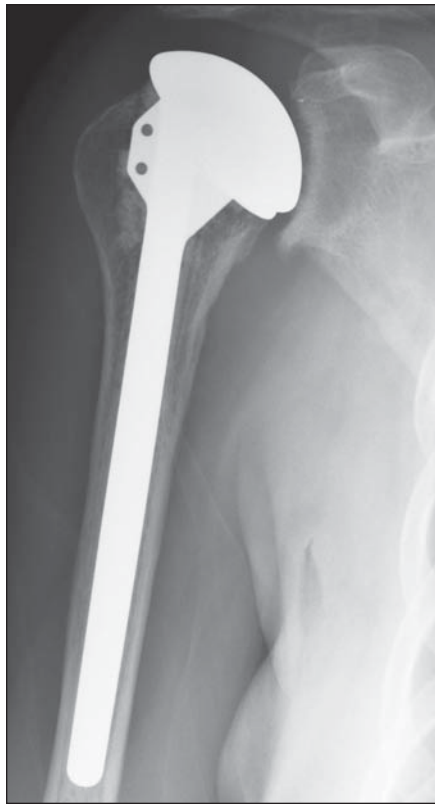**A and B**, Anteroposterior (**A**) and axillary (**B**) radiographs of right shoulder show treatment with partial humeral head resurfacing (*arrow*, **A**). Articular cap should be flush with articular cartilage, and there should be no lucency surrounding post. On axillary view, implant should center on glenoid.

**C**, Coronal STIR image shows that partial resurfacing still enables evaluation of rotator cuff integrity (*white arrow*) and glenoid labrum and articular cartilage (*black arrow*).

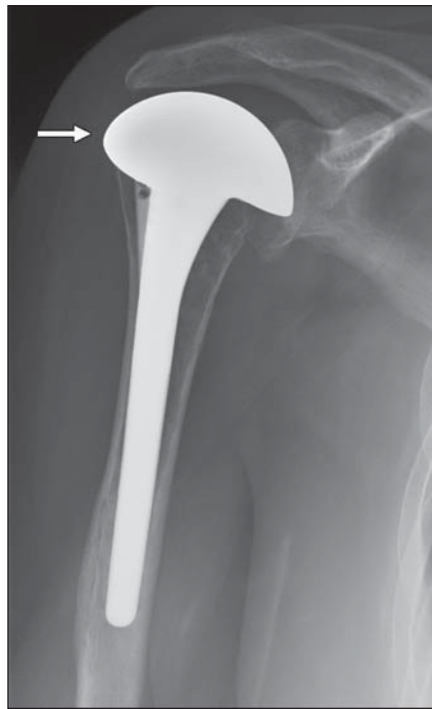

**Fig. 7**—Complication of humeral head resurfacing in 55-year-old woman with resurfacing arthroplasty of humeral head.

**A and B**, Anteroposterior (**A**) and axillary (**B**) radiographs show narrowing of glenohumeral joint and greater than 50% anterior subluxation of humerus relative to glenoid (*arrow*, **B**). Findings were due to subscapularis tear.



**A**

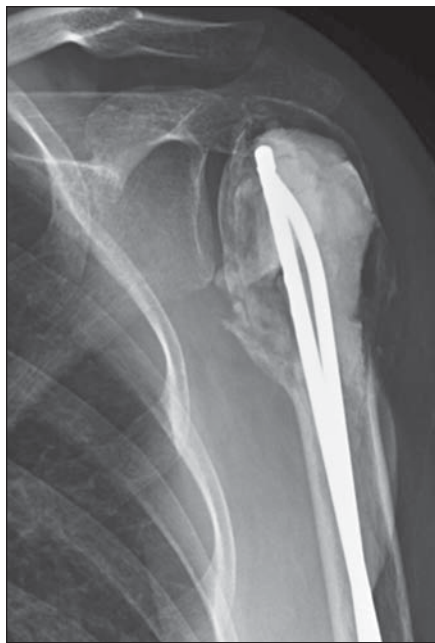

**B**

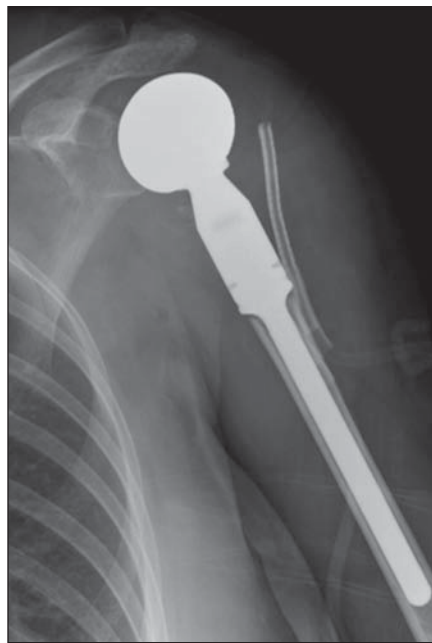**Fig. 8—Hemiarthroplasty.**

**A**, Grashey radiograph of hemiarthroplasty in 65-year-old woman with osteonecrosis of humerus shows replacement of humeral articular surface with metal stem component similar to that used in anatomic total shoulder arthroplasty. No glenoid replacement is present.

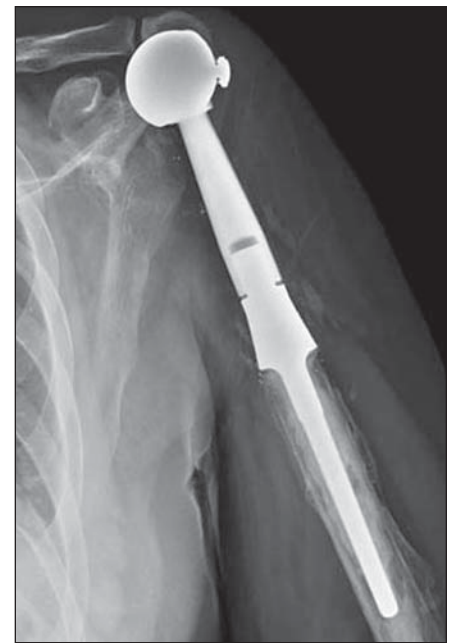**B**, Anteroposterior radiograph of extended coverage humeral component hemiarthroplasty in 69-year-old woman with full-thickness rotator cuff tear. Articular head surface extends more laterally (arrow) to prevent bony impingement between greater tuberosity of humerus and acromion. No glenoid component is present.



**A**



**B**



**C**

**Fig. 9—Oncologic humeral hemiarthroplasty.**

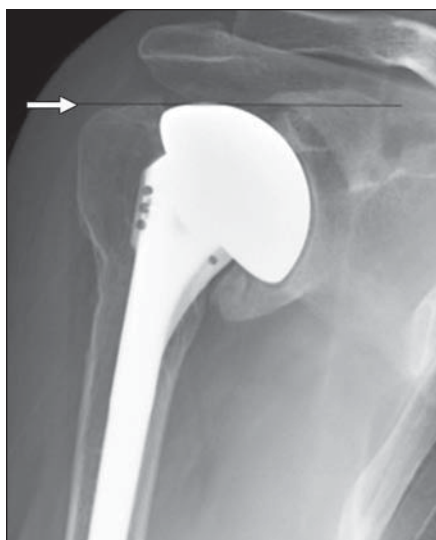**A**, Anteroposterior radiograph of left shoulder in 27-year-old woman who underwent multiple prior giant cell tumor resections from proximal humerus shows cement packing and intramedullary rod placement.

**B**, Slightly oblique frontal radiograph in same patient as in **A** immediately after placement of oncologic hemiarthroplasty component and direct rotator cuff reattachment to prosthesis. Soft-tissue drain is seen lateral to prosthesis.

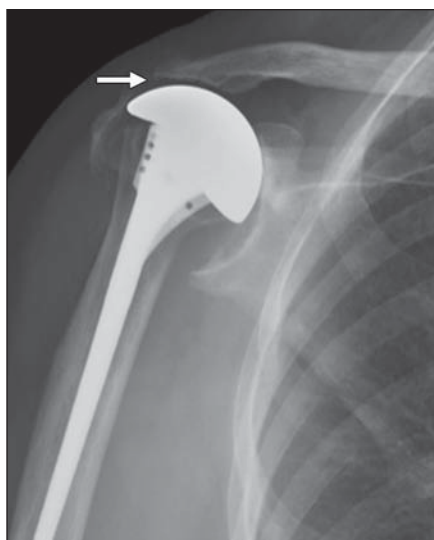
**C**, Frontal radiograph in 35-year-old man after Ewing sarcoma resection shows oncologic prosthesis without cuff repair. Note decreased acromiohumeral distance.



## Imaging Shoulder Arthroplasty



**A**

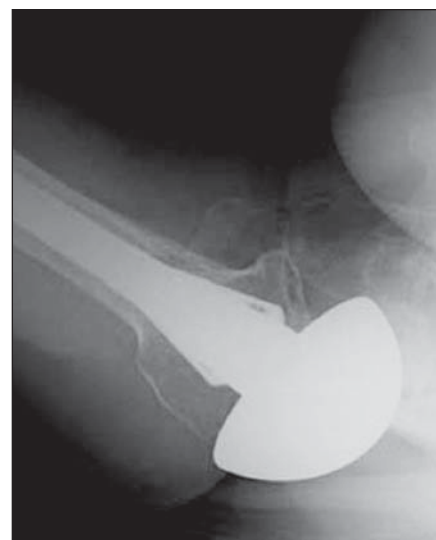


**B**

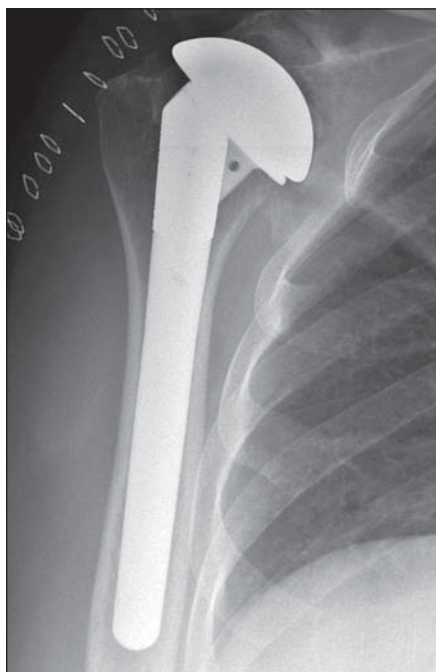
**Fig. 10**—Humeral head height evaluation.

**A**, Decreased humeral head height in 49-year-old man 18 months after hemiarthroplasty surgery represents subsidence, with line indicating that greater tuberosity and humeral component are at similar level due to axial migration of implant (*arrow*).

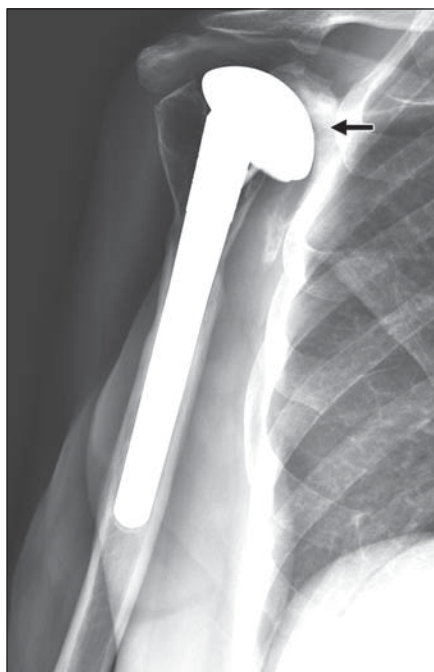
**B**, Increased humeral height in 54-year-old woman after hemiarthroplasty. Decreased (< 2 mm) acromiohumeral distance can be due to overstuffing of humeral component (*arrow*), as in this patient. Also noted is heterotopic ossification adjacent to greater tuberosity.



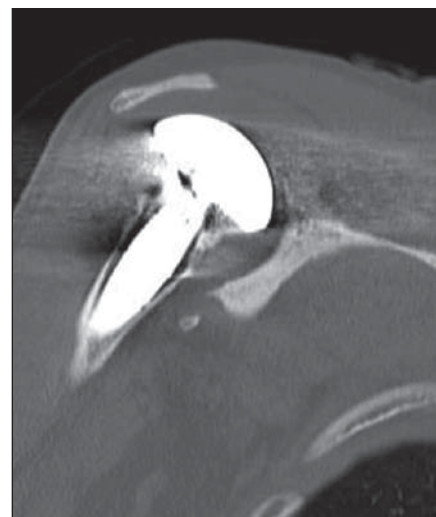
**Fig. 11**—Subluxation axillary radiograph in 47-year-old man with shoulder hemiarthroplasty for degenerative arthritis shows moderate posterior subluxation (25–50% translation of humeral head).



**A**



**B**



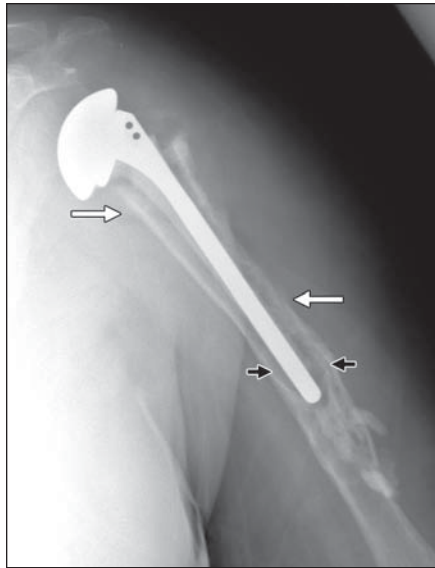
**C**

**Fig. 12**—Glenoid erosions in 51-year-old woman.

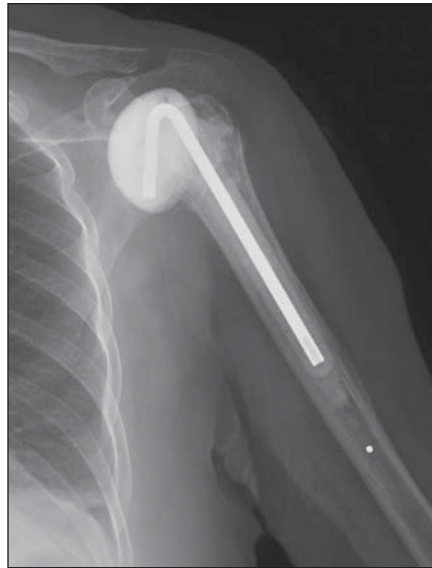**A**, Initial postoperative anteroposterior radiograph shows hemiarthroplasty without glenoid erosion.

**B**, Anteroposterior radiograph 12 months after **A** shows progressive medial translation of humerus, with narrowing of glenohumeral joint, sclerosis of glenoid, and erosions (*arrow*).

**C**, Coronal CT scan in bone window shows major central remodeling of glenoid.



**A**

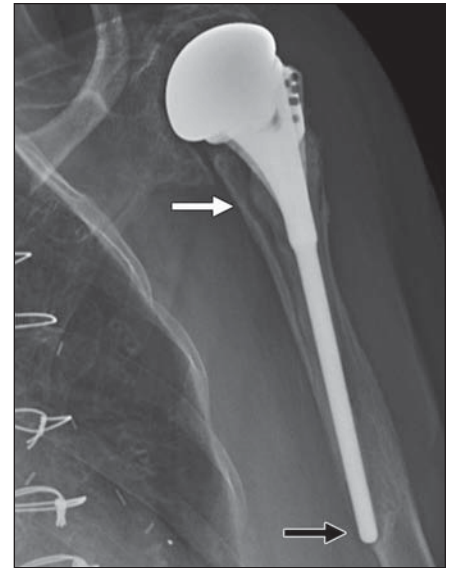


**B**

**Fig. 13—Arthroplasty infection.**

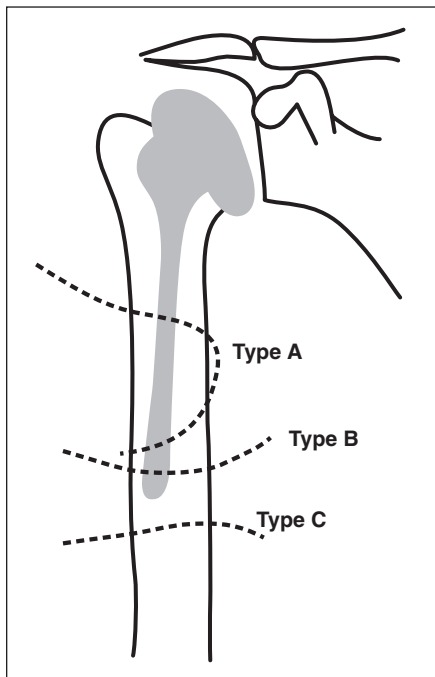
**A**, Anteroposterior radiograph of hemiarthroplasty in 65-year-old woman shows areas of periostitis around entire humeral shaft (white arrows) and radiolucency adjacent to metal stem (black arrows). There is soft-tissue swelling around shoulder. Joint aspiration was performed and cultures grew *Staphylococcus aureus*. Thus, radiographic findings were due to infection.

**B**, Anteroposterior radiograph in 72-year-old woman shows methyl methacrylate antibiotic-impregnated spacer with pin placed for treatment of infected shoulder arthroplasty.

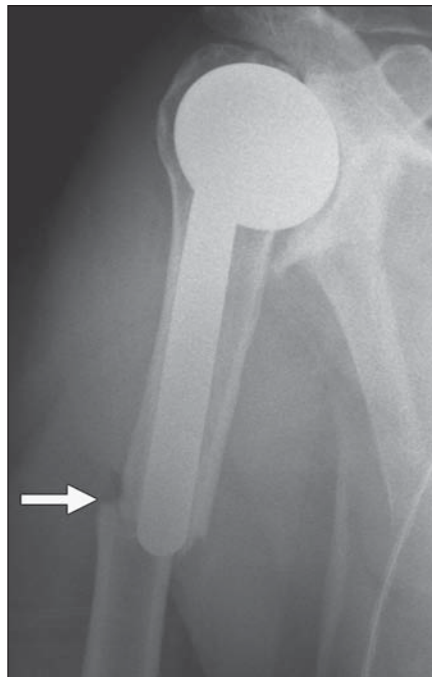


**Fig. 14—Stress shielding and radiolucency** in 83-year-old woman with hemiarthroplasty.

Anteroposterior radiograph shows thinning of humeral cortex (white arrow), medullary areas of increased osteopenia, and loosening of prosthesis, with stem extending from cortex (black arrow). Stress shielding increases risk of aseptic loosening and fracture and makes revision arthroplasty more challenging.



**A**



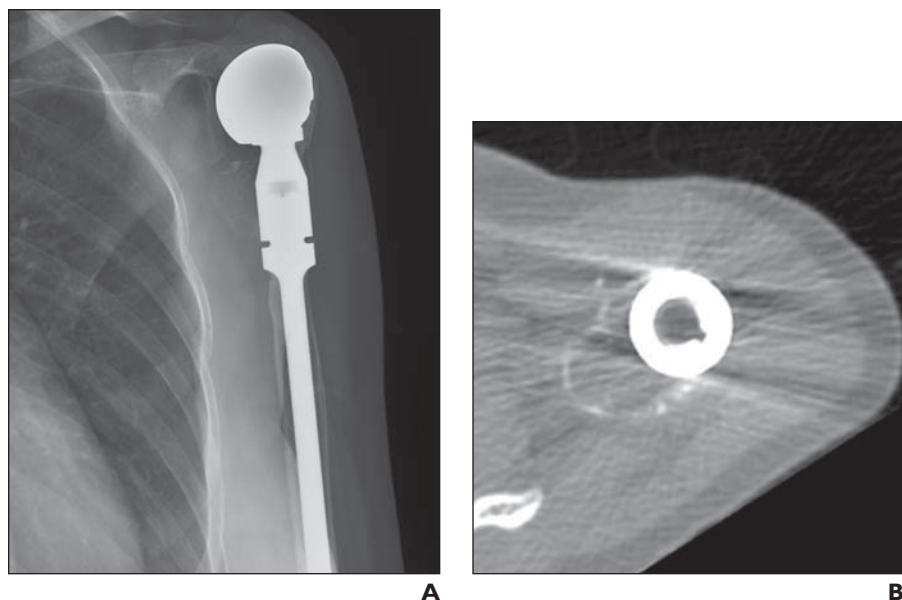
**B**

**Fig. 15—Periprosthetic fracture.**

**A**, Illustration shows Wright and Cofield [39] classification scheme of periprosthetic fractures around humeral component. Type A fractures are located at tip of prosthesis and extend proximally. Type B fractures lie at tip of prosthesis or cement without extension or only minimal proximal extension. Type C fractures are located distal to tip of prosthesis.

**B**, Anteroposterior radiograph in 54-year-old man with hemiarthroplasty of right shoulder after fall shows transverse fracture at tip of humeral stem (arrow) without proximal extension. This would be classified as type B fracture.

## Imaging Shoulder Arthroplasty



**Fig. 16**—Tumor recurrence after oncologic humeral prosthesis in 28-year-old woman with prior giant cell tumor (GCT) resection.

**A and B**, Anteroposterior radiograph (**A**) of shoulder now shows new expansile lytic lesion arising from medial margin of proximal humeral shaft. This lesion is also seen on axial CT (**B**), representing GCT recurrence.

### FOR YOUR INFORMATION

This article is part of a self-assessment module (SAM). Please also refer to "Current Concepts of Shoulder Arthroplasty for Radiologists: Part 2—Anatomic and Reverse Total Shoulder Replacement and Nonprosthetic Resurfacing," which can be found on page 768.

Each SAM is composed of two journal articles along with questions, solutions, and references, which can be found online. You can access the two articles at [www.ajronline.org](http://www.ajronline.org), and the questions and solutions that comprise the Self-Assessment Module by logging on to [www.arrs.org](http://www.arrs.org), clicking on *AJR* (in the blue Publications box), clicking on the article name, and adding the article to the cart and proceeding through the checkout process.

The American Roentgen Ray Society is pleased to present these SAMs as part of its commitment to lifelong learning for radiologists. Continuing medical education (CME) and SAM credits are available in each issue of the *AJR* and are **free to ARRS members**. **Not a member?** Call 1-866-940-2777 (from the U.S. or Canada) or 703-729-3353 to speak to an ARRS membership specialist and begin enjoying the benefits of ARRS membership today!